



Contents lists available at ScienceDirect

## International Journal of Surgery Case Reports

journal homepage: [www.casereports.com](http://www.casereports.com)

# Incarcerated incisional hernia of the sigmoid colon after appendectomy: A case report



Pyong Wha Choi

Department of Surgery, Inje University College of Medicine, Ilsan Paik Hospital, 170, Juhwa-ro, Ilsanseo-gu, Goyang-si, Gyeonggi-do, Goyang 10380, Republic of Korea

## ARTICLE INFO

## Article history:

Received 13 October 2016  
 Received in revised form 3 January 2017  
 Accepted 4 January 2017  
 Available online 5 January 2017

## Keywords:

Incisional hernia  
 Appendectomy  
 Colon

## ABSTRACT

**INTRODUCTION:** Incisional hernia after appendectomy is rare, affecting 0.4% to 0.9% of cases. The small bowel and omentum are commonly herniated through the abdominal wall defect, but incisional hernia of the sigmoid colon is extremely rare.

**CASE PRESENTATION:** A 78-year-old man presented with a right lower quadrant abdominal wall mass on the previous McBurney incision site. He had a history of appendectomy for appendicitis 40 years ago. Computed tomography (CT) showed the sigmoid colon herniated through the abdominal wall defect. During the operation, a feces-impacted sigmoid colon was found protruding through the defect of the abdominal wall. Reduction of the sigmoid colon into the peritoneal cavity and herniorrhaphy with primary repair were performed.

**DISCUSSION:** The ascending and descending colon are fixed into the retroperitoneum, whereas the transverse and sigmoid colon are not, which can allow these bowel segments to herniate through a weak abdominal wall just as small bowel loops do. However, incisional hernia of the colon is extremely rare. The diagnosis of incisional hernia can be easily made because a reducible abdominal wall mass can be detected by physical examination. In cases with rare type of hernia, CT can identify unusual types of abdominal hernias and differentiate hernias from neoplasms, inflammatory disease, and hematoma.

**CONCLUSION:** Although incisional hernia of the colon after appendectomy is extremely rare and preoperative diagnosis by physical examination is difficult, CT is a useful method to make the correct diagnosis, avoiding unnecessary invasive intervention, particularly in patients with an unusual abdominal wall mass.

© 2017 The Author(s). Published by Elsevier Ltd on behalf of IJS Publishing Group Ltd. This is an open access article under the CC BY-NC-ND license (<http://creativecommons.org/licenses/by-nc-nd/4.0/>).

## 1. Introduction

Incisional hernia after appendectomy is very rare, with a prevalence rate of 0.4% to 0.9% [1]. The most common contents of the sac of incisional hernias are the small bowel or omentum because these organs are freely movable in the peritoneal cavity, but colonic herniation through the abdominal wall defect is extremely rare irrespective of previous incision type. Here, we present a case of a 78-year-old man with an abdominal wall mass that was determined to be post-appendectomy incisional hernia of the sigmoid colon [2].

## 2. Presentation of case

A 78-year-old man, presenting with a right lower quadrant abdominal wall mass, was admitted to the Department of Surgery, Inje University, College of Medicine, Ilsan Paik Hospital. The mass

was first detected 3 months ago, but there were no associated obstructive bowel symptoms such as abdominal distension, pain, and constipation. He had a history of appendectomy for appendicitis 40 years ago, and well-controlled diabetes mellitus diagnosed 10 years ago. At that time of appendectomy, appendicitis was uncomplicated. So, simple appendectomy was performed without drain. He was discharged from the hospital on the 2th postoperative day without complications, and returned to work (a night guard) after 1 week postoperatively.

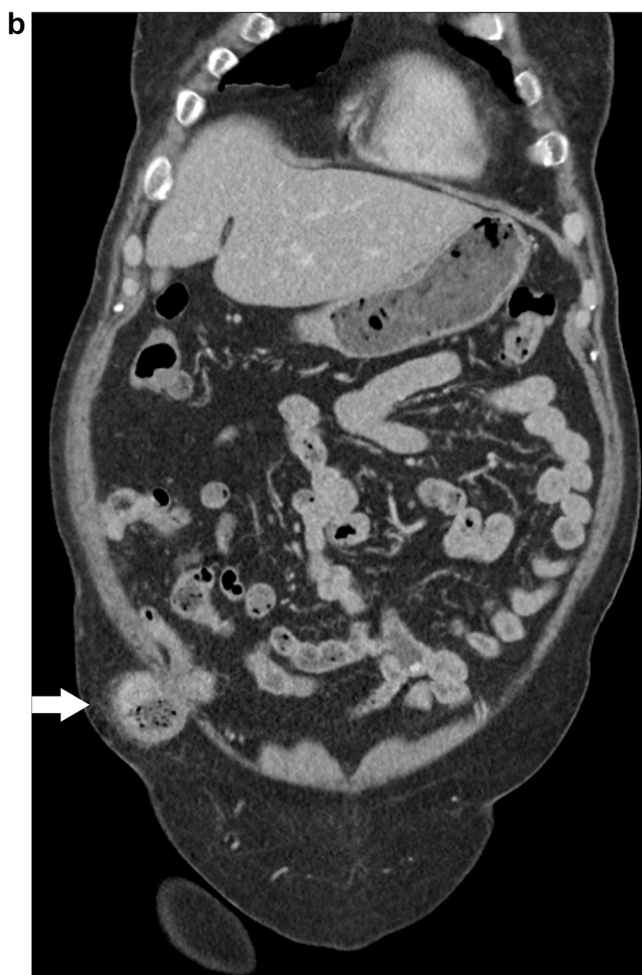
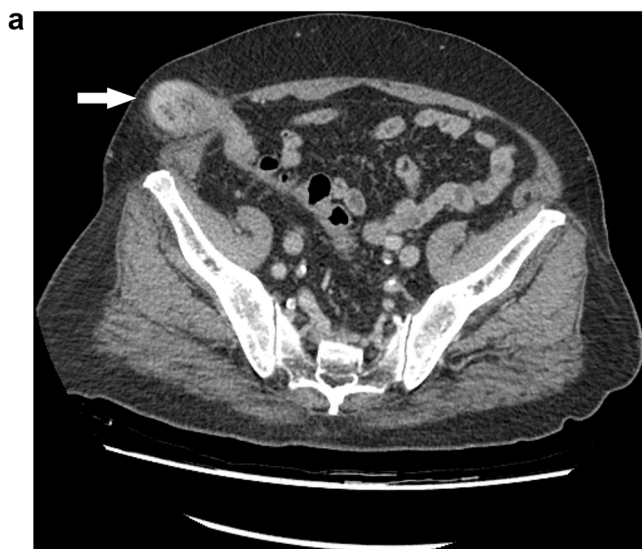On admission, his vital signs were stable and laboratory results were within normal limits. Physical examination revealed a 3 cm × 3 cm irreducible subcutaneous soft and movable mass on the previous McBurney incision scar, with a base fixed into the deep abdominal wall. There was no tenderness, rebound tenderness, redness, or heat, but the patient complained of localized pain when the abdominal wall mass was squeezed.

A neoplastic lesion such as a desmoid tumor or lipoma was considered as a presumptive clinical diagnosis based on physical examination. However, a computed tomography (CT) showed the sigmoid colon herniated through the abdominal wall defect with-

E-mail address: [choipeace1130@gmail.com](mailto:choipeace1130@gmail.com)

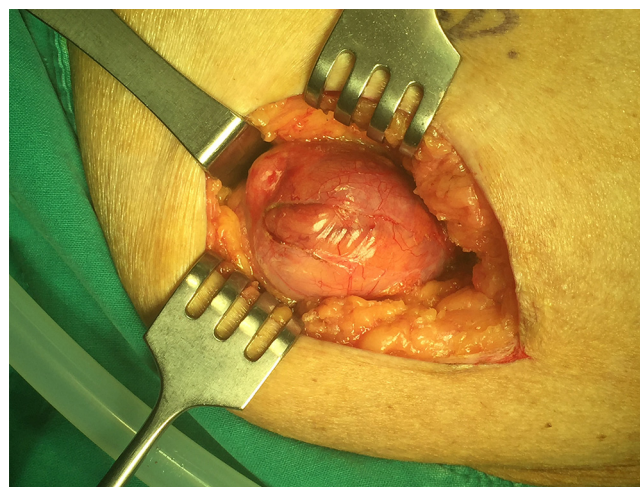
<http://dx.doi.org/10.1016/j.ijscr.2017.01.006>

2210-2612/© 2017 The Author(s). Published by Elsevier Ltd on behalf of IJS Publishing Group Ltd. This is an open access article under the CC BY-NC-ND license (<http://creativecommons.org/licenses/by-nc-nd/4.0/>).



**Fig. 1.** Abdominal computed tomography shows herniation of the sigmoid colon through the defect of the right low quadrant abdominal wall (arrow). a: axial image, b: coronal image.

out ischemic changes, indicating an incarcerated incisional hernia of the sigmoid colon (Fig. 1). During the operation, after sharp and blunt dissection of the mass in the subcutaneous layer, an incarcerated sigmoid colon, which was impacted with hard stool, was identified (Fig. 2). Reduction of the sigmoid colon into the peritoneal cavity and herniorrhaphy with primary repair were per-



**Fig. 2.** Operative findings. Herniated sigmoid colon is shown after blunt and sharp dissection of the abdominal wall beneath the McBurney incision scar.

formed. The patient was discharged from the hospital on the 4th postoperative day without complications.

### 3. Discussion

Incisional hernia is one of the late complications of open abdominal or, rarely, laparoscopic surgery. Many factors can have an effect on the development of incisional hernia including old age, male, obesity, steroid use, diabetes mellitus, inept surgical technique, and postoperative wound infection [3,4]. Other than these risk factors, the length of the incision is closely related to the occurrence of this type of hernia. In open abdominal surgery, incisional hernias following major abdominal surgery requiring a long incision and a long operative time is more common than those following minor surgery. Appendectomy is a common and representative minor surgery with a small incision although some severe cases require bowel resection, a long incision, and a prolonged operative time. Incisional hernia after appendectomy is very rare, affecting less than 1% of cases [1].

The small bowel and omentum are commonly herniated organs, but unusual organs such as the bladder and colon may herniate through the abdominal wall defect [5–8]. The ascending and descending colon are fixed into the retroperitoneum, whereas the transverse and sigmoid colon are not, which can allow these bowel segments to herniate through a weak abdominal wall just as small bowel loops do. In the present case, although the patient had several risk factors for incisional hernia such as old age, male, and diabetes mellitus, incisional hernia of the sigmoid colon is rare because the radius of the colon is larger than that of the small bowel and the colon is less redundant. Moreover, since the muscles in the abdominal wall play an important role in preventing herniation following a McBurney incision, the present case is extremely rare when considering the probability of colonic incisional hernia through a McBurney incision following appendectomy [5]. In the English literature, the present case is the fourth case of incisional hernia of the colon after abdominal surgery (Table 1) and the first case of incisional hernia of the colon after appendectomy. Unlike the present case, all previous patients with incisional colonic hernias were women, and the transverse colon was herniated in all cases. Among them, the symptoms of two cases were associated with colonic strangulation and perforation.

The diagnosis of incisional hernia without incarceration or strangulation can be easily made because a reducible abdominal wall mass can be detected by physical examination. However, in

Download English Version:

<https://daneshyari.com/en/article/5732906>

Download Persian Version:

<https://daneshyari.com/article/5732906>

[Daneshyari.com](https://daneshyari.com)