

Contents lists available at [ScienceDirect](#)

International Journal of Surgery Case Reports

journal homepage: www.casereports.com

Intraneural ganglion cyst of the ulnar nerve in an unusual location: A case report



Ufuk Öztürk^{a,*}, Ahmet Salduz^b, Mehmet Demirel^b, Tuna Pehlivanoglu^b, Sevan Sivacioglu^a

^a Department of Orthopaedics and Traumatology, Yedikule Surp Pırgıç Ermeni Hospital, İstanbul, Turkey

^b Department of Orthopaedics and Traumatology, İstanbul University, İstanbul Faculty of Medicine, İstanbul, Turkey

ARTICLE INFO

Article history:

Received 1 November 2016

Accepted 4 January 2017

Available online 5 January 2017

Keywords:

Intraneural ganglion cyst

Superficial branch

Ulnar nerve

Articular branch

ABSTRACT

INTRODUCTION: Intraneural ganglion cysts are benign, mucinous, non-neoplastic lesions of the peripheral nerves. While the most common location of intraneural ganglion cysts is the ulnar nerve and its branches, intraneural ganglion cyst involving the superficial branch of the ulnar nerve has not yet been reported.

PRESENTATION OF CASE: A 25-year-old woman presented with pain and a palpable mass in the hypothenar region of the volar side of her right hand. Her neuromuscular examination was normal. The pain was unresponsive to nonsurgical treatments. After confirming with imaging modalities, the initial diagnosis was considered as an intraneural ganglion cyst arising from superficial ulnar nerve. Excision of the ganglion and exploration of the articular branch (if seen in operation) decision was undertaken by the senior author. Whether MRI or intraoperative exploration, not identified an articular branch.

DISCUSSION: Intraneural ganglion cysts of peripheral nerves may be seen in miscellaneous locations in the body. However, to our knowledge, an intraneural ganglion cyst involving the superficial branch of the ulnar nerve is unique. While a variety of theories have been proposed to enlighten the etiopathogenesis of intraneural ganglia, the latest and most affirmed is the unifying articular (synovial) theory.

CONCLUSION: Intraneural ganglion cysts may be seen on the hypothenar side of the palm. The etiology and treatment of choice are closely associated with each other in this rare disorder. It is important to realize a related articular branch, otherwise the origin of cyst formation remains, and this may cause other para-articular cysts.

© 2017 The Authors. Published by Elsevier Ltd on behalf of IJS Publishing Group Ltd. This is an open access article under the CC BY-NC-ND license (<http://creativecommons.org/licenses/by-nc-nd/4.0/>).

1. Introduction

Intraneural ganglion cysts are benign, mucinous, non-neoplastic lesions of the peripheral nerves that arise from the epineurium, which may cause compression neuropathy at the extremities [1]. In the upper extremities, the leading location of intraneural ganglion cysts is the ulnar nerve and its branches; an intraneural ganglion cyst involving the superficial branch of the ulnar nerve has not yet been reported [2].

Although extraneural ganglion cysts are common and well-known, intraneural ganglion cysts are rare and poorly understood by surgeons in clinical practice [3]. Several theories for the pathogenesis of this rare entity have been proposed in the literature. However, the latest and most affirmed is the unifying articular (synovial) theory [4].

The aim of this case report was to present an unusually-located intraneural ganglion cyst in the superficial branch of the ulnar nerve on the hypothenar side of the palm and this paper has been reported in line with the SCARE criteria [17].

2. Case report

A woman aged 25 years was admitted to our department with pain and a palpable mass in the hypothenar region of the volar side of her right hand. Her medical history revealed that she recognized the mass following pain on the medial side of her hand 3 months before admission to our hospital. She had ignored her symptoms until the pain in her hand became intolerable. She denied having any traumatic event, and her pain was unresponsive to non-steroid anti-inflammatory drug treatment. In her physical examination, after bone and joint deformities were ruled out, we identified a palpable 1 × 1 × 1-cm mass on the hypothenar side of the palm in line with the superficial branch of the ulnar nerve. Her neuromuscular examination was normal; no muscular and sensory pathologies such as muscle atrophy or hypoesthesia were determined. In addition, special tests used to identify any kind

* Corresponding author at: İstanbul University, İstanbul Faculty of Medicine, Department of Orthopaedics and Traumatology, Çapa Fatih, İstanbul 34050, Turkey.
E-mail address: dr88.mehmet.demirel@gmail.com (U. Öztürk).

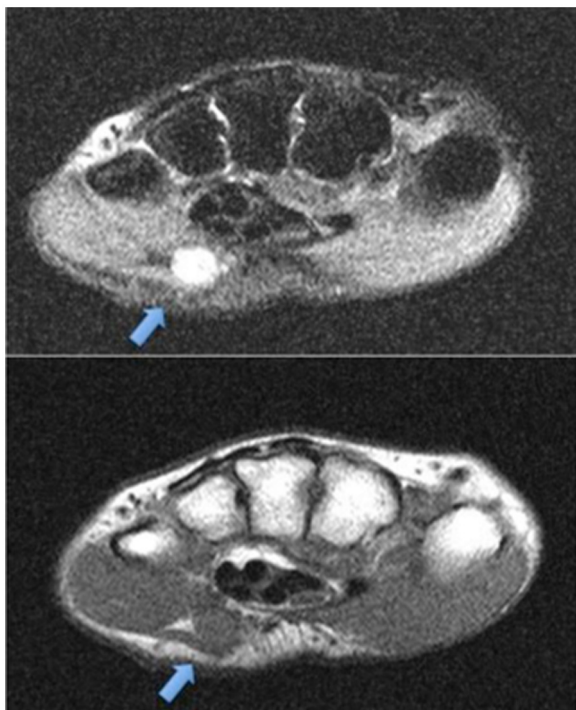


Fig. 1. Preoperative MRI displayed an intraneural ganglion cyst related to the ulnar nerve.

of compression neuropathy, Froment sign, Wartenberg sign, and Tinel sign were negative. After the anamnesis and physical examination, the intraneural ganglion cyst was considered a possible diagnosis. Therefore, we requested magnetic resonance imaging (MRI) and ultrasonography of the right hand to rule out differential diagnoses such as lipoma or granuloma by infectious agents. MRI revealed a multiloculated ganglion within the ulnar nerve on the hypothenar side of the hand, consistent with the superficial branch of the ulnar nerve. However, no articular branch associated with joint was interpreted around the mass (Fig. 1). In a related way, the sonogram revealed a cyst-like structure in the same location. In light of the above findings, the initial diagnosis was that the patient had an intraneural ganglion cyst within the superficial branch of the ulnar nerve. Excision of the ganglion and exploration of the articular branch decision was undertaken by the senior author, because the most definitive treatment is exploration and disconnection of the articular branch adjacent to the ganglion. An informed consent about the surgery was achieved from the patient.

The patient underwent surgery because of the pain increased after conservative management with non-steroid anti-inflammatory drugs and splinting of the wrist had failed. The informed consent that includes benefits and hazards about operation was taken from the patient. A prophylactic single dose of cefazolin was administered 1 h before general anesthesia. The patient was anesthetized in the prone position with general anesthesia, and an above-elbow tourniquet was fastened. A longitudinal around-hypothenar-5-cm incision was made over the mass. After achieving enough exposure, the parent ulnar nerve and its superficial branch was identified (Fig. 2). Our intraoperative impression was that it was an intraneural cyst originating from the superficial branch of the ulnar nerve, and it was entirely filled with mucinous fluid. No articular branch was observed between the mass and any joint of the hand. Excision of the mass was undertaken; the achieved mass was sent to the pathology department to assess its histopathologic features. The histopathology result was congruent with a multicystic ganglion cyst.

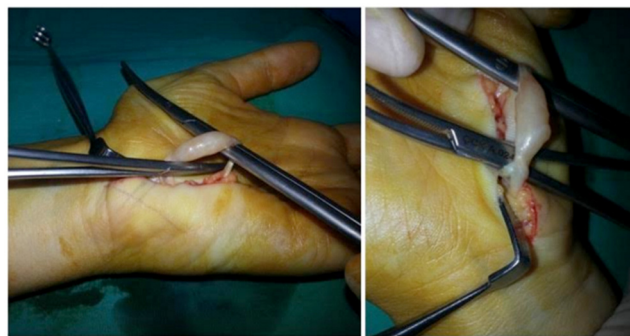

Fig. 2. The intraneural ganglion cyst arising from the superficial branch of the ulnar nerve.

At 3 weeks of follow-up, with the exception of a mild neurogenic pain in her right hand for 3 weeks after surgery, which resolved completely without further intervention, there were no other symptoms of neuropathy such as numbness or weakness. She returned to normal physical activity in the 6th postoperative week. We revisited the patient with 6-monthly hand MRIs in order to determine recurrence of the cyst.

Postoperatively 1 year, the patient had no symptoms, and recurrence was not observed in MRI or physical examination.

3. Discussion

Intraneural ganglion cysts of peripheral nerves may be seen in miscellaneous locations in the body. Most intraneural ganglia documented in the literature involved the common peroneal nerve in the fibular neck region. Involvement of the peripheral nerves of the upper extremities with an intraneural ganglion is an extremely rare presentation [5]. The most commonly involved peripheral nerve in this rare presentation is the ulnar nerve; the most common location is the elbow in an upper extremity [6].

The hand is a relatively rarer location than the elbow and wrist among intraneural ganglia. Involvement of the (main) ulnar nerve and its branches by intraneural ganglia such as the deep branch and the dorsal cutaneous branch in the wrist and hand has previously been reported [3,6]. Wang et al. documented 2 cases of intraneural ganglion cysts of the hand, involving the radial digital nerve of the index finger and dorsoulnar digital nerve of the thumb [7]. Similarly, Naam et al. reported intraneural ganglion cysts of the hand in relation with the superficial radial nerve, the digital nerve, and the dorsal branch of the digital nerve [6].

To our knowledge, no clinical reports have addressed an intraneural ganglion cyst with involvement of the superficial branch of the ulnar nerve on the hypothenar side of the hand. When viewed from this aspect, we might make the argument that our case report is unique in the literature.

A variety of theories such as degenerative (de novo), articular, tumoral, and extraneural intrusion have been proposed to enlighten the etiopathogenesis of intraneural ganglia [8]. In view of the fact that the pathogenesis of these cysts remains a matter of debate, the unifying articular (synovial) theory has increasingly been referred to as the latest and most affirmed, attributing articular (synovium) origin [2]. According to this theory, an articular branch takes the principal role regarding the formation of an intraneural ganglion cyst arising from a neighboring synovial joint, whether this articular branch is identified or not. The cyst fluid, following the path of least resistance, runs along the articular branch through the adjacent intraneural cyst in the direction of pressure fluxes.

The theory postulated that the unidentified joint connection was related with the cysts' rarity, radiologists' and surgeons' in experi-

Download English Version:

<https://daneshyari.com/en/article/5732912>

Download Persian Version:

<https://daneshyari.com/article/5732912>

[Daneshyari.com](https://daneshyari.com)