



Neuroendocrine tumor of the small intestine diagnosed with trans-abdominal ultrasonography: A case report

Kazuma Tsujimura*, Yasukatsu Takushi, Tsuyoshi Teruya, Kouji Iha, Morihito Ota, Atsushi Nakachi, Akira Gakiya

Department of Surgery, Tomishiro Central Hospital, Okinawa, Japan

ARTICLE INFO

Article history:

Received 9 November 2016

Received in revised form 5 January 2017

Accepted 5 January 2017

Available online 10 January 2017

Keywords:

Case report

Neuroendocrine tumor

Trans-abdominal ultrasonography

Small intestine

ABSTRACT

INTRODUCTION: Tumors of the small intestine are rare. In addition, clinical symptoms are nonspecific and neoplasm-related symptoms occur late. We report a case of neuroendocrine tumor (NET) of the small intestine that was diagnosed early with trans-abdominal ultrasonography (US).

PRESENTATION OF CASE: The patient was a 61-year-old man. Abdominal contrast-enhanced computed tomography (CT) was performed because the patient complained of abdominal pain. The CT showed a tumor lesion in the mesentery. Trans-abdominal US was undertaken to evaluate this tumor lesion, and a tumor lesion of the small intestine was found nearby. A diagnosis of lymph-node metastasis of a small-intestine tumor was made as a preoperative diagnosis. A laparotomy was performed with partial resection of the ileum, together with the small-intestine mesentery including an enlarged lymph node. Histological examination revealed NET of the ileum and lymph-node metastasis.

DISCUSSION: With the application of trans-abdominal US, we could diagnose lymph-node metastasis of a small-intestine tumor relatively early and before surgery.

CONCLUSION: Trans-abdominal US is useful in the diagnosis of small-intestine NET.

© 2017 The Author(s). Published by Elsevier Ltd on behalf of IJS Publishing Group Ltd. This is an open access article under the CC BY-NC-ND license (<http://creativecommons.org/licenses/by-nc-nd/4.0/>).

1. Introduction

Tumors of the small intestine are rare. In addition, clinical symptoms are nonspecific and neoplasm-related symptoms occur late. Further, gastroscopy and colonoscopy are not useful for the detection of these tumors. This rarity, nonspecific symptomatology, and inaccessibility make these tumors liable to being overlooked, with delayed or erroneous diagnosis [1]. Here, we report a case of neuroendocrine tumor (NET) of the small intestine that was diagnosed early with trans-abdominal ultrasonography (US).

2. Presentation of case

The patient was a 61-year-old man. His medical history included appendectomy decades previously, hyperlipidemia, and hyperuricemia. He presented at our department because of continuous lower abdominal pain. We performed abdominal contrast-enhanced computed tomography (CT) to investigate this pain. The CT revealed a tumor lesion of 15 mm in diameter in the mesentery at the level of the lower navel. The lesion showed partial contrast enhancement and calcification of the lesion edge

(Fig. 1A). Because the patient continued to have lower abdominal pain after admission, we additionally performed trans-abdominal US to evaluate this tumor lesion in the mesentery. The US revealed a well-defined hypoechoic, homogeneous oval (15 × 9 mm) tumor lesion in the small intestine near the tumor lesion in the mesentery (Fig. 1B). Color Doppler examination showed hypervascularity within the tumor (Fig. 1C). Re-evaluation of the CT images revealed a tumor lesion with weak contrast enhancement in the small intestine near the tumor lesion in the mesentery (Fig. 1D). At the time of these CT and US examinations, no metastasis to other organs was found. From these imaging findings we made a diagnosis of lymph-node metastasis of a small-intestine tumor as a preoperative diagnosis. The patient continued to have abdominal pain for three days after admission, so exploratory laparotomy was scheduled.

The laparotomy was performed with partial resection of the ileum, together with the small-intestine mesentery including an enlarged lymph node. Laparotomy revealed only one small-intestine tumor (15 mm in size) and one enlarged lymph node in the small-intestine mesentery (Fig. 2A).

Histological examination revealed NET of the ileum with invasion of the muscle layer (Fig. 2B, C). Chromogranin A staining of the specimens was positive, and the positive rate of Ki-67 staining was less than 2% (Fig. 2D, E). According to the Ki-67 labeling index and the 2010 WHO classification, the histologic classification

* Corresponding author at: Tomishiro Central Hospital, Department of Surgery, 25 Azaueda, Tomishiro-shi, Okinawa 901-0243, Japan.

E-mail address: tsujikazuma1978@yahoo.co.jp (K. Tsujimura).

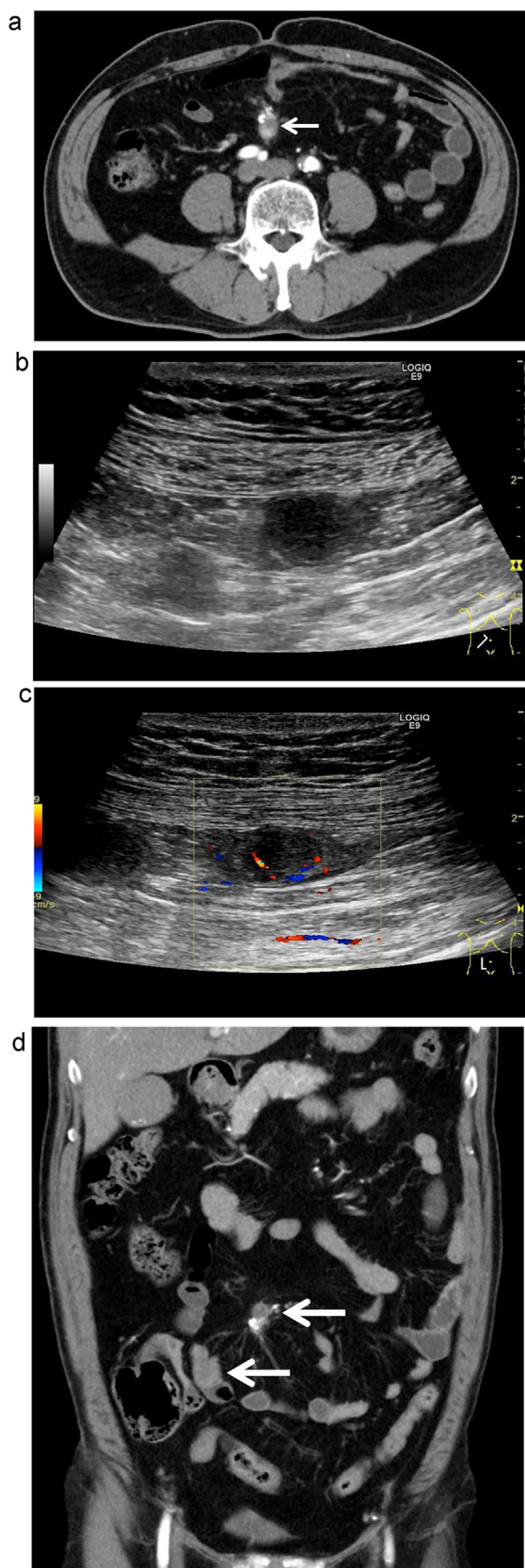


Fig. 1. A. A contrast-enhanced CT image shows a tumor lesion (arrow) with partial contrast enhancement and calcification of the lesion edge in the mesentery. The size of the tumor lesion is 15 mm. B. An US image shows a well-defined hypochoic, homogeneous tumor lesion in the small intestine near the tumor mass in the mesentery. The size of the tumor lesion is 15 × 9 mm. C. A color Doppler image shows hypervascularity within the tumor. D. A CT image shows a tumor lesion with weak contrast enhancement in the small intestine near the tumor lesion in the mesentery (arrows).

of the tumor was an NET Grade 1. The resected enlarged lymph node showed metastasis of the NET.

After the operation, the general condition of the patient was good. Six months after the operation, we performed US, abdominal contrast-enhanced CT, and positron emission tomography CT. These imaging modalities showed no recurrence.

3. Discussion

The rate of NETs originating from the small intestine is comparatively high, with a frequency of approximately 30% [2,3]. Small-intestine NETs differ from those occurring in other sites of the internal organ in that they are often at an advanced stage at the time of presentation. Tumors of the small intestine are usually discovered after resection of the bowel for symptoms of obstruction, or during exploration of the small intestine in search of a primary tumor after distant metastases have occurred [4]. The percentage of nonlocalized lesions in NETs of the small intestine is high at approximately 70%, and their 5-year survival rate is approximately 50% [2].

In the patient in this case, we performed abdominal contrast-enhanced CT because he complained of lower abdominal pain. Initially, we could only detect the tumor lesion in the mesentery on this CT. However, because the patient continued to have lower abdominal pain, we additionally performed trans-abdominal US to further investigate the tumor lesion in the mesentery and consequently detected a tumor lesion in the small intestine. While there are some disadvantages of trans-abdominal US, including that it is generally difficult, that the precision becomes lower when there is a lot of gas in the intestinal tract, and that comparison of trans-abdominal US images with other images (e.g., CT images) requires advanced operator skills, there are also several advantages to this method. Especially, trans-abdominal US has the benefit of using innocuous sound waves to produce an image. Therefore, trans-abdominal US can be performed on a routine basis at the bedside of the patients, at admission, and during the perioperative period [5].

Kala et al. reported that trans-abdominal US should be recommended as the preferred method in the diagnosis of small-intestinal tumors [6], and, in another previous study, primary NETs of the small intestine were visualized on trans-abdominal US in 13 of 17 patients (76.5%) [7]. In other words, small-intestine tumors may be detected with trans-abdominal US even if they are not detected with other imaging modalities. With the application of trans-abdominal US, we could diagnose lymph-node metastasis of a small-intestine tumor relatively early and before surgery. Therefore, it is particularly important that trans-abdominal US is performed in cases in which there is a tumor lesion in the mesentery of unknown cause. The US appearance of lesions of primary small-intestine NET has been previously reported. They appeared as hypochoic, homogeneous oval masses that were predominantly intraluminal and had a well-defined contour, and color Doppler examination showed hypervascularity in two of three cases [8]. In this case, the findings of trans-abdominal US were similar to those of the previous report.

Tumor size had the greatest effect on the frequency of metastatic disease at the time of surgery. The relationship between tumor size and the presence of metastases was investigated in the series by Moertel et al., which showed a metastatic rate of 2% for tumors less than 1 cm in diameter, 50% for tumors 1–2 cm in diameter, and 80% for tumors greater than 2 cm in diameter [9]. In this case, there was lymph-node metastasis on histological examination even though the size of the small-intestine NET was relatively small at 15 mm. In regards to prognosis, it is reported that patients with R0 resection of small-intestine malignancy have significantly high

Download English Version:

<https://daneshyari.com/en/article/5732916>

Download Persian Version:

<https://daneshyari.com/article/5732916>

[Daneshyari.com](https://daneshyari.com)