

Contents lists available at [ScienceDirect](http://www.sciencedirect.com)

International Journal of Surgery Case Reports

journal homepage: www.casereports.com

Formation of ring-shaped lateral meniscus following anterior cruciate ligament reconstruction: A case report



Masataka Fujii^a, Takayuki Furumatsu^{a,*}, Shinichi Miyazawa^a, Takaaki Tanaka^b, Hiroto Inoue^a, Yuya Kodama^a, Toshifumi Ozaki^a

^a Department of Orthopaedic Surgery, Okayama University, Graduate School of Medicine, Dentistry, and Pharmaceutical Sciences, 2-5-1 Shikata-cho, Kita-ku, Okayama 700-8558, Japan

^b Department of Orthopaedic Surgery, Sumitomo Besshi Hospital, Japan

ARTICLE INFO

Article history:

Received 17 November 2016
Received in revised form 23 January 2017
Accepted 23 January 2017
Available online 30 January 2017

Keywords:

Meniscus
Knee
Ring-shaped lateral meniscus
Anterior cruciate ligament reconstruction
Second-look arthroscopy

ABSTRACT

INTRODUCTION: We presented the first case in the literature of inter-horn bridge formation involved in ring-shaped lateral meniscus after anterior cruciate ligament (ACL) reconstruction.

PRESENTATION OF CASE: A 22-year-old man underwent anatomic double-bundle ACL reconstruction using semitendinosus tendon autograft. At the surgery, the lateral meniscus showed a normal appearance without meniscal tears and had no instability. There were no meniscal anomalies such as discoid meniscus and ring-shaped meniscus. Magnetic resonance image examination was performed before second-look arthroscopy at 1 year postoperatively. A coronal plane showed a small triangular fragment located at the medial border of the lateral tibial plateau. An axial plane demonstrated a ring-shaped lateral meniscus. On second-look arthroscopy, there was a meniscus-like tissue formation that connected the anterior horn to the posterior horn of the lateral meniscus at the lateral intercondylar tubercle.

DISCUSSION: Ring-shaped meniscus is an extremely rare malformation of the meniscus. Our hypothesis was that drilling debris and remaining remnant of ACL might induce a scar tissue formation.

CONCLUSION: This is the first case in the literature of inter-horn bridge formation involved in ring-shaped lateral meniscus following ACL reconstruction.

© 2017 The Authors. Published by Elsevier Ltd on behalf of IJS Publishing Group Ltd. This is an open access article under the CC BY-NC-ND license (<http://creativecommons.org/licenses/by-nc-nd/4.0/>).

1. Introduction

Abnormalities of the human meniscus, including discoid meniscus, double-layered meniscus, and ring-shaped meniscus, have been reported. The prevalence of ring-shaped menisci is extremely rare, with an incidence of 0.9%–2.4% in Asian population [1,2]. There are some reports of symptomatic ring-shaped lateral meniscus [3,4]. They found ring-shaped lateral meniscus incidentally during arthroscopy. These authors believe that this anomaly seems to be congenital. Monllau et al. [5] defined ring-shaped meniscus as the meniscus that had a peripheral attachment with both anterior and posterior horns connected by an inter-horn meniscal bridge. In this case report, we presented the first case in the literature of inter-horn bridge formation involved in ring-shaped lateral meniscus after anterior cruciate ligament (ACL) reconstruction. This work has been reported in line with the SCARE criteria [6].

2. Case report

This study received the approval of our Institutional Review Board and the patient gave his informed consent for this case report. A 22-year-old man initially presented with ACL rupture to his left knee, resulting from an injury in the valgus knee position during Double Dutch jump rope. Magnetic resonance imaging (MRI) demonstrated a complete tear of the ACL without meniscal tear (Fig. 1A, B). Three months after the injury, the patient underwent anatomic double-bundle ACL reconstruction using semitendinosus tendon autograft in our hospital. On arthroscopic examination, the ACL remnant tissue attached on the femur (Crain type III) [7]. The lateral meniscus showed a normal appearance without meniscal tears and had no instability. There were no meniscal anomalies such as discoid meniscus and ring-shaped meniscus (Fig. 2A). Femoral tunnels were created with the outside-in drilling technique. To prevent the damage to the anterior insertion of the lateral meniscus, the lateral portion of the ACL tibial footprint was preserved during tibial tunnel creation (Fig. 2B) [8]. Femoral fixation was achieved using an EndoButton system (Smith & Nephew, Andover, MA). Graft fixations were performed with 30 N for anteromedial bundle and 20 N for posterolateral bundle using double-spike plates (Meira, Aichi, Japan). Knee motion and partial weight-bearing were

* Corresponding author.

E-mail address: matino@md.okayama-u.ac.jp (T. Furumatsu).

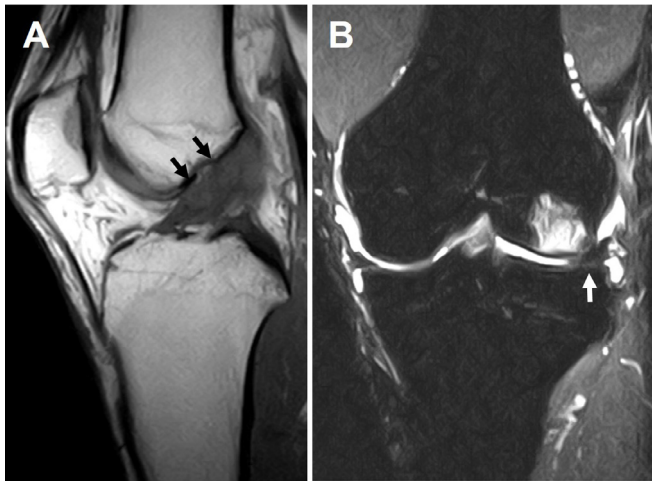


Fig. 1. MR images before ACL reconstruction surgery. (A) Sagittal T1-weighted image shows a ruptured ACL (arrows). (B) Coronal T2-weighted image demonstrates normal and nondisplaced meniscus (arrow).

Table 1
Clinical evaluation outcomes.

	Preoperative period	Postoperative period
KT-2000 measurement (mm)	+4 mm	+2 mm
IKDC score	67.8	86.2
Lysholm score	84	100
Tegner activity score	6	6
KOOS score	90.5	83.3

started at 1 week postoperatively. Full weight-bearing was allowed at 4 weeks postoperatively. No clinical symptoms on his knee were detected during 1-year postoperative period. Follow-up evaluations revealed the presence of a painless knee without any instability and a full range of motion of the knee. There was no history of additional injuries during follow-up period. Preoperative and postoperative clinical evaluation outcomes at 1 year follow-up were shown in [Table 1](#).

MRI examination was performed at 1 year postoperatively. A coronal plane of MR images showed a small triangular fragment located at the medial border of the lateral tibial plateau ([Fig. 3A](#)). An axial plane demonstrated a ring-shaped lateral meniscus ([Fig. 3B](#)). The patient underwent second-look arthroscopy in conjunction with hardware removal. Informed consent was obtained from the patient to allow arthroscopic examination of the knee during

hardware removal. On second-look arthroscopy, we carefully observed the reconstructed ACL and menisci using a probing technique. The surface of the reconstructed bundles was covered by synovial tissues. There was a meniscus-like tissue formation that connected the anterior horn to the posterior horn of the lateral meniscus at the lateral intercondylar tubercle ([Fig. 4A, B](#)). The anterior and posterior horns were firmly attached to their original insertions. This inter-horn bridging tissue was stable and showed no impingement finding. Therefore we did not perform resection and biopsy of the bridging tissue at second-look arthroscopy. This patient was able to return to his sports activities at 3 weeks later without any complaints.

3. Discussion

Ring-shaped meniscus is an extremely rare malformation of the meniscus. Noble first reported a ring-shaped lateral meniscus of one case as an incidental finding during autopsy in 1975 [9]. Since then, there are some reports of ring-shaped menisci with or without clinical symptoms [1,3,4,10]. In a large cadaveric study, the prevalence of ring-shaped meniscus was reported 0.9% (4/437) in Japanese population [2]. According to the previous reports, ring-shaped menisci have been believed the congenital anomaly because of the free from traumatic episode. On the other hand, Soejima et al. [11] reported an exceptional case of regeneration of ring-shaped meniscus-like tissue after partial resection of a discoid lateral meniscus with ACL reconstruction. They suggested that the meniscus-like tissue formation might be induced by bone marrow-derived cells and metaplasia of the ACL remnants. Bisicchia et al. [12] reported a case of meniscal re-growth in a child. After partial meniscectomy of incomplete discoid lateral meniscus, the preserved meniscus showed a re-growth and restored the shape of incomplete discoid meniscus. They considered that the re-growth of the discoid meniscus might show variant morphogenesis.

In our case, the lateral meniscus was completely normal at the reconstruction surgery. In addition, there were no major traumas during the period between the ACL reconstruction and second-look arthroscopy. We considered that the ring-shaped meniscus-like tissue was spontaneously formed after ACL reconstruction. To the best of our knowledge, there are no literatures about the development of ring-shaped meniscus-like tissue connected the anterior horn to the posterior horn of the lateral meniscus after ACL reconstruction. It was not certain why the inter-horn bridging tissue was formed. Our hypothesis was that drilling debris derived from bone tunnel creation may contain mesenchymal stem cells and growth factors for inducing an excessive scar tissue formation at the intercondylar

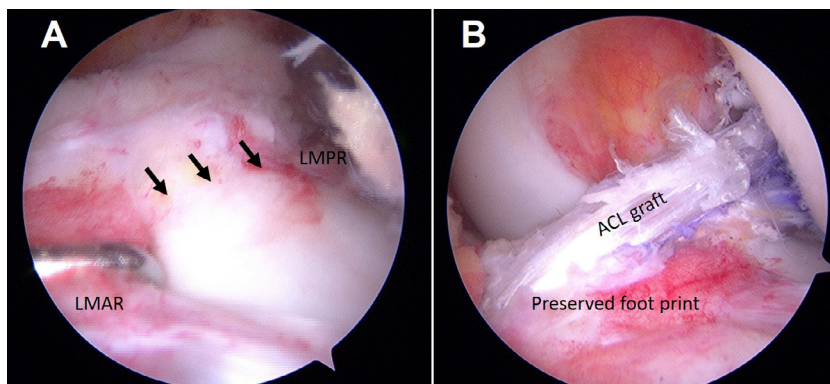


Fig. 2. Arthroscopic findings at the time of ACL reconstruction. (A) There was no meniscal tissue that connected between the anterior and posterior meniscal roots (arrows). (B) The lateral portion of the ACL tibial footprint was preserved during tibial tunnel creation. LMAR: lateral meniscus anterior root, LMPR: lateral meniscus posterior root.

Download English Version:

<https://daneshyari.com/en/article/5732954>

Download Persian Version:

<https://daneshyari.com/article/5732954>

[Daneshyari.com](https://daneshyari.com)