



## Research report

# Segmentation of the inferior longitudinal fasciculus in the human brain: A white matter dissection and diffusion tensor tractography study



Francesco Latini<sup>a,\*</sup>, Johanna Mårtensson<sup>b</sup>, Elna-Marie Larsson<sup>b</sup>, Mats Fredrikson<sup>c,d</sup>, Fredrik Åhs<sup>c,d</sup>, Mats Hjortberg<sup>e</sup>, Håkan Aldskogius<sup>f</sup>, Mats Ryttefjors<sup>a</sup>

<sup>a</sup> Department of Neuroscience, Neurosurgery, Uppsala University, Uppsala, Sweden

<sup>b</sup> Department of Surgical Sciences, Radiology, Uppsala University, Uppsala, Sweden

<sup>c</sup> Department of Psychology, Uppsala University, Uppsala, Sweden

<sup>d</sup> Department of Clinical Neuroscience, Karolinska Institute, Stockholm, Sweden

<sup>e</sup> Department of Medical Cell Biology, Education, Uppsala University, Uppsala, Sweden

<sup>f</sup> Department of Neuroscience, Regenerative Neurobiology, Uppsala University, Uppsala, Sweden

## ARTICLE INFO

## Article history:

Received 10 April 2017

Received in revised form 8 August 2017

Accepted 1 September 2017

Available online 9 September 2017

## Keywords:

DTT

ILF

White matter

Occipital-temporal connectivity

Social cognition

Visual memory

## ABSTRACT

The inferior longitudinal fascicle (ILF) is one of the major occipital-temporal association pathways. Several studies have mapped its hierarchical segmentation to specific functions. There is, however, no consensus regarding a detailed description of ILF fibre organisation. The aim of this study was to establish whether the ILF has a constant number of subcomponents. A secondary aim was to determine the quantitative diffusion properties of each subcomponent and assess their anatomical trajectories and connectivity patterns.

A white matter dissection of 14 post-mortem normal human hemispheres was conducted to define the course of the ILF and its subcomponents. These anatomical results were then investigated in 24 right-handed, healthy volunteers using in vivo diffusion tensor imaging (DTI) and streamline tractography. Fractional anisotropy (FA), volume, fibre length and the symmetry coefficient of each fibre group were analysed. In order to show the connectivity pattern of the ILF, we also conducted an analysis of the cortical terminations of each segment. We confirmed that the main structure of the ILF is composed of three constant components reflecting the occipital terminations: the fusiform, the lingual and the dorsolateral-occipital. ILF volume was significantly lateralised to the right. The examined indices of ILF subcomponents did not show any significant difference in lateralisation.

The connectivity pattern and the quantitative distribution of ILF subcomponents suggest a pivotal role for this bundle in integrating information from highly specialised modular visual areas with activity in anterior temporal territory, which has been previously shown to be important for memory and emotions.

© 2017 Elsevier B.V. All rights reserved.

**Abbreviations:** AF, Arcuate fasciculus; Cu, Cuneal branch; DLOC, dorso-lateral occipital branch; DTI, Diffusion tensor imaging; DTT, Diffusion tensor tractography; FA, Fractional anisotropy; Fu, Fusiform branch; IFOF, Inferior fronto-occipital fasciculus; ITG, Inferior temporal gyrus (T3); Li, Lingual branch; LOTG, Lateral occipital-temporal gyrus (T4); MLF, Middle longitudinal fasciculus; MOG, Middle occipital gyrus; MRI, Magnetic resonance imaging; MTG, Middle temporal gyrus (T2); PHG, Parahippocampal gyrus (T5); ROA, Region of avoidance; ROI, Region of interest; SLF, Superior longitudinal fasciculus; SOG, Superior occipital gyrus; STG, Superior temporal gyrus (T1); UF, Uncinate fasciculus; VO, Vertical occipital fasciculus.

\* Corresponding author at: Department of Neuroscience, Neurosurgery, Uppsala University, S-751 85 Uppsala, Sweden.

E-mail address: [francesco.latini@neuro.uu.se](mailto:francesco.latini@neuro.uu.se) (F. Latini).

## 1. Introduction

The inferior longitudinal fasciculus (ILF), traditionally considered the major occipital-temporal association fibre pathway, connects the occipital extrastriate cortex with the temporal lobe and vice versa (Crosby et al., 1962; Dejerine, 1895; Gloor, 1997). Its anatomical description (Dejerine, 1895; Polyak, 1957) has been the subject of several mutually conflicting studies. Some authors denied its existence because of the unclear results obtained in non-human brains (Polyak, 1957; Putnam, 1926; Tusa and Ungerleider, 1985). However, while the anatomical evidence for an ILF is disputed, several neuropsychological syndromes have been associated with a disruption of this specific temporo-occipital connection. These syndromes include, due to a bilateral damage, associative visual agnosia (Jankowiak and Albert, 1994)

and visual amnesia (Ross, 1980), while prosopagnosia (Benson et al., 1974; Meadows, 1974) and visual hypo-emotionality (Bauer, 1982; Sierra et al., 2002; Geschwind, 1965a,b; Girkin and Miller, 2001) have been associated to a right lesion of the temporal-occipital white matter.

Using diffusion tensor imaging (DTI), several authors have confirmed the presence of this constant longitudinal pathway in humans (Mori et al., 2002; Catani et al., 2002, 2003; Wakana et al., 2007; Catani and Thiebaut de Schotten, 2008; Fernandez Miranda et al., 2008; Hasan et al., 2010), and many other studies have suggested that the ILF is implicated in some forms of autism, Asperger's syndrome, schizophrenia and alexia (Ashtari et al., 2007; Epelbaum et al., 2008; Pugliese et al., 2009; Koldewyn et al., 2014)

This complex and variable pattern of symptoms seems to be related to a complex hierarchical organisation of the ILF fibres, which may reflect the activity of several functional networks, as demonstrated by non-invasive studies and direct cortical/subcortical stimulation (Cohen et al., 2004; Duffau, 2008; Mandonnet et al., 2009; Sarubbo et al., 2015; Zemmoura et al., 2015). Unfortunately, despite the general anatomical validation provided by several studies based on white matter dissection of post-mortem brains (Mori et al., 2002; Fernandez Miranda et al., 2008; De Benedictis et al., 2014; Latini, 2015; Latini et al., 2015a), there is no consensus regarding a detailed description of ILF fibre segregation, which is still a matter of investigation and debate (Catani et al., 2003; Latini, 2015).

The classical description of the ILF mentions three (Crosby et al., 1962) or four (Catani et al., 2003) distinct occipital branches. These arise in extrastriate cortical regions on the dorso-lateral surface of the occipital lobe, dorso-medially from the cuneus and on the ventral surface from the posterior lingual gyrus and fusiform gyrus. Accord-

ing to the modern connectomic theory (Catani and Ffytche, 2005; Ffytche and Catani, 2005; De Benedictis and Duffau, 2011; Catani et al., 2012), the whole ILF can in theory support, through each sub-component, parallel and bidirectional segregated networks between occipital extrastriate cortex and temporal areas. A desynchronisation or an altered balance between the ILF branches and closer fibre bundles can create a variable pattern of positive (e.g. visual hallucinations) or negative symptoms (e.g. prosopagnosia, the inability to recognise familiar faces). To date, little data regarding the analysis of these branches have been reported in the literature (Catani et al., 2003; Latini, 2015; Latini et al., 2015a), so a more detailed segmentation of the ILF with a quantitative and anatomical inter-hemispheric analysis including in vivo and post-mortem analyses may help to clarify the anatomy of this occipito-temporal pathway with functional implications.

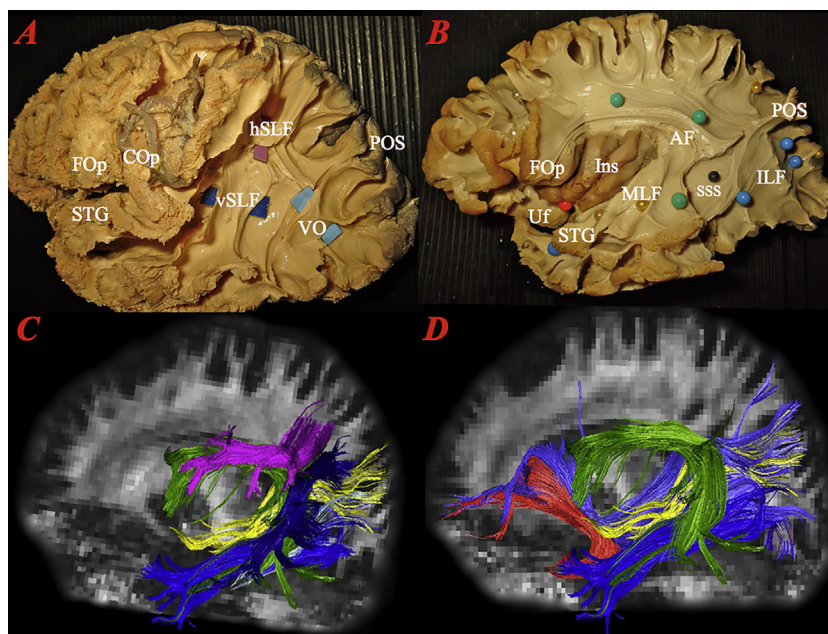
The first aim of this study was to establish whether a constant organisation of fibres exists among the ILF subcomponents. This was accomplished by fibre dissections of post-mortem human brains. Secondly, this analysis of ILF connectivity patterns was used to acquire anatomical and quantitative information on each sub-component obtained from in vivo DTI tracking. Finally, the quantitative and anatomical results are discussed in the light of the numerous published studies on the proposed functional involvement of this bundle.

## 2. Results

### 2.1. Anatomical dissection

#### 2.1.1. Dissection of the lateral surface

The dissection of the lateral surface started with the exposure of the short and intermediate fibres of the indirect (vertical)



**Fig. 1.** Spatial relationship between the white matter bundles surrounding the ILF. **A)** Superficial step of white matter dissection in a left hemisphere showing the vSLF (dark blue), the VO (light blue) and the hSLF (pink). **B)** Deeper layer of white matter dissection of a left hemisphere with the AF fibres partially cut in order to show the SSS (black pin), which contains the MLF (yellow) fibres and more medially the IFOF. The ILF fibres (blue pins) connect the occipital region and the anterior temporal pole. At this level, the UF fibres (red pin) share the medial and cranial cortical territories with the ILF. **C)** Superficial white matter bundles (reconstructed during the subject-by-subject tractography) showing the superficial vertical segment of the SLF (dark blue), the AF (green) and the VO (grey) in respect of the ILF (blue). **D)** Deeper reconstruction (during the subject-by-subject DTT) of the ILF (blue) running medial in respect to the AF (green) within the sagittal stratum of Sachs. The MLF (yellow) runs cranial and medial from the STG to the POS region within the SSS. The IFOF (purple) is more medial within the SSS but shares with the ILF basically all the occipital cortical terminations. The UF (red) is in close relationship with the anterior terminations of the ILF on the medial and cranial portion of the temporal pole. SLF: superior longitudinal fasciculus; AF: arcuate fasciculus; VO: vertical occipital fasciculus; hSLF: horizontal segment of superior longitudinal fasciculus; vSLF: vertical segment of superior longitudinal fasciculus; ILF: inferior longitudinal fasciculus; MLF: middle longitudinal fasciculus; IFOF: inferior fronto-occipital fasciculus; UF: uncinata fasciculus; FOp: frontal operculum; COp: central operculum; STG: superior temporal gyrus; POS: parieto-occipital sulcus; SSS: sagittal stratum of Sachs. (For interpretation of the references to colour in this figure legend, the reader is referred to the web version of this article.)

Download English Version:

<https://daneshyari.com/en/article/5736468>

Download Persian Version:

<https://daneshyari.com/article/5736468>

[Daneshyari.com](https://daneshyari.com)