



Coinfection by *Ureaplasma* spp., *Photobacterium damsela* and an *Actinomyces*-like microorganism in a bottlenose dolphin (*Tursiops truncatus*) with pleuropneumonia stranded along the Adriatic coast of Italy



Gabriella Di Francesco^a, Cesare Cammà^a, Valentina Curini^a, Sandro Mazzariol^b, Umberto Proietto^c, Cristina Esmeralda Di Francesco^d, Nicola Ferri^a, Andrea Di Provvido^a, Giovanni Di Guardo^{d,*}

^a Istituto Zooprofilattico Sperimentale dell'Abruzzo e del Molise "G. Caporale", Teramo, Italy

^b University of Padua, Department of Comparative Biomedicine and Food Science, Legnaro, Padova, Italy

^c Veterinary Practitioner, Giulianova, Teramo, Italy

^d University of Teramo, Faculty of Veterinary Medicine, Località Piano d'Accio, Teramo, Italy

ARTICLE INFO

Article history:

Received 27 October 2015

Received in revised form 12 January 2016

Accepted 29 January 2016

Keywords:

Bottlenose dolphin

Pleuropneumonia

Ureaplasma spp.

Photobacterium damsela

Actinomyces

Adriatic Sea

ABSTRACT

A case of pleuropneumonia is reported in an adult male bottlenose dolphin (*Tursiops truncatus*) found stranded in 2014 along the Central Adriatic coast of Italy. A severe pyogranulomatous pneumonia and thoracic lymphadenopathy were present at necropsy. Numerous *Splendore-Hoeppli* bodies were found microscopically scattered throughout the lung. Histochemical evidence of *Actinomyces*-like organisms was obtained from the pulmonary parenchyma, with a strain of *Photobacterium damsela* subsp. *piscicida* and *Ureaplasma* spp. being also isolated from the same tissue. For the latter, a genome fragment of approximately 1400 bp from the 16s rDNA was amplified and sequenced. BLAST analysis revealed 100% identity with an uncultured *Ureaplasma* spp. (JQ193826.1).

© 2016 Elsevier Ltd. All rights reserved.

In recent years, there has been a growing interest in aquatic mammal health, ecology and conservation. This has enabled, among others, the expansion of our knowledge of infectious diseases in free-living pinnipeds and cetaceans, some of which are also considered emerging public health issues (Van Bresseem et al., 2009).

Within this framework, a "National Cetacean Stranding and Health Surveillance Network" was created in 2010 in Italy, under the joint supervision of the Ministry for the Environment and of the Ministry of Health, in order to standardize the diagnostic protocols and improve the collection of data obtained from stranded cetaceans.

Aim of the present work is to describe the anatomico-histopathological changes observed in a bottlenose dolphin (*Tursiops truncatus*) stranded along the Central Adriatic coast of Italy, along with the identification and characterization of the microbial pathogens associated with the lung lesions.

An adult male bottlenose dolphin, found stranded lifeless in July 2014 along the Central Adriatic Sea coast (Pineto, Abruzzo Region, Italy), was subjected to a detailed *post mortem* examination at the Istituto Zooprofilattico Sperimentale dell'Abruzzo e del Molise "G. Caporale" (Teramo, Italy). The animal's decomposition code was 3,

according to a standardized and widely utilized protocol (Geraci and Lounsbury, 2005). During necropsy, body tissues were both fixed in 10% neutral buffered formalin and frozen at -20°C for microbiological and ecotoxicological investigations. Faecal samples were also collected, while blood clots were obtained from the heart chambers and centrifuged, with the resulting serum being stored at -20°C .

Tissues were routinely processed for histopathological investigations, with periodic acid Schiff (PAS), Grocott and Ziehl-Neelsen staining techniques being additionally applied on selected lung sections and Gram stain on unfixed pulmonary tissue smears. Immunohistochemistry (IHC) against *Ureaplasma* spp. was performed on selected lung tissue sections, utilizing a polyclonal antiserum raised in rabbits, while IHC against *Morbillivirus* was carried out on selected lung, pulmonary lymph node and brain tissue sections with a commercially available, murine monoclonal antibody raised against a highly conserved region of the *Canine Distemper Virus* (CDV) nucleoprotein (N) antigen (VMRD Inc., USA). Suitable positive and negative control tissue specimens were included in each IHC run. Furthermore, biomolecular (PCR, RT-PCR) investigations for *Brucella* spp. and *Morbillivirus* were performed on a range of tissues utilizing two previously published protocols (Frisk et al., 1999; OIE, 2011), while serological investigations for *Morbillivirus*, *Toxoplasma gondii* and *Brucella* spp. were carried out based on reported methods (Di Guardo et al., 2010). Detailed

* Corresponding author.

E-mail address: gdiuardo@unite.it (G. Di Guardo).

microbiological analyses were additionally performed on all major organs, with the lung being cultured in supplemented PPLO-selective media (Difco™ and BBL™ PPLO broth and PPLO agar, BD Biosciences, NJ, USA). Furthermore, biomolecular investigations were carried out on DNA extracted from the pulmonary tissue. A portion of the 16S rDNA for *Mycoplasma* spp. (Kumar et al., 2013), along with a fragment of the gene coding for a penicillin-binding protein (PBP) of *Photobacterium damsela* (Serracca et al., 2011), as well as with an approximately 550 bp long sequence of the rRNA internal transcribed spacer region (ITS) for detecting fungi (Schoch et al., 2012), were amplified. The obtained PCR products were then sequenced and submitted for a BLAST search (<http://blast.ncbi.nlm.nih.gov/Blast.cgi>).

Finally, biomolecular (PCR) investigations aimed at detecting *Mycoplasma* spp. were performed from the aforementioned PPLO-selective media. Once DNA was extracted from broth-derived pellets, the 16S rDNA was amplified by a modified PCR protocol (Kumar et al., 2013), with PCR products being sequenced and submitted for a BLAST search (<http://blast.ncbi.nlm.nih.gov/Blast.cgi>).

Macroscopically, a diffuse and severe, bilateral pleuropneumonia was observed, with the lung being tightly adherent to the costal pleural surface and with pulmonary lesions characterized by multifocal and coalescing necrotic areas (Fig. 1, a–b). Furthermore, a loco-regional lymphadenopathy involving the pulmonary, mediastinal and tracheobronchial lymph nodes was apparent, with mesenteric lymph nodes also exhibiting a marked enlargement.

Histologically, variably sized, multifocal and coalescing pyogranulomatous lesions were seen scattered throughout the lung tissue. The aforementioned pyogranulomas showed central necrosis, while several aggregates of an intensely eosinophilic and amorphous material consistent with *Splendore-Hoeppli* bodies (so-called “*Splendore-Hoeppli* phenomenon”) could be simultaneously found in close proximity to, or within pyogranulomatous lesions (Fig. 2, a). Pulmonary tissue smears showed Gram-positive, filamentous bacterial organisms and colonies (Fig. 2, b). These microbial aggregates, which were frequently observed either within or at the periphery of the aforementioned pyogranulomatous lesions, were positively stained also by Grocott (Fig. 2, c) and negatively stained by PAS and Ziehl–Neelsen techniques. Their morphological and histochemical staining features were consistent with those of *Actinomycetales*. Bacterial aggregates were also seen neighbouring slight, lymphoplasmacytic inflammatory foci affecting the dolphin's myocardium. Additionally, a moderate lymphoid cell depletion was found in the pulmonary, mediastinal, tracheobronchial and mesenteric lymph nodes.

Biomolecular, IHC and serological investigations for *Morbillivirus*, *T. gondii* and *Brucella* spp. yielded negative results, similarly to biomolecular analyses and cultures for fungi, mycobacteria and *Brucella* spp.

Microbiological examinations allowed the isolation of *P. damsela* and an *Ureaplasma*-like agent from the lung tissue. For the latter, a genome fragment of approximately 1400 bp from the 16S rDNA was

amplified and sequenced. BLAST analysis revealed 100% identity with an uncultured *Ureaplasma* spp. (JQ193826.1). Moreover, BLAST analysis of a fragment of the gene coding for a penicillin-binding protein (PBP) of approximately 290 bp in length revealed 99% identity of our bacterial isolate with *P. damsela* subsp. *piscicida* (EU164926.1). Despite the repeated attempts of biomolecular characterization, it was not possible to identify the *Actinomyces*-like agent detected in close association with the pyogranulomatous lung lesions.

On the basis of the above results, coupled with those reported in the scientific literature (Baker, 1992; Di Guardo et al., 1995), we believe that the extensive lung lesions played an important role in the stranding and subsequent death of the bottlenose dolphin. Although the chronology of the infection with the three concerned pathogens cannot be defined, the pyogranulomatous morphology of the pulmonary lesions, associated with the simultaneous occurrence of *Splendore-Hoeppli* bodies, strongly supports an *Actinomyces*-like/*Nocardia*-like or, alternatively, a fungal aetiology (Higgins, 2000). Indeed, a number of fungal, parasitic and bacterial infections have been causally linked to the occurrence of the “*Splendore-Hoeppli* phenomenon”, with actinomycosis and nocardiosis being also included among the latter conditions (Hussein, 2008). In this respect, we believe that an *Actinomyces*-like rather than a *Nocardia*-like agent was involved in the determinism of the pyogranulomatous inflammatory lesions found in the dolphin under study, since *Nocardia* spp. is often acid-fast, while *Actinomyces* spp. is a non-acid-fast microorganism (Robboy and Vickery, 1970). Additionally, since the pathogenic role of *P. damsela* for cetaceans — as well as for other mammalian species — still remains unsolved (Casalone et al., 2014), we cannot assign a precise aetiological responsibility to this bacterial agent for the lung lesions reported herein. The isolation from the dolphin's pulmonary parenchyma of an *Ureaplasma* spp. strain exhibiting a 100% sequence homology with an uncultured *Ureaplasma* spp. agent (JQ193826.1) is also of interest as this microorganism has not been hitherto identified in cetaceans. Conversely, *Mycoplasma* spp. infection has been reported in free-living pinnipeds (Geraci et al., 1982; Higgins, 2000) and in cetaceans stranded in Scottish waters (Foster et al., 2011).

Ureaplasma spp. infection has been documented in human patients and in non-human primates (Kanamoto et al., 1983; Neto et al., 2013; Taylor-Robinson, 2013; Gancia et al., 2014), as well as in cattle, goat, sheep, swine, cats, dogs, raccoon dogs (*Nyctereutes procyonoides viverrinus*) and chickens (Kanamoto et al., 1983; Burgher et al., 2014; dos Santos et al., 2014; Gaeti et al., 2014). *Ureaplasma* spp. has been detected in ovine semen samples (dos Santos et al., 2014), being additionally responsible for pustular vulvovaginitis and abortion in cattle (Gaeti et al., 2014), alongside with urethral inflammation in male chimpanzees (*Pan troglodytes*) (Taylor-Robinson, 2013). *Ureaplasma* spp. infection can also occur in utero or during the perinatal period in human premature infants, with some individuals developing a prominent lung pro-inflammatory and pro-fibrotic response, resulting at its turn in an increased risk of bronchopulmonary dysplasia occurrence (Gancia et al.,

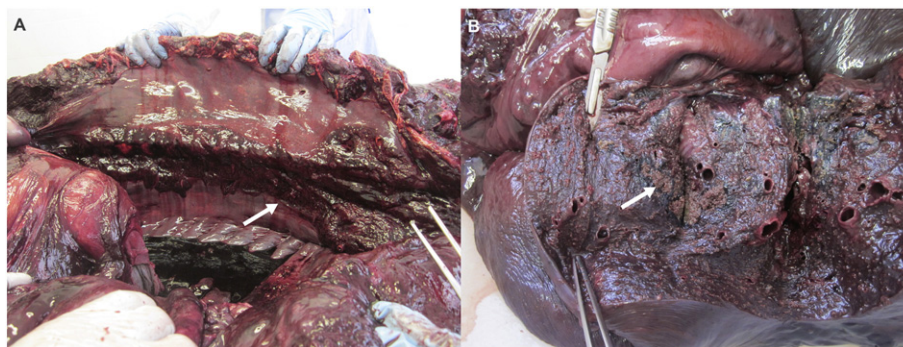


Fig. 1. Bottlenose dolphin (*Tursiops truncatus*). Thoracic cavity. Extensive adhesions (arrow) are seen between the lung and the costal pleural surfaces (a); lung. Multifocal to coalescing necrotic foci (arrow) are found scattered throughout the parenchyma (b).

Download English Version:

<https://daneshyari.com/en/article/5794382>

Download Persian Version:

<https://daneshyari.com/article/5794382>

[Daneshyari.com](https://daneshyari.com)