Heart & Lung 44 (2015) 481–485

Contents lists available at ScienceDirect

Heart & Lung

journal homepage: www.heartandlung.org

Myocardial edema in Takotsubo syndrome mimicking apical hypertrophic cardiomyopathy: An insight into diagnosis by cardiovascular magnetic resonance

Cemil Izgi, MD [a], Sanjoy Ray, MD [b], Evangelia Nyktari, MD [a], Francisco Alpendurada, MD, PhD [a,c], Alexander R. Lyon, MD, PhD [c], Sudhir Rathore, MBBS, MD [b], Arun John Baksi, MBBS, PhD [a,c,*]

[a] Cardiovascular Magnetic Resonance Unit, Royal Brompton Hospital, SW3 6NP London, UK
[b] Department of Cardiology, Frimley Park Hospital NHS Foundation Trust, Frimley GU16 7UJ, Surrey, UK
[c] NIHR Cardiovascular Biomedical Research Unit, Royal Brompton and Harefield NHS Trust, Imperial College London, London, UK

ARTICLE INFO

Article history:
Received 5 May 2015
Received in revised form
26 July 2015
Accepted 31 July 2015
Available online 25 August 2015

Keywords:
Takotsubo syndrome
Myocardial hypertrophy
Hypertrophic cardiomyopathy
Edema
Cardiovascular magnetic resonance

ABSTRACT

Myocardial edema is one of the characteristic features in the pathogenesis of Takotsubo syndrome. We report a middle aged man who presented with typical clinical and echocardiographic features of apical variant of Takotsubo syndrome. However, a cardiovascular magnetic resonance study performed 10 days after presentation did not show any apical 'ballooning' but revealed features of an apical hypertrophic cardiomyopathy on cine images. Tissue characterization with T2 weighted images proved severe edema as the cause of significantly increased apical wall thickness. A follow-up cardiovascular magnetic resonance study was performed 5 months later which showed that edema, wall thickening and the appearance of apical hypertrophic cardiomyopathy all resolved, confirming Takotsubo syndrome as the cause of the initial appearance. As the affected myocardium most commonly involves the apical segments, an edema induced increase in apical wall thickness may lead to appearances of an apical hypertrophic cardiomyopathy rather than apical ballooning in the acute to subacute phase of Takotsubo syndrome.

© 2015 Elsevier Inc. All rights reserved.

Introduction

Myocardial edema is one of the characteristic features in the pathogenesis of Takotsubo syndrome (or stress-induced cardiomyopathy).[1] It is not seen on routine echocardiography but can be demonstrated in the majority of patients on edema sensitive cardiac magnetic resonance (CMR) imaging sequences.[1] Edema usually does not cause any grossly visible increase in wall thickness but rarely may be severe enough to appear as significant 'hypertrophy' on echocardiography as well as CMR cine images. The most common anatomical variant of Takotsubo syndrome involves the apical segments, and the edema-dependent increase in apical wall thickness may raise the suspicion of apical hypertrophic cardiomyopathy. Recently there have been reports of cases in which significantly increased apical wall thickness during the course of Takotsubo syndrome were observed,[2,3] but no CMR studies were available in these cases to demonstrate the edema as the cause of the apparent hypertrophy.

Case report

A 44-year-old man presented with acute onset crushing central chest pain which radiated to the left arm and was associated with vomiting. There was no previous history of coronary artery disease, angina or a stressful trigger. Past medical history included hypertension (well-controlled with ramipril 7.5 mg/day and indapamide 1.25 mg/day) and ankylosing spondylitis with previous spine surgery. He did not have any history of diabetes. He was smoking 15–20 cigarettes a day and occasionally cannabis but he did not report use of cannabis or any other illicit drug prior to presentation. The patient's typical alcohol consumption was one bottle of wine every day, but he had consumed 2.5 bottles in the evening prior to presentation. On admission, he was hemodynamically stable with normal respiratory and cardiac auscultatory findings. His 12 lead

Sources of funding: None.
Declaration of potential conflict of interest: No relationships.
* Corresponding author. CMR Unit, Royal Brompton Hospital, Sydney Street, SW3 6NP London, UK. Tel.: +44 207 351 8800; fax: +44 207 351 8816.
E-mail address: J.Baksi@rbht.nhs.uk (A.J. Baksi).

0147-9563/$ – see front matter © 2015 Elsevier Inc. All rights reserved.
http://dx.doi.org/10.1016/j.hrtlng.2015.07.008

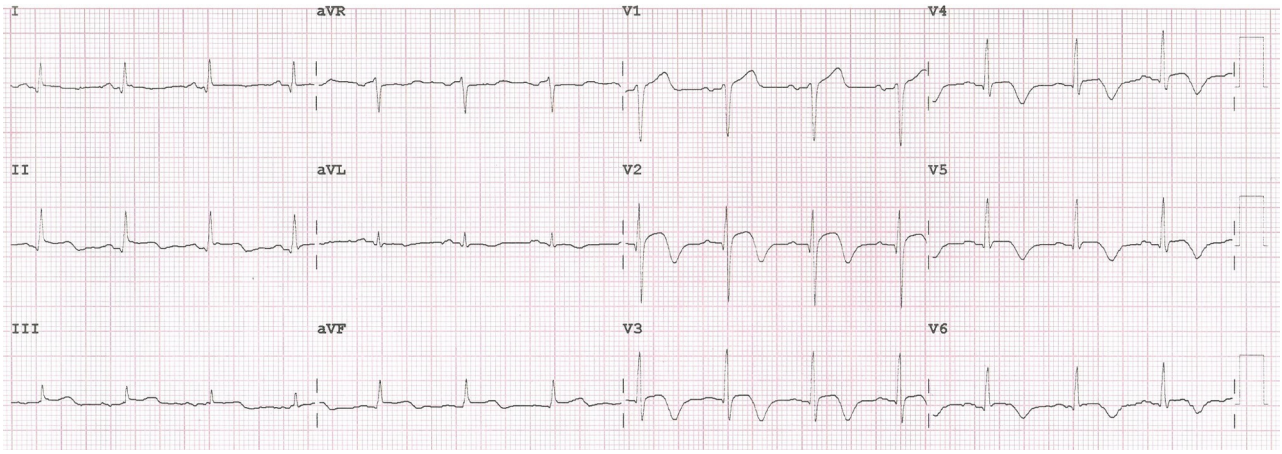

Fig. 1. ECG from admission showing ST elevation in leads V2–V4 and inferior leads and T wave inversion in leads V2–V6.

electrocardiogram revealed ST elevation in leads II, III, aVF and V1–4 with widespread T wave inversion in leads aVL and V2–V6 (Fig. 1). His Troponin-I was elevated at 12.2 ng/mL. The patient underwent emergency invasive coronary angiography with a presumptive diagnosis of an acute ST elevation myocardial infarction. Left and right coronary arteries showed only minor plaque disease. However, left ventriculography showed apical akinesia and ballooning with hypercontractility of the basal segments (Fig. 2A and B). This was confirmed on the subsequent echocardiography (Fig. 2C, Movie I). In the presence of apical dysfunction involving more than one coronary artery territory and the absence of culprit coronary artery disease, a diagnosis of Takotsubo syndrome was made. No obvious emotional or physical precipitator could be identified. The hospital course was uneventful and the patient was discharged on bisoprolol 5 mg/day added to his current medication. CMR was not performed during the acute phase as it was not available in the admitting hospital. The patient was scheduled for an outpatient CMR study following discharge in the regional CMR referral center to exclude a myocardial infarction or myocarditis and to confirm the diagnosis of Takotsubo syndrome.

A CMR study was performed 10 days after initial presentation. Contrary to the typical CMR findings of Takotsubo syndrome, cine images revealed significantly thickened mid to apical left ventricular (LV) segments with preserved contraction and apical systolic cavity obliteration (Fig. 3A–F, Movies II and III). There was no apical ballooning. The cine images were in keeping with apical hypertrophic cardiomyopathy. However, edema sensitive T2 weighted (short tau inversion recovery, STIR) images revealed increased signal in the thickened myocardial segments (Fig. 3G). This involved all mid-apical segments and was not localized to a coronary artery territory. There was also early gadolinium enhancement in keeping with hyperemia associated with edema and inflammation (Fig. 3H). Subtle mid-wall late gadolinium enhancement was observed in the thickened segments (Fig. 3I). When interpreted with the clinical presentation of the patient, the CMR findings suggested a sub-acute phase of Takotsubo syndrome with increased wall thickness due to inflammation and edema. A follow-up CMR examination was performed 5 months after the initial scan. In this study, the previously increased wall thickness had completely normalized and all left ventricular segments demonstrated normal thickness and contractility (Fig. 3J–L, Movie IV). The myocardial T2-STIR signal was normal and there was no late gadolinium enhancement. The normal myocardial findings support recovery following Takotsubo syndrome.

Discussion

Takotsubo syndrome (or stress-induced cardiomyopathy) typically results in presentation with acute chest pain (mimicking acute myocardial infarction) or heart failure, frequently with a history of

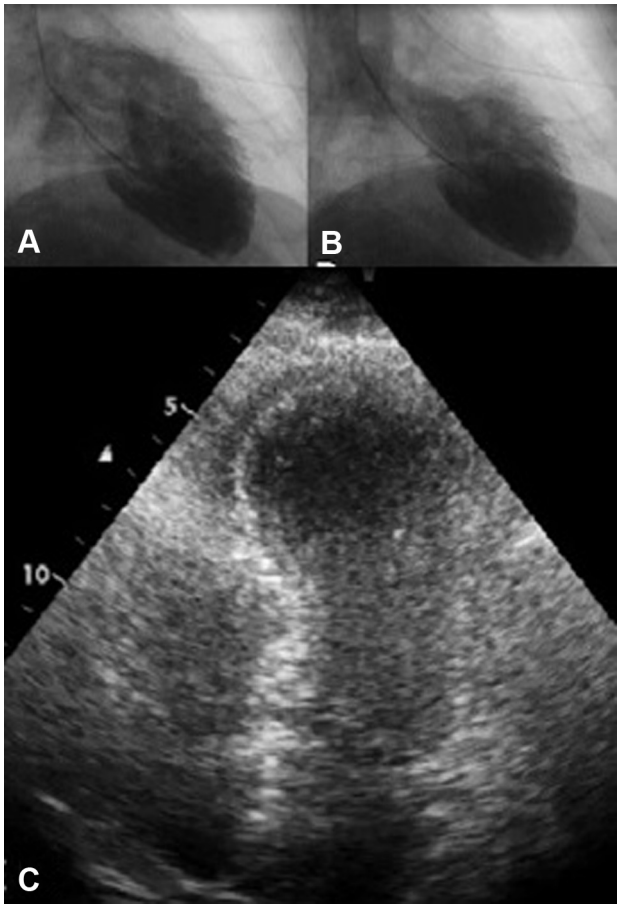

Fig. 2. Left ventriculography and echocardiography images. End diastolic (A) and end-systolic (B) frames of left ventriculography showing apical ballooning and basal hypercontractility in systole. End-systolic frame from the apical four chamber view by echocardiography confirming apical ballooning; there is no increased apical wall thickness in this study which was in the acute phase (C and Movie I).

Download English Version:

https://daneshyari.com/en/article/5869154

Download Persian Version:

https://daneshyari.com/article/5869154

Daneshyari.com