



E-QUID: ANSWER / *Genito-urinary imaging*

Complete androgen sensitivity syndrome[☆]



I. Skiker^{a,*}, S. Nasri^a, S. Maimouni^a, H. Latrech^b,
A. Mimouni^c, A. Brahimi^d

^a Department of Radiology, El Farabi Hospital, FMPO, Mohamed Premier Oujda University, Oujda, Morocco

^b Department of Endocrinology, El Farabi Hospital, Oujda, Morocco

^c Maternity Department, El Farabi Hospital, Oujda, Morocco

^d Radiology Department, Ibn Rochd, Oujda, Morocco

Case report

This was a 30-year-old female patient, the third of six siblings, who had no particular previous history. She had been married for 12 years and consulted because of primary sterility, when the clinical enquiry revealed primary amenorrhea. On clinical examination she was of normal female body morphology, apart from relatively poorly developed axillary and pubic hair growth and on palpation she was found to have two structures in her inguinal folds. Gynecological examination showed the vagina to be patent although with a blind end and no cervix. Her hormone profile showed an FSH of 11.75 mIU/mL, 17-beta estradiol of 10.84 pg/mL and a serum testosterone of 0.190 ng/mL.

Pelvic ultrasound (Fig. 1a–c) with sections through the inguinal structures and a pelvic CT (Fig. 2) and MRI (Fig. 3) were performed.

DOI of original article: <http://dx.doi.org/10.1016/j.diii.2014.04.010>.

[☆] Here is the answer to the case “Primary infertility” previously published. As a reminder we publish again the entire case with the response following.

* Corresponding author at: Boulevard Mohamed VI, rue Dobai, n° 4, Oujda, Morocco.

E-mail address: imanesugar@yahoo.fr (I. Skiker).

<http://dx.doi.org/10.1016/j.diii.2014.04.011>

2211-5684/© 2014 Éditions françaises de radiologie. Published by Elsevier Masson SAS. All rights reserved.

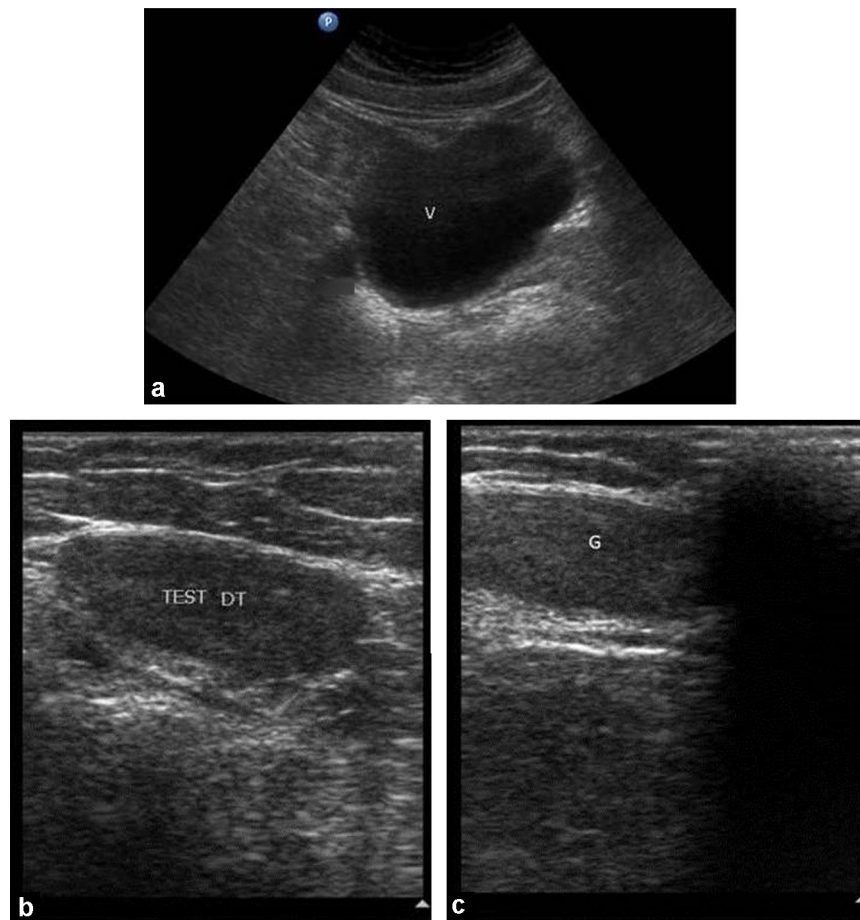


Figure 1. Pelvic ultrasound: sections through the uterine region (a) and through the right (b) and left (c) inguinal structures.

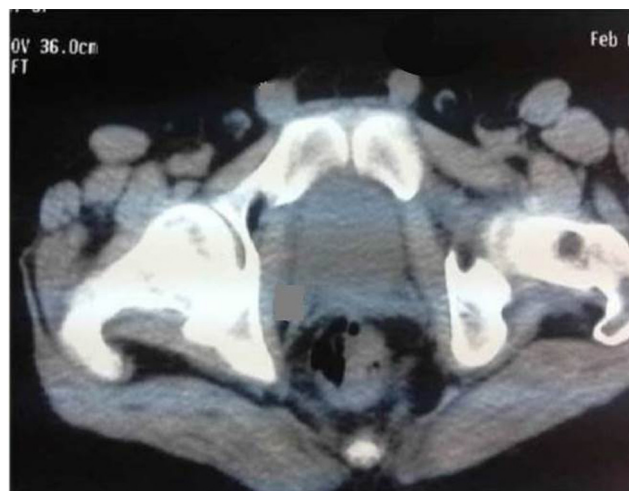

Figure 2. Pelvic CT: axial section through the uterine region and through the two inguinal structures.

Download English Version:

<https://daneshyari.com/en/article/5880262>

Download Persian Version:

<https://daneshyari.com/article/5880262>

[Daneshyari.com](https://daneshyari.com)