

Usefulness of Transesophageal Echocardiography in Guiding Acute Aortic Dissection Management During Open Repair of an Abdominal Aortic Aneurysm



Atsushi Kainuma, MD,* Masayuki Ihara, MD,* Ikuko Miyawaki, MD, PhD,* Hiroyuki Mima, MD,* Tadaaki Koyama, MD, PhD,† and Kazuo Yamazaki, MD*

ACUTE AORTIC DISSECTION (AAD) is a rare and fatal complication that can develop during open repair of an abdominal aortic aneurysm (AAA).¹ Transesophageal echocardiography (TEE) is a helpful tool to detect this rare complication during surgery.¹ In the present report, a case of retrograde Stanford type-A aortic dissection (AD) with severe aortic regurgitation (AR) that developed during emergent open repair of an infrarenal aortic aneurysm is described. It was observed that perioperative TEE was useful for diagnosis and operative decision-making during the management of AD.

CASE REPORT

A 78-year-old woman (height: 1.6 m; weight: 71 kg) with sudden onset of left abdominal pain was diagnosed with an impending AAA rupture and was transferred to this hospital for surgical management.

The patient had no remarkable medical history. Before surgery, her vital signs were blood pressure, 89/67 mmHg; heart rate, 104 beats per minute; respiratory rate, 34 breaths per minute; and oxygen saturation, 98% in room air.

Blood tests indicated a hemoglobin level of 7.4 g/dL, normal renal function, and absence of any coagulation disorders. Electrocardiography indicated a normal sinus rhythm with no evidence of ischemia. Transthoracic echocardiography (TTE) showed normal left ventricular function (ejection fraction >50%) and no obvious valvular disease. A contrast-enhanced computed tomographic (CT) scan confirmed the presence of a 60-mm ruptured infrarenal AAA. A contrast-enhanced CT scan of the entire aorta found no evidence of dissection, intramural hematoma, or penetrative ulcers along the entire length of the ascending aorta.

After the placement of peripheral intravenous and arterial catheters, the patient was transferred to the operating room for surgical repair of the AAA. Anesthesia was induced, uneventfully, with 250 µg of fentanyl, 2 mg of midazolam, and 100 mg of rocuronium. She was intubated with a 7.0-mm endotracheal tube and received inhaled sevoflurane as maintenance anesthesia. Thereafter, a central venous catheter was inserted through the right internal jugular vein.

After her abdomen was opened, the hemorrhage from the aneurysm became uncontrollable. She suffered cardiopulmonary arrest (CPA) due to hemorrhagic shock. Therefore, a left anterolateral incision was made, and the cardiothoracic surgeon initiated cardiac massage. Moreover, the descending aorta was clamped through the incision. Thus, cardiopulmonary resuscitation was attempted, and spontaneous circulation returned after approximately 24 min; hence, the surgery was resumed. Her activated coagulation time (ACT) was 340 seconds without heparin administration; therefore, heparin was not administered during the surgery.

The infrarenal abdominal aorta and left and right common iliac arteries were identified and clamped. Thereafter, the patient underwent infrarenal abdominal aorta replacement with

an I-graft (20 × 11 mm; Hemashield Gold, MAQUET, San Jose, CA). After the proximal aortic site was unclamped, the patient's blood pressure suddenly fell. Although appropriate medical and fluid therapies were administered, her vital signs remained unstable. Consequently, a TEE probe was inserted, which indicated the presence of an AAD extending along the aorta proximally from the aortic arch to the descending aorta. At that time, the dissection was limited to the aortic arch on the proximal side. After the distal site was unclamped, the patient suffered another CPA due to hypovolemic shock and required blood volume infusion and cardiac massage. She recovered quickly and underwent another TEE examination thereafter. TEE indicated that the dissection extended to the ascending aorta—which was suggestive of a retrograde type-A AD (Fig 1)—and showed the presence of moderate-to-severe AR, the absence of any apparent pericardial effusion, and the absence of any abnormal cardiac wall motion or coronary involvement. Within the visual field of the TEE, no entry site of the dissection was observed. After discussing the management of this patient with the cardiothoracic surgeons, conservative treatment was adopted for treating the dissection.

After I-graft replacement for the AAA was completed, the patient was transferred to the intensive care unit (ICU) with an open abdomen and was intubated. She received an infusion of 0.1 µg/kg/min of norepinephrine and 0.7 µg/kg/min of epinephrine. The total amount of bleeding due to surgery was 1,074 mL, whereas 7,070 mL of blood were collected in the cell saver canister (Sorin Group, Milan, Italy). The patient required 34 U of packed red cells, 32 U of fresh frozen plasma, and 30 U of platelet concentrates to resolve the loss caused by hemorrhage during the surgery. Finally, her ACT was found to be 191 seconds without heparin administration.

In the ICU, the patient's urine output was >50 mL/hour, intravesical pressure was <15 mmHg, and no metabolic acidosis was detected. Her cardiac function was assessed using TTE, but AD could not be evaluated due to a poor viewing field, even though the examination was performed by a cardiologist. An abdominal wall closure procedure was planned 3 days after the initial surgery. It was planned to use TEE to evaluate AD. During the surgery, a TEE probe was inserted,

*From the Departments of *Anesthesiology and Critical Care; and †Cardiovascular Surgery, Kobe City Medical Center General Hospital, Kobe, Japan.*

Address reprint requests to Atsushi Kainuma, MD, Department of Anesthesiology and Critical Care, Kobe City Medical Center General Hospital, 2-1-1, Minatojima-minamimachi, Chuo-ku, Kobe, 650-0047, Japan. E-mail: atsu.va.mola@gmail.com

© 2016 The Authors. Published by Elsevier Inc. All rights reserved. 1053-0770/2602-0033\$36.00/0

<http://dx.doi.org/10.1053/j.jvca.2015.07.027>

Key words: perioperative transesophageal echocardiography, acute aortic dissection, abdominal aortic aneurysm

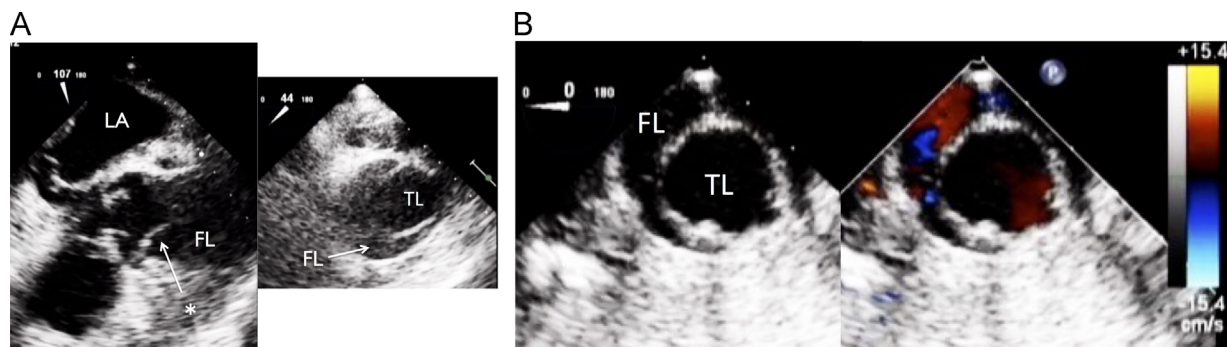


Fig 1. (A) Perioperative transesophageal echocardiograph indicating a Stanford type-A aortic dissection in the midesophageal long-axis view and ascending aortic short-axis view. The asterisk (*) indicates the dissection flap. (B) Perioperative transesophageal echocardiograph indicating a descending aortic dissection in the descending aortic short-axis view. Abbreviations: LA, left atrium; TL, true lumen; FL, false lumen.

which indicated the presence of a type-A AD with a thrombosed false lumen (FL), and without any AR (Fig 2). She did not need any further intervention for AD. Moreover, the vacuum-pack technique was used for abdominal wall closure.

Tracheostomy was performed 10 days after the initial surgery, and closure of the patient's abdominal fascia was performed 16 days after the initial surgery. At 22 days after the initial surgery, her general condition sufficiently recovered so that she could undergo contrast-enhanced CT for the first time since the initial surgery. Contrast-enhanced CT indicated that the AAD noted perioperatively was thrombosed completely and that the thrombosed FL already had disappeared (Fig 3). She was moved to the general ward 95 days after the initial surgery; at that time, she showed clear consciousness and did not require any inotropic support.

DISCUSSION

When operated by experienced physicians, the diagnostic ability of TEE for thoracic AD is high, similar to that of CT and magnetic resonance imaging.² The salient features of using TEE relative to the other modalities are as follows: it easily can be

performed in the operating room or at the bedside; it enables the visualization of blood flow, which can help diagnose malperfusion and the presence of a false or true lumen;²⁻⁵ and it enables the detection of ongoing AD, such as in the present case. This case report highlights the fact that perioperative TEE can be helpful for diagnosing a rare complication during AAA surgery and for deciding the appropriate management for type-A AD in this rare clinical course.

In a retrospective review of 4,347 patients who underwent open AAA repair surgery, acute type-A AD was observed intraoperatively in only 1 patient who required immediate surgical intervention.⁶ With regard to type-A and type-B AD, only the present case and 4 other cases have reported the occurrence of AAD during and after the AAA surgery.^{1,6-8} In the present patient and 2 previous patients, AAD occurred upon aortic declamping.^{1,6} In 2 other patients, AAD occurred on arrival in the recovery room or 15 days after the AAA surgery.^{7,8} Several studies have reported the occurrence of sudden onset of hypotension or volume loss of unknown origin and anuria immediately after elective repair of AAA, as symptoms of AD.^{1,7} Perioperative TEE and angiography were

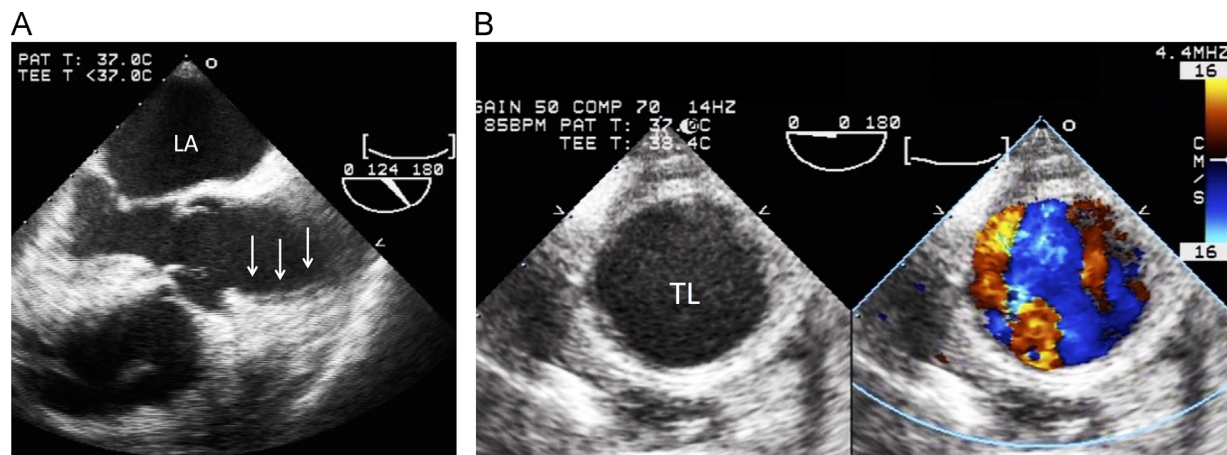


Fig 2. (A) At the second surgery, performed 3 days after the initial surgery, perioperative transesophageal echocardiography indicated a Stanford type-A aortic dissection with a thrombosed false lumen (delineated by arrows), and without any aortic regurgitation, in the midesophageal long-axis view. (B) At the second surgery, performed 3 days after the initial surgery, perioperative transesophageal echocardiography indicated an aortic dissection with a thrombosed false lumen in the descending aortic short-axis view. Abbreviations: LA, left atrium; TL, true lumen.

Download English Version:

<https://daneshyari.com/en/article/5883649>

Download Persian Version:

<https://daneshyari.com/article/5883649>

[Daneshyari.com](https://daneshyari.com)