Bone 57 (2013) 484–492

Contents lists available at ScienceDirect

Bone

journal homepage: www.elsevier.com/locate/bone

Original Full Length Article

Induced periosteum a complex cellular scaffold for the treatment of large bone defects

Richard J. Cuthbert [a,c], Sarah M. Churchman [a,c], Hiang B. Tan [b,c], Dennis McGonagle [a,c], Elena Jones [a,c], Peter V. Giannoudis [a,c,*]

[a] Leeds Institute of Rheumatic and Musculoskeletal Medicine, University of Leeds, LS9 7TF, UK
[b] Department of Trauma and Orthopaedics, Academic Unit, Clarendon Wing, Leeds Teaching Hospitals NHS Trust, Great George Street, Leeds LS1 3EX, UK
[c] Leeds NIHR Biomedical Research Unit, Leeds Institute of Molecular Medicine, Beckett Street, Leeds, LS9 7TF, UK

ARTICLE INFO

Article history:
Received 28 May 2013
Revised 2 August 2013
Accepted 9 August 2013
Available online 15 August 2013

Edited by: J. Aubin

Keywords:
Induced-periosteum
Induced membrane
Bone regeneration
Osteoprogenitor cells
MSC

ABSTRACT

Objective: Surgically induced periosteal membrane holds great potential for the treatment of large bone defects representing a simple alternative to combinations of exogenous stem cells, scaffolds and growth factors. The purpose of this study was to explore the biological basis for this novel regenerative medicine strategy in man.
Methods: Eight patients with critical size defects were treated with the induced membrane (IM) technique. After membrane formation 1 cm^2 biopsy was taken together with matched, healthy diaphyseal periosteum (P) for comparative analysis. Morphological characteristics, cell composition and growth factor expression were compared. Functional and molecular evaluation of mesenchymal stromal cell (MSC) activity was performed.
Results: Both tissues shared similar morphology although IM was significantly thicker than P ($p = 0.032$). The frequency of lymphocytes, pericytes ($CD45^-CD34^-CD146^+$) and cells expressing markers consistent with bone marrow MSCs ($CD45^{-/low}CD271^{bright}$) were 31. 3 and 15.5-fold higher respectively in IM (all $p = 0.043$). IM contained 3-fold more cells per gramme of tissue with a similar proportion of endothelial cells ($CD45^-CD31^+$). Expressed bone morphogenic protein 2, vascular endothelial growth factor and stromal derived factor 1 (SDF-1) are key tissue regeneration mediators. Adherent expanded cells from both tissues had molecular profiles similar to bone marrow MSCs but cells from IM expressed greater than 2 fold relative abundance of SDF-1transcript compared to P ($p = 0.043$).
Conclusion: The IM is a thick, vascularised structure that resembles periosteum with a cellular composition and molecular profile facilitating large defect repair and therefore may be described as an "induced-periosteum". This tissue offers a powerful example of in situ tissue engineering.

Introduction

Bone regeneration for the treatment of large bone defects is challenging and several factors are thought to affect treatment outcome, including the location and length of the defect, the condition of the soft tissue envelope, the mechanical environment, as well as patient related factors such as age, metabolic and systemic disorders and related co-morbidities [1–3]. For small bone defects with healthy surrounding soft tissues, the bone gap can usually be bridged with conventional cancellous bone grafting or bone substitutes [4]. However, when the defect exceeds a 'critical size' more specialised treatment modalities are essential to augment tissue repair [5]. Indeed the treatment of large size defects represents a substantial challenge and many consider that elaborate tissue engineering strategies including the use of exogenous stem cells, growth factors and bioactive scaffolds will be required [6].

Recently the novel concept of Guided Bone Regeneration with the use of bioactive induced membranes, pioneered by Masquelet et al. has received attention [7,8]. When a cement spacer is placed in critical sized defects a biological membrane is induced around it. At a later date the cement is removed with the induced membrane (IM) serving as a conduit to contain cells or bone graft [9]. Animal studies have shown the IM to have osteogenic, osteoinductive and angiogenic properties [10,11], but to date there have been no studies addressing the functional properties and characteristics of the IM in a clinical setting.

The periosteum is widely recognised to be of critical importance in bone formation and regeneration [12–14]. Structurally it is divided into two distinct layers an outer fibrous layer and a inner cambium layer [15,16], this has been shown to be a reservoir of progenitor cells with an osteogenic potential comparable to bone marrow derived mesenchymal stromal cells (BM-MSCs) and superior to synovial MSCs [12,17–19]. The periosteum is highly vascularised, provides the cortical blood supply [15,16,18] and has been demonstrated to be an important factor in healing long bone fractures [20,21]. The anatomical location of IM in relation to the cement spacer implant closely resembles that of the diaphyseal periosteum in relation to underlying bone, suggesting that these tissues may be analogous.

The purpose of this study was to investigate the morphology, molecular properties and gene expression patterns of the IM harvested

* Corresponding author at: Leeds Institute of Rheumatic and Musculoskeletal Medicine, University of Leeds, LS9 7TF, UK.
E-mail address: pgiannoudi@aol.com (P.V. Giannoudis).

8756-3282/$ – see front matter © 2013 Elsevier Inc. All rights reserved.
http://dx.doi.org/10.1016/j.bone.2013.08.009

from a series of patients undergoing reconstruction for the treatment of large diaphyseal bone defects. The tissue architecture and location of cell types were compared to normal diaphyseal periosteum in order to identify any characteristics of the IM that may facilitate bone regeneration. Of particular interest was whether IMs were enriched for MSCs; highly proliferative multipotential cells that can form bone, cartilage and other stromal lineages [22]. The presence of pericytes was also investigated, a cell type known to share many proliferative and differentiation characteristics with MSCs [23], as well as being important contributors to blood vessel maturation [24]. The distribution of molecules critical to bone repair and vascularisation including bone morphogenic protein—(BMP) 2, vascular endothelial growth factor (VEGF) and stromal derived factor 1 (SDF-1) expression was also investigated.

Our aim was to investigate if a comparatively simple surgical technique was associated with the generation of a periosteum like structure, containing MSCs and molecules needed for bone repair. This would support the concept that the skeleton has remarkable intrinsic repair capabilities that may not necessarily depend on elaborate and expensive tissue engineering strategies for optimal repair.

Patients and methods

Inclusion criteria

Patients admitted to our institution for treatment of either the upper or the lower extremity with bone loss (critical size bone defect) using the IM technique were invited to participate in this study; all patients gave informed consent and research was carried out in compliance with the Helsinki Declaration. Ethics committee approval was obtained from the local National Health Service Research & Development Department, National Research Ethics Service, Leeds East Research Ethics Committee for the harvesting of these tissues. Patients that underwent treatment of bone defects by other methods of bone regeneration (i.e. distraction osteogenesis, allograft implantation following tumour excision) were excluded.

Patient characteristics

Eight patients (7 male) with a mean age of 60 years (range 18–80) were recruited to this study. All defects were of post-traumatic nature. The distribution of the anatomical site of the defect is shown in Table 1. The mean size of the defect was 36.25 mm (range 25–50 mm). Six cases (numbers 1, 2, 3, 4, 6, 7) were infected non-unions whereas 2 cases (numbers 5, 8) were aseptic non-unions. The most common bacteria isolated from the infected cases were coagulase negative *Staphylococcus*. The mean number of operations performed prior to the first stage of the IM technique was 1.5 (1–3). In all cases after the debridement of the non-union site and the implantation of the cement spacer, the fractures were stabilised with external fixators. Subsequently, during the second stage, all external fixators were removed and the fractures were stabilised with either intramedullary nailing (case 1) or locked plating (cases 2–8) (Table 1). All patients progressed to osseous healing of the defect at a mean time of 6.2 months (range 3–9).

Table 1
Patient demographics.

Patient	Sex	Age	Size of defect	Location of defect
1	M	46	45 mm	Femur
2	M	72	40 mm	Femur
3	M	64	40 mm	Tibia
4	M	66	25 mm	Radius
5	M	27	25 mm	Radius
6	M	18	25 mm	Ulna
7	F	80	40 mm	Femur
8	M	72	50 mm	Radius

Table shows patient sex, age at time of procedure (second stage), the size of the defect and its anatomical location.

Induced membrane technique and tissue harvesting

Following adequate debridement of the affected limb a polymethyl methacrylate cement spacer (Heraeus Medical GmbH, Wehrheim, Germany) was implanted and the affected limb temporarily stabilised with an external fixator as previously described [9]. The cement spacer was removed six to eight weeks later by incising the IM. During the removal of the cement spacer (second stage of the IM procedure), an area of at least of 1 cm^2 IM tissue was harvested at the centre of the bone loss area (Fig. 1). IM was harvested from tibia radius and ulna on the side opposite to the muscle layer and in femur defects IM was harvested adjacent to the muscle layer. Subsequently, with careful dissection at least 10 cm proximally from the area of the bone defect, a periosteum layer from the normal diaphyseal bone was prepared and 1 cm^2 of tissue was harvested. The procedure then proceeded as previously described [9].

Tissue processing

Tissue samples were bisected; 50% of each sample was retained for histological processing and the remaining was weighed and subjected to collagenase digestion to produce a single cell suspension. For digestion, samples were incubated in 600 U/ml collagenase (Worthington Biochemical Corp., Lakewood, NJ, USA) solution, 20% foetal calf serum (PAA laboratories, Yeovil, Summerset, UK) in phosphate buffered saline at 37 °C for 4 h with constant agitation. Following incubation, cell suspensions were passed through a 70 μm filter to remove large debris and cells were concentrated by centrifugation prior to analysis by flow cytometry or cryopreserved.

Histology and immunohistochemistry

Histology and immunohistochemistry were carried out on paraformaldehyde-fixed histological tissue sections of matched IM and periosteum (n = 8). Haematoxylin and eosin staining was performed according to standard protocols. Immunohistochemistry staining was performed using REAL peroxidise/DAB + detection system (Dako, Stockport, UK) and specific mouse and rabbit primary antibodies (Table 2). Paraffin-embedded tissue sections (4 μm thick) were de-waxed in xylene and rehydrated through a graded alcohol series to water. Endogenous peroxidase activity was quenched by incubation with hydrogen peroxide solution and antigen retrieval was

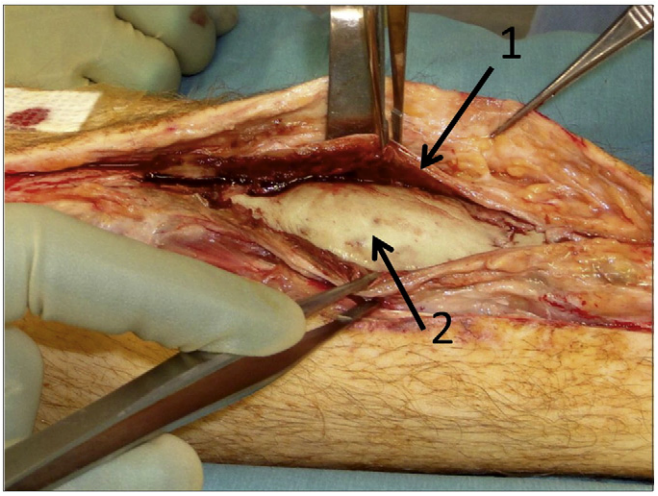

Fig. 1. Intraoperative picture illustrating the induced membrane. Induced membrane (1) separated and elevated off the cement spacer (2) of patient number 3 (tibial defect).