

Successful Healing of Tracheal Radionecrosis

Role of Hyperbaric Oxygen Therapy



Miguel Ariza-Prota, MD; Arturo Morales, MD; Jose Grajeda, MD; Rosa López-Lisbona, MD; Noelia Cubero, PhD; Jordi Dorca, PhD; and Antoni Rosell, PhD

Hyperbaric oxygen therapy, the administration of 100% oxygen at pressures > 1 atm, is believed to promote wound healing by increasing angiogenesis and collagen synthesis. To our knowledge, this treatment modality has never been described in patients with tracheal radionecrosis. Here, we report the case of a 55-year-old man diagnosed with stage IIIB lung adenocarcinoma who was treated with chemotherapy and concomitant external intensity-modulated radiotherapy involving the left lung and mediastinum. Nine months later, he presented with neck pain, cough with mucopurulent sputum, and fever. A PET-CT scan revealed a fissure in the posterior wall of the left upper trachea. Flexible bronchoscopy showed a tracheal ulceration with a small left posterior wall fissure that extended into the mediastinum. To our knowledge, this is the first report in the literature that suggests that treatment with hyperbaric oxygen therapy, local debridement, and antibiotics is a feasible and successful management option for patients with complicated tracheal radionecrosis. CHEST 2016; 150(6):e147-e150

KEY WORDS: bacterial infection; bronchoscopy; hyperbaric oxygen therapy; radiotherapy; tracheal radionecrosis

Acute or late lung toxicity after chest irradiation can occur in patients with lung cancer.¹ Late toxicity associated with radiotherapy features vascular damage, atrophy, and fibrosis. The vascular damage can cause, among others complications, small vessel constriction, which may manifest as ischemia and necrosis.² As a rare complication of larynx radiation, cartilage radionecrosis has been reported²⁻⁶ and may present together with fistula and infection. In these laryngeal complications, hyperbaric oxygen therapy (HBOT) has demonstrated to be effective and avoids the need for tracheostomy or laryngectomy.^{7,8} Here, we

present a case of an infected tracheal radionecrosis successfully treated with a triple modal therapy, including antibiotics, local debridement, and HBOT.

Case Report

A 55-year-old man, former smoker, diagnosed with stage IIIB (cT1aN3M0) adenocarcinoma of the lung, was treated with chemotherapy and concomitant external intensity-modulated radiotherapy with 66 Gy, involving the left lung and mediastinum, because no specific mutations were found. He achieved a complete response assessed by PET-CT scan, but he

ABBREVIATIONS: HBOT = hyperbaric oxygen therapy

AFFILIATIONS: From the Servei de Pneumologia (Drs Ariza-Prota, Grajeda, López-Lisbona, Cubero, Dorca, and Rosell), Hospital Universitari de Bellvitge-IDIBELL and the Facultat de Medicina, Departament de Ciències clíniques (Drs Dorca and Rosell), Universitat de Barcelona, Barcelona, Spain; and the Departamento de Enfermedades Respiratorias (Dr Morales), Facultad de Medicina, Pontificia Universidad, Católica de Chile, Santiago, Chile.

CORRESPONDENCE TO: Antoni Rosell, PhD, Feixa Llarga s/n. 08907 L'Hospitalet de Llobregat, Barcelona, Spain; e-mail: arosell@bellvitge-hospital.cat

Copyright © 2016 American College of Chest Physicians. Published by Elsevier Inc. All rights reserved.

DOI: <http://dx.doi.org/10.1016/j.chest.2016.03.027>

developed mild actinic pneumonitis and esophagitis, which resolved spontaneously. Nine months later he was referred to the hospital because of neck pain, coughing with mucopurulent sputum, and low-grade fever. PET-CT scan revealed a fissure in the posterior wall of the left upper trachea, at the level of vertebrae T1-2, with a slight increase in metabolic activity (maximum standardized uptake value = 3.2) (Fig 1A). Cancer recurrence was suspected, and stent placement was initially proposed. Bronchoscopy showed a right anterolateral tracheal ulceration, extending to the right posterior wall, together with a small left posterior wall fissure that extended into the mediastinum. The lesion occupied 75% of the tracheal ring. Both lesions were covered by mucopurulent secretions (Fig 1B). Biopsies of both sites were negative for tumor recurrence, and stent placement was not thought to be indicated. Suspecting that tracheal radionecrosis was the underlying cause, with superimposed infection, the patient was started on triple modal therapy. This consisted of antibiotics, local debridement, and HBOT, plus saline solution (0.9%) nebulizations through a supersonic nebulizer. Bronchoscopic protected specimen brush sample retrieved cultures positive for multisensitive *Staphylococcus aureus* and *Parvimonas micra* sensitive to penicillin. He received 6 weeks of oral cloxacillin 500 mg 4 times a day. Concomitant with antibiotics, 9 sessions of local debridement with a cytology bronchial brush were performed at monthly intervals. The patient received 40 sessions of HBOT of 60 min each at 2 atmosphere absolute, in a multiplace chamber with good tolerance, at a twice per week schedule. In serial monthly interval bronchoscopies, a

progressive healing of lesions was witnessed (Fig 2A-E). A control PET-CT scan, performed after 9 months of multimodal treatment, showed complete resolution of the fissure in the left posterior tracheal wall (Fig 1B). The last flexible bronchoscopy showed total resolution of the ulcerative lesion with complete tracheal re-epithelization and mild cicatricial tracheal stenosis that did not require treatment (Fig 2F). One year after the end of treatment, the patient continues to be asymptomatic, with no evidence of tumor recurrence.

Discussion

Cartilage necrosis has been described as a late complication of radiotherapy toxicity.^{2,4-6} Mehta and Dweik⁹ reported 4 patients with total bronchial necrosis after radiation therapy for squamous cell carcinoma of the lung. They concluded that radiation is a major culprit in bronchial necrosis, and it is likely that the presence of all 3 entities (external radiotherapy, infection, and bronchogenic carcinoma) synergistically produce necrosis. Patients were treated with antibiotics and laser to the bleeding areas. The mortality rate was 100% within 3 months.⁹ An additional case of radiation-induced bronchial necrosis has also been reported.¹⁰ Here, we report this case of tracheal radionecrosis and concomitant infection, which was successfully treated with a multimodal approach of directed antibiotics, debridement, and HBOT, similar to the management of diabetic foot and skin ulcers.¹¹

A systematic review concluded that, for patients with late radiation tissue injury affecting tissues of the head,

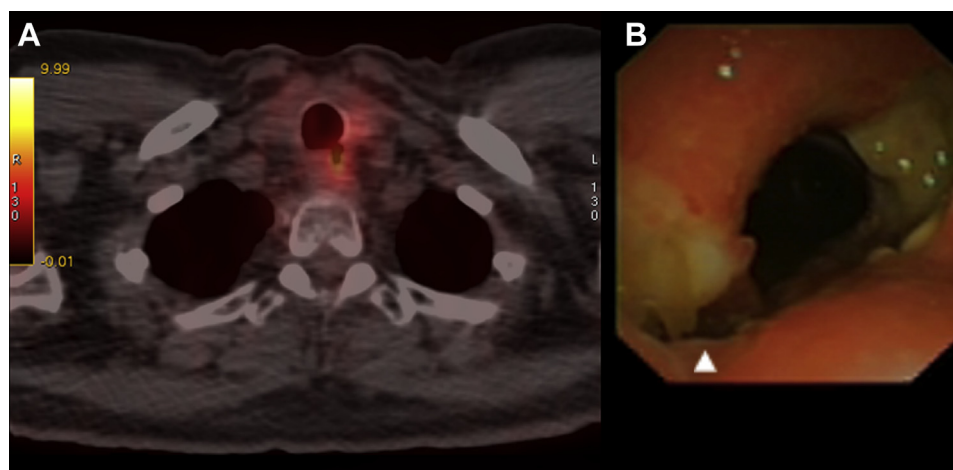


Figure 1 – A, PET-CT scan of the chest showing a diverticulum nearly fistulizing into the mediastinum in the left posterior wall of the upper trachea with slightly increased metabolic activity. B, Tracheal view showing a left posterior wall diverticulum (white arrowhead) and a right anterolateral wall tracheal ulceration covered by purulent secretions before treatment.

Download English Version:

<https://daneshyari.com/en/article/5952129>

Download Persian Version:

<https://daneshyari.com/article/5952129>

[Daneshyari.com](https://daneshyari.com)