



Case Report

Ventricular pacing inhibition by oversensing due to diaphragmatic myopotential during deep inspiration

Yasutsugu Nagamoto (MD, PhD)*, Tetsuya Shiomi (MD, PhD), Taku Matsuura (MD), Arihide Okahara (MD), Kota Inoue (MD), Rika Yamaguchi (MD), Kaoru Takegami (MD), Daigo Mine (MD), Takaharu Shirahama (MD), Yasuaki Koga (MD, PhD), Keiki Yoshida (MD), Kenji Sadamatsu (MD, PhD), Kiyoshi Hayashida (MD, PhD)

Division of Cardiology, Saga Prefectural Hospital Koseikan, 1-12-9 Mizugae, Saga 840-8571, Japan

ARTICLE INFO

Article history:

Received 22 January 2013

Received in revised form 17 April 2013

Accepted 25 April 2013

Keywords:

Pacemaker inhibition

Oversensing

Diaphragmatic myopotential

ABSTRACT

An 80-year-old man, who had dilated cardiomyopathy with right ventricular (RV) dilatation, underwent implantable cardioverter defibrillator (ICD) implantation for advanced atrioventricular block and primary prevention of sudden cardiac death. Tined and screw-in leads were placed on the right atrial appendage and RV apex, respectively. Ventricular pacing inhibition was detected after surgery due to oversensing by diaphragmatic myopotential occurring only during deep inspiration. We performed re-surgery and switched the screw-in lead for a tined lead. The diaphragmatic myopotential decreased, thereby improving oversensing by diaphragmatic myopotential and ventricular pacing inhibition. It might be beneficial to use a tined lead when placing the ventricular lead at the RV apex for implantation of a pacemaker or ICD if oversensing of diaphragmatic myopotential is observed using a screw-in lead.

<Learning objective: Oversensing due to diaphragmatic myopotential is rarely observed. However if it occurs, it becomes a critical problem, which causes pacemaker inhibition or inappropriate ICD shock. However, the method of preventing this problem is unknown. In this case, we demonstrated that a tined-lead may be useful for the prevention of oversensing by diaphragmatic myopotential.>

© 2013 Japanese College of Cardiology. Published by Elsevier Ltd. All rights reserved.

Introduction

Oversensing, a well-acknowledged complication of a pacemaker or implantable cardioverter defibrillator (ICD), may arise because of electromagnetic interference, lead fractures, insulation breaks, and P or T waves [1]. We describe a case of ventricular pacing inhibition by oversensing due to diaphragmatic myopotential during deep inspiration in a patient with an ICD, which was improved by changing the lead type.

Case report

An 80-year-old man with dilated cardiomyopathy was admitted to our hospital because of syncope. Electrocardiography (ECG) showed an advanced atrioventricular block with 3 to 1

conduction and nonsustained ventricular tachycardia (VT). Ultrasound echocardiography (UCG) revealed left ventricular (LV) dysfunction (ejection fraction, 16%), right ventricular (RV) and LV dilatation (RV, LV diastolic dimension, 58 mm and 78 mm, respectively). A pacing device was indicated for the advanced atrioventricular block; therefore, we chose to implant an ICD (St. Jude Fortify 2235-40; St. Paul, MN, USA) for primary prevention of sudden cardiac death based on the patient's laboratory findings, which showed dilated cardiomyopathy with severe LV dysfunction and nonsustained VT. Severe LV dysfunction might indicate the implantation for cardiac resynchronization therapy (CRT)-D, not ICD, because cardiac function tends to deteriorate by pacing from the RV apex. However, the patient had no history of heart failure. Moreover the patient had impaired renal dysfunction (creatinine level, 2.48 mg/dl). Contrast dye is required for coronary sinus venography when inserting an LV lead, which may pose a risk for contrast nephropathy. Therefore, we decided to implant an ICD, and planned a strategy to upgrade from the ICD to CRT-D, in case the patient experienced heart failure in the future.

* Corresponding author. Tel.: +81 952 24 2171; fax: +81 952 29 9390.

E-mail address: sqopacificsouthern1978@yahoo.co.jp (Y. Nagamoto).

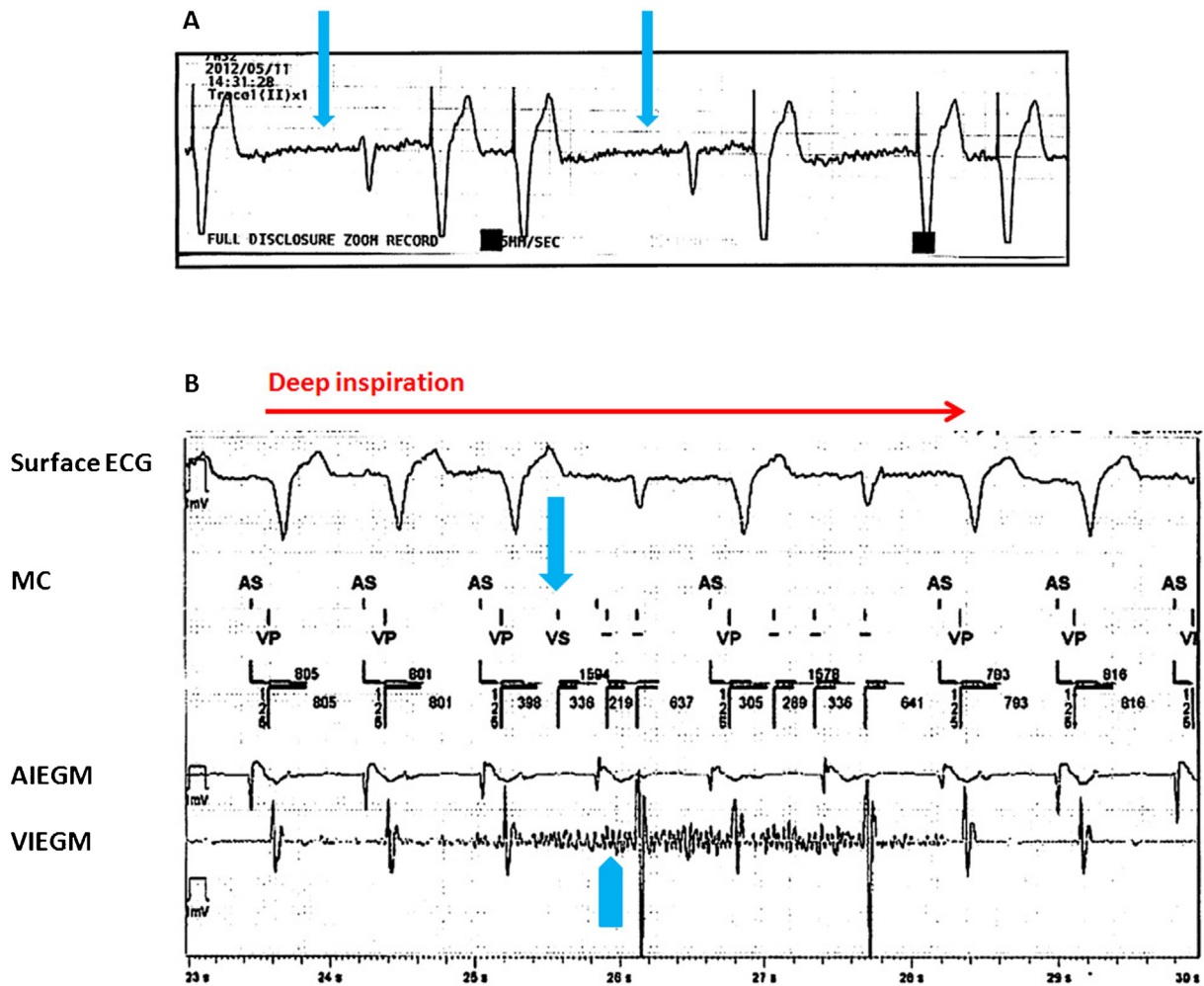


Fig. 1. (A) Electrocardiogram (ECG) monitoring revealed ventricular pacing inhibition (arrow) 7 days after implantable cardioverter defibrillator implantation. (B) Oversensing (arrow) with the right ventricular screw-in lead due to diaphragmatic myopotential (arrowhead) during deep inspiration. AIEGM, atrial intracardiac electrogram; MC, maker channel; VIEGM, ventricular intracardiac electrogram.

Tined (St. Jude, 1944/52 cm) and screw-in leads (St. Jude, 7120Q/58 cm) were placed on the right atrial appendage and RV apex, respectively. Ventricular pacing inhibition was detected 7 days after surgery (Fig. 1A). Chest X-ray and UCG did not reveal any lead dislodgement or pericardial effusion caused by lead perforation. ICD assessment revealed no abnormality of lead impedance, sensing or output threshold; however, oversensing by diaphragmatic myopotential occurred only during deep inspiration (Fig. 1B), causing ventricular pacing inhibition. We performed re-surgery without changing the ICD setting. Many locations were explored to find an optimal site for the RV lead without diaphragmatic myopotential. First, a low pacing threshold and an absence of diaphragmatic myopotential was observed in the RV septum, but ventricular amplitude was low (<2.0 mV); thus, we decided against placing the RV lead at the RV septum. Therefore, we carefully explored the RV apex, which had a low pacing threshold and high ventricular amplitude. However, diaphragmatic myopotential was observed during deep inspiration. Fig. 2A illustrates a representative intracardiac ECG showing diaphragmatic myopotential during deep inspiration at re-surgery using a screw-in lead, which was placed at a different location at the RV apex from that during the first surgery. We considered that the shorter distance

between the lead-end, which included a screw, and the diaphragm might cause diaphragmatic myopotential due to an enlarged RV. Therefore, we switched the screw-in lead for tined lead (St. Jude, 7170Q/58 cm), which was placed at virtually the same location as that during the first surgery (Fig. 3A and B). The diaphragmatic myopotential decreased, thereby improving ventricular pacing inhibition (Fig. 2B) during the re-surgery and follow-up period.

Discussion

The first report about oversensing of muscle potentials associated with inspiration refers to a VVI pacemaker with a unipolar ventricular lead [2], but oversensing of diaphragmatic myopotential has also been described with a bipolar lead [3]. Oversensing the detection of diaphragmatic myopotential has been reported to cause pacemaker inhibition [2,3] and inappropriate ICD shocks [1,4]. Schulte et al. [5] reported an incidence of inappropriate arrhythmia detection due to diaphragmatic myopotential oversensing of 8.6%, and an inappropriate shock incidence of 3% in a general population with ICD implantations.

Download English Version:

<https://daneshyari.com/en/article/5984867>

Download Persian Version:

<https://daneshyari.com/article/5984867>

[Daneshyari.com](https://daneshyari.com)