

Novel sutureless mitral valve implantation method involving a bayonet insertion and release mechanism: A proof of concept study in pigs

Duc-Thang Vu, MD,^a Lian Kah Ti, MD,^b Lay Choo Ong, BEng, MSc,^c Poh Hock Neo, BEng, MSc,^c Chuen Neng Lee, MD,^a and Theo Kofidis, MD,^a Singapore, Republic of Singapore

Despite the development of mitral valve repair and percutaneous mitral procedures, mitral valve replacement (MVR) is still the first option for 62% and 43.2% to 61% of patients with mitral regurgitation and mitral stenosis, respectively.¹ The implantation of a mitral valve prosthesis, however, still involves the time-consuming work of suturing a mitral prosthesis to the mitral annulus. Furthermore, en bloc removal of the degenerated prosthesis, old sutures, and pledgets during reoperative MVR carries the risks of embolism and of injury to the already perforated mitral annulus and relevant structures.

The objectives of the this proof of concept large animal study were to develop a new type of mitral valve implantation mechanism and to prove that the novel technique would remarkably reduce operative and cardiac arrest times, simplifying MVR with comparable efficacy and safety.

MATERIALS AND METHODS

Novel Sutureless Mitral Valve

The novel sutureless mitral valve (Figure 1) is a 2-component device; a hinge ring and the modified prosthetic mitral valve (PMV). The prototypes were fabricated in collaboration with the Biomedical Engineering Group, Nanyang Polytechnic, Singapore, a non-valve-focused facility. All parts were manufactured with rapid-prototyping material (Accura Si 50; 3D Systems, Inc, Rock Hill, SC).

The hinge ring. This external hinge ring is designed for permanent anchoring to the mitral annulus and functions as the hinge mechanism.

The PMV. The PMV portion could be compatible with any commercially available mitral prosthesis, with the fabric suture ring removed and 2 new indentations added on the outer side of the valve housing ring to engage with the prominences on the hinge ring. In this study, we produced a prototype that mimicked a size 27 conventional mitral bileaflet disk prosthesis.

Animal Model

Fourteen female Yorkshire pigs, weighing 55 to 75 kg, were divided into control (n = 6) and prototype (n = 8) groups. Animals in the control group received a size 27 conventional mitral valve prosthesis, whereas the ones in the study group received our prototype. The protocol was approved by the institutional animal care and use committee of the National University of Singapore.

Surgical Technique

After median sternotomy, cardiopulmonary bypass was established. After aortic crossclamping and institution of cardioplegia, the left atrium was opened and the mitral leaflets were excised, leaving behind a rim of 5 mm. In the control group, the mitral leaflets were excised. Sutures were inserted into the mitral annulus and the mitral prosthesis, followed by knot tying.

In the prototype group, the hinge ring was mounted on the valve holder and introduced into the left ventricle through the mitral annulus to the level at which the pins were just below the annulus. One by one, 12 pins were punched through the mitral annulus. When all 12 pins were in good position, the retainer ring was placed on top of the prototype hinge ring so that the pins could fit into the corresponding holes of the ring in the atrial side. The pins were then bent down against the retainer ring, by doing so pulling the hinge ring and retainer ring closer and thereby clamping the annulus and leaflet tissue in between. The prosthesis was then inserted, twisted, and clicked into position. Anchoring sutures and a valve holder were removed, and leaflet movement was checked. No valve suture was used. The left atrial wall was closed.

The animals were weaned from cardiopulmonary bypass in the usual fashion. The implanted valves were assessed by epicardial echocardiography (GE Vivid-i, 1.5- to 3.6-MHz transducer; GE Healthcare, Chalfont St Giles, UK). The animals were killed 1 hour after termination of cardiopulmonary bypass, and the hearts were harvested for gross examination. One animal was used to test the feasibility of reimplantation of the prosthesis. That animal's heart was put back on cardiopulmonary bypass, after which it was arrested and the left atrium reopened. The implanted PMV was untwisted and taken out. A new PMV was mounted on the valve holder and then inserted into the stable position inside the hinge ring in a twist-and-click fashion, resembling a bayonet mechanism.

RESULTS

The implantation and aortic crossclamp times of the prototype group were significantly shorter than those of the control group at 26.4 ± 4.6 minutes versus 12.4 ± 3.7 minutes ($P = .0005$) and 43.8 ± 8.5 minutes versus 29.4 ± 5.1 minutes ($P = .014$), respectively. Implantation time was reduced by 14 minutes in the prototype group (Table 1). Electrocardiography did not show any signs of atrioventricular block or ST segment changes. On echocardiography, no paraprosthetic leak was seen. There was a mild central leak arising between the leaflets of the prototype.

From the Departments of Surgery^a and Anaesthesia,^b Yong Loo Lin School of Medicine, National University of Singapore, Singapore; and the Biomedical Engineering Group,^c School of Engineering (Manufacturing), Nanyang Polytechnic, Singapore, Republic of Singapore.

Funded by Proof-of-Concept Grant, Singapore National Research Foundation.

Disclosures: Authors have nothing to disclose with regard to commercial support.

Received for publication Nov 21, 2011; revisions received Jan 9, 2012; accepted for publication Jan 16, 2012; available ahead of print Feb 13, 2012.

Address for reprints: Theo Kofidis, MD, FAHA, FAMS, Department of Cardiac, Thoracic and Vascular Surgery, National University Health System, Singapore, 1E Lower Kent Ridge Rd, NUHS Tower Block, Level 9, Singapore 119228 (E-mail: surtk@nus.edu.sg).

J Thorac Cardiovasc Surg 2012;143:985-8
0022-5223/\$36.00

Copyright © 2012 by The American Association for Thoracic Surgery
doi:10.1016/j.jtcvs.2012.01.037

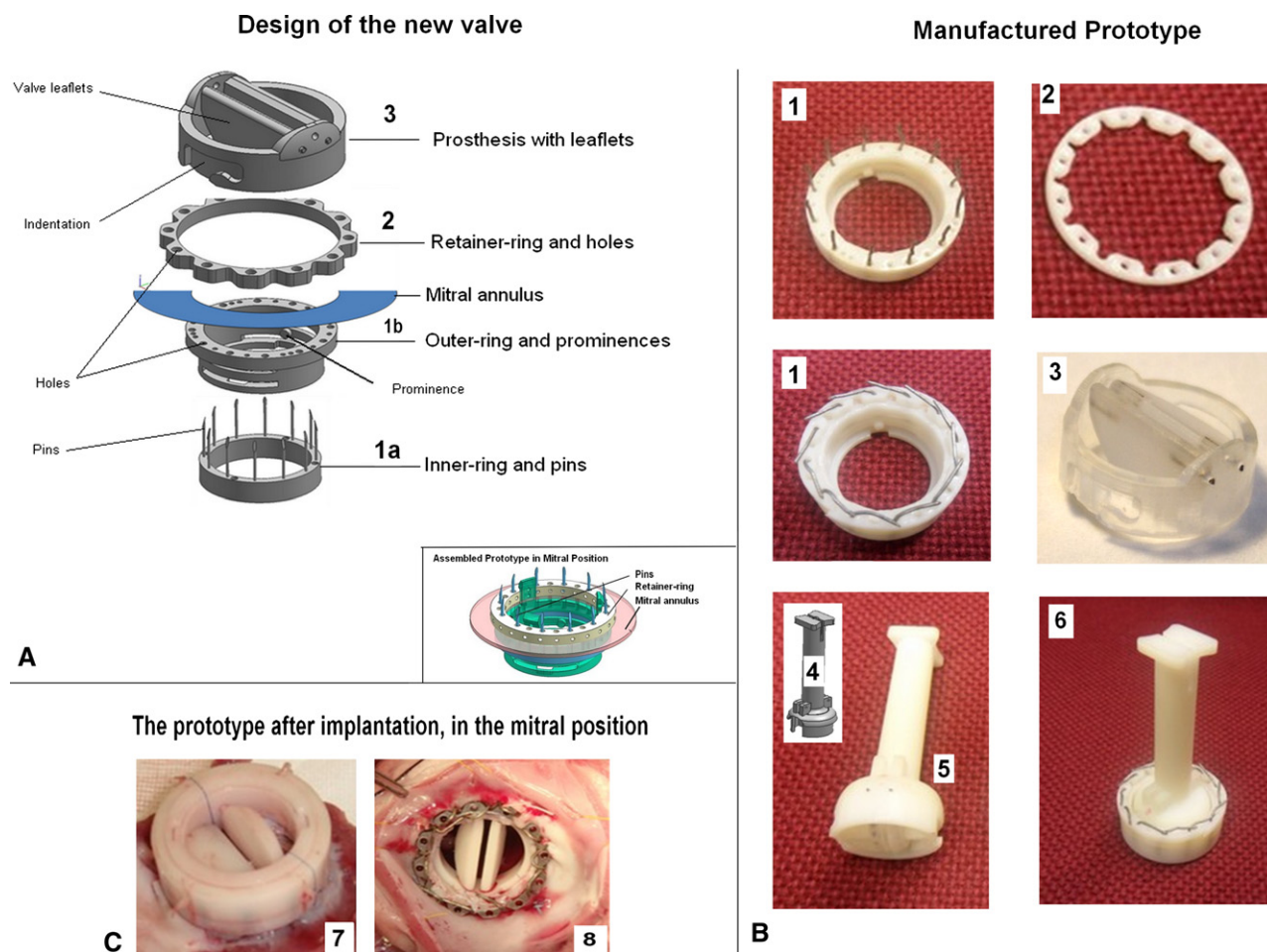


FIGURE 1. Design and prototype of the new valve. A, Design of the new valve. B, The manufactured prototype before implantation. The hinge ring consists of an outer piece carrying an array of pins (1a) and an inner piece carrying prominences (1b). The pins go through a series of holes in the inner piece when the 2 pieces are assembled before implantation. The assembled hinge ring with straight and bent pins (1). The retainer ring carries an array of holes to align with the pins from the atrial side of the mitral annulus, after the pins puncture through the real annulus (2). The mitral bileaflet disk prosthetic valve, with 2 indentations for engagement with prominences on the hinge ring (3). The valve holder (4). Prosthetic valve is mounted on the valve holder (5). The pins will be later bent to hold the rings together and attach to the annulus (6, 7). The prosthetic valve is inserted into the hinge ring in a twist-and-click fashion, resembling a bayonet mechanism (6). Removal of prosthetic valve can be done simply by twisting and pulling out, in the opposite direction. C, The prototype after implantation in the mitral position: atrial view (7) and ventricular view (8) of the prototype after implantation. The prototype attached firmly to the mitral annulus. The annular tissue was intact. Note that the healthy valve tissue of the pigs is much thinner and more fragile than that in human beings.

Post mortem gross examination demonstrated that the valve was attached firmly to the annulus. Wherever the pins went through the annulus, the tissue was intact (Figure 1, C). The total crossclamp time of reimplantation

was 8 minutes. On post mortem gross examination, we did examine the anatomy of aortic valve, aortic annulus, and circumflex artery, and we found no injury to the mentioned structures.

TABLE 1. Surgical time of control and prototype groups

Time	Control (n = 5)	Prototype (n = 8)	P value
Aortic crossclamp time (min)	43.8 ± 8.5	29.4 ± 5.1	.014
Implantation time (min)	26.4 ± 4.6	12.4 ± 3.7	.0005
Time of stitching sutures to annulus (min)	20.2 ± 3.5	0	

All data are mean ± SD.

DISCUSSION

Most surgeons manage to replace the mitral valve with a crossclamp time ranging from 74 to 93 minutes.^{2,3} The crossclamp time in our prototype group was significantly shorter (29.4 ± 5.1 minutes), because any time for suturing and tying the knots was omitted (Table 1). It should be noted that the operative duration until opening of the atrium remained the same (data not shown). Where

Download English Version:

<https://daneshyari.com/en/article/5990513>

Download Persian Version:

<https://daneshyari.com/article/5990513>

[Daneshyari.com](https://daneshyari.com)