




Contents lists available at ScienceDirect

## Epilepsy &amp; Behavior

journal homepage: [www.elsevier.com/locate/yebeh](http://www.elsevier.com/locate/yebeh)

## Review

## Functional neuroanatomy of disorders of consciousness

Carol Di Perri<sup>a,b</sup>, Johan Stender<sup>a,c</sup>, Steven Laureys<sup>a</sup>, Olivia Gosseries<sup>a,\*</sup><sup>a</sup> Coma Science Group, Cyclotron Research Centre & Neurology Department, University and University Hospital of Liege, Liege, Belgium<sup>b</sup> Department of Neuroradiology, National Neurological Institute C. Mondino, Pavia, Italy<sup>c</sup> Department of Neuroscience and Pharmacology, University of Copenhagen, Denmark

## ARTICLE INFO

## Article history:

Accepted 6 September 2013

Available online xxx

## Keywords:

Consciousness

Neuroimaging techniques

Brain connectivity

Vegetative/unresponsive wakefulness syndrome

Minimally conscious state

General anesthesia

Coma

## ABSTRACT

Our understanding of the mechanisms of loss and recovery of consciousness, following severe brain injury or during anesthesia, is changing rapidly. Recent neuroimaging studies have shown that patients with chronic disorders of consciousness and subjects undergoing general anesthesia present a complex dysfunctionality in the architecture of brain connectivity. At present, the global hallmark of impaired consciousness appears to be a multifaceted dysfunctional connectivity pattern with both within-network loss of connectivity in a widespread frontoparietal network and between-network hyperconnectivity involving other regions such as the insula and ventral tegmental area. Despite ongoing efforts, the mechanisms underlying the emergence of consciousness after severe brain injury are not thoroughly understood. Important questions remain unanswered: What triggers the connectivity impairment leading to disorders of consciousness? Why do some patients recover from coma, while others with apparently similar brain injuries do not? Understanding these mechanisms could lead to a better comprehension of brain function and, hopefully, lead to new therapeutic strategies in this challenging patient population.

**This article is part of a Special Issue entitled Epilepsy and Consciousness.**

© 2013 Elsevier Inc. All rights reserved.

## 1. Introduction

Consciousness is a multifaceted and ambiguous concept and the focus of both scientific and philosophical debate. Despite ongoing efforts, no universal definition of the term has been agreed on [1,2]. For practical and didactic purposes, consciousness is often described as having two main components: awareness and wakefulness [3]. Awareness refers to the phenomenal perception of self and surroundings or, in the words of Nagel, “the subjective character of experience” [4]. Awareness appears anatomically related to structures in the frontoparietal cortex [3]. At present, there is no single marker of awareness, but its presence can be clinically deduced from behavioral signs such as visual pursuit or responses to command [5]. Wakefulness describes the state of arousal or the potential to experience awareness. It is supported by structures in the brainstem and clinically evidenced by the eyes being open [3]. Wakefulness generally precipitates awareness; an increase in arousal is usually accompanied by an increase of conscious experience, leading to a linear correlation of the two components along the

spectrum of consciousness [2]. For example, during deep sleep, coma, and anesthesia, awareness and wakefulness decline simultaneously [3]. In some cases, however, the two are dissociated. On the one hand, during vivid dreams, wakefulness is lowered, whereas internal awareness is preserved. On the other hand, in some pathological states, wakefulness is spared, while awareness is impaired [6–8]. These states comprise the minimally conscious state (MCS) and the vegetative state (VS, now also called the unresponsive wakefulness syndrome – UWS [9,10]), as well as absence seizures, complex partial seizures, and somnambulism (Fig. 1). Studies of these dissociated states offer a unique opportunity to disentangle and critically investigate the neural correlates of awareness.

Here, we review the current understanding of (un)consciousness obtained from studies of disorders of consciousness (DOC) following brain injury (coma, VS/UWS, and MCS) and general anesthesia. We focus on functional neuroimaging studies and address the utility of these techniques in the diagnosis of patients with DOC (for a review on electroencephalography – EEG – studies, see [11]).

## 2. Disorders of consciousness and neural correlates of awareness

Disorders of consciousness remain among the most challenging and poorly understood conditions in modern medical care. Patients with VS/UWS are seemingly awake but exhibit no behavioral signs of awareness [3]. Vegetative state/unresponsive wakefulness syndrome typically follows a coma, a state of complete unconsciousness from

*Abbreviations:* DOC, disorders of consciousness; VS, vegetative state; UWS, unresponsive wakefulness syndrome; MCS, minimally conscious state; fMRI, functional magnetic resonance imaging; EEG, electroencephalography; TMS, transcranial magnetic stimulation.

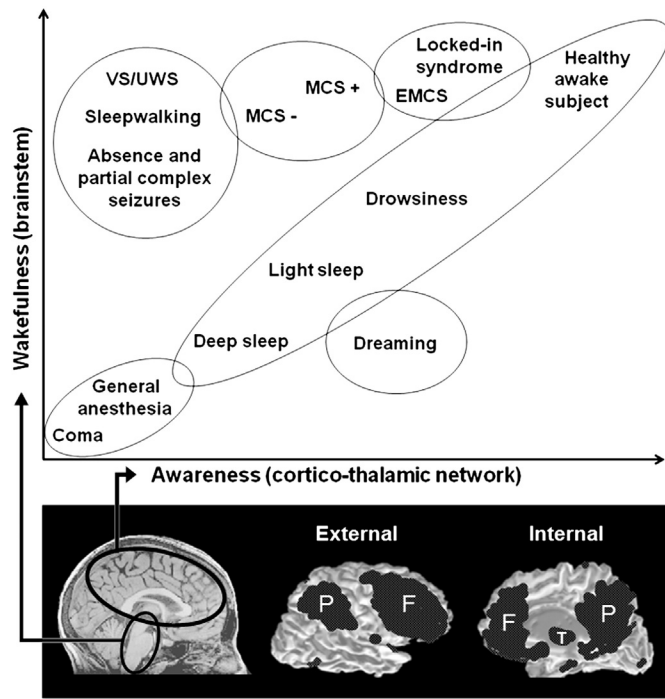
\* Corresponding author at: Coma Science Group, Cyclotron Research Center and Neurology Department, University and University Hospital of Liege, Sart-Tilman B30, 4000 Liege, Belgium. Fax: +32 4 366 29 46.

E-mail address: [ogosseries@ulg.ac.be](mailto:ogosseries@ulg.ac.be) (O. Gosseries).

1525-5050/\$ – see front matter © 2013 Elsevier Inc. All rights reserved.

<http://dx.doi.org/10.1016/j.yebeh.2013.09.014>

Please cite this article as: Di Perri C, et al, Functional neuroanatomy of disorders of consciousness, *Epilepsy Behav* (2013), <http://dx.doi.org/10.1016/j.yebeh.2013.09.014>



**Fig. 1.** The two main components of consciousness: wakefulness and awareness. Correlation between wakefulness, related to brainstem ascending reticular activating systems [68], and awareness, related to cortico-thalamic network connectivity. In most physiological, pharmacological, and pathological alterations of consciousness, wakefulness and awareness are positively linearly correlated. In some cases, however, both components of consciousness are dissociated. Vegetative state/unresponsive wakefulness syndrome, VS/UWS; minimally conscious state, MCS; emergence of MCS, EMCS. Adapted from [3].

which the patient cannot be aroused [12,13]. Minimally conscious state patients show fluctuating awareness and may respond appropriately to some stimuli [14]. Minimally conscious state was recently subcategorized as MCS plus and MCS minus based on the presence or absence, respectively, of language comprehension [15]. Emergence from MCS is defined as the return of reliable communication or functional use of objects [14].

Conventional brain structural imaging studies have shown heterogeneous lesion patterns in DOC, suggesting that no specific brain region can be unequivocally related to awareness [16]. This is supported by observations in transient unconscious states, such as during epileptic seizures, where the core pathology is related to the abnormality of brain function rather than macroscopic structure [17]. Nonetheless, widespread diffuse axonal injury and thalamic damage have been observed in patients with VS/UWS following traumatic brain injury [18,19], supporting the role of the thalamus and cerebral cortex in the genesis of awareness.

Using 18-fluorodesoxyglucose positron emission tomography, a technique which measures brain energy turnover, we showed that awareness is not tightly related to the global brain metabolism [20] but, rather, to the preservation of a large-scale frontoparietal network encompassing the polymodal associative cortices [21]. In line with their clinical condition, patients with MCS show a partial preservation of this large-scale associative frontoparietal network [22]. Similar findings of frontoparietal deactivation have been recorded in somnambulism as well as in absence and complex partial (mainly in the temporal lobe) seizures [6–8], whereas temporal lobe seizures without loss of consciousness are not accompanied by these widespread changes [7].

Connectivity within the frontoparietal regions and their thalamic connections appear to play a key role in the maintenance of consciousness. Thus, reestablishment of thalamocortical activity in a

patient with VS/UWS was observed upon recovery [20]. Furthermore, disconnection between primary sensory areas and higher-order associative cortices, which are thought to be required for conscious perception [3], has been demonstrated in patients with VS/UWS during passive auditory and noxious stimulations [23,24].

There is now increasing evidence that this large anatomical frontoparietal cortex contains at least two main functional networks, clearly linked to spontaneous mentation (Fig. 1) [25]. The external awareness network, or executive control network, subserved by lateral frontoparietal regions, shows increasing activity during attention-demanding cognitive tasks. The internal awareness network, or default mode network (DMN), is a mesial frontoparietal network that appears to be involved in self-related processes [26]. Activity in the two networks is normally anticorrelated – when one is active, the other is not [25]. However, studies using functional magnetic resonance imaging (fMRI) found decreasing anticorrelation in anesthesia [27], deep sleep [28], and VS/UWS [29], showing the anticorrelation to be a core constituent of conscious cognition [30].

Because of its link to internally oriented cognitive content, such as mind-wandering and autobiographical memory recall, the DMN, in particular, has been proposed as the locus of conscious awareness [25,31,32]. Resting-state fMRI studies have detected reduced connectivity in the DMN of patients in coma, VS/UWS, and MCS (Fig. 2) [33]. This decrease of connectivity was correlated to the level of consciousness, mostly affecting the precuneus, a brain area considered to be a critical hub within this network with a massive degree of interconnectivity [34]. Similar decreases in DMN connectivity were observed in healthy controls during deep sleep [35], sedation, and general anesthesia (Fig. 2) [27]. Nevertheless, coherent DMN connectivity has also been observed in VS/UWS and anesthetized monkeys [29,36]. This suggests that the DMN may not be a strict reflection of conscious mental activity, and there are indications that the role of the DMN in consciousness is highly complex. Concurrent with decreasing DMN connectivity, we recently reported increased connectivity in the deep structures of the limbic system (i.e., the ventral tegmental area, the insula, the orbitofrontal cortex, and the hypothalamus) in patients with DOC (Fig. 3). The effect was greater in patients with VS/UWS than in patients with MCS [37]. This limbic hyperconnectivity may reflect the persistent engagement of residual neural activity in self-reinforcing neural loops which may disrupt normal patterns of connectivity, including synchronized neural activity in DMN. A loss of connectivity is, therefore, not necessarily the global hallmark of impaired consciousness but only an aspect of a multifaceted dysfunction in the architecture of brain connectivity [37]. Correspondingly, patients with complex partial seizures due to temporal lobe epilepsy associated with mesial sclerosis show increased regional synchronization in areas outside the DMN, such as the ipsilateral parahippocampal gyrus, midbrain, insula, corpus callosum, bilateral sensorimotor cortex, and frontoparietal subcortical structures [38]. Although these findings were detected during interictal periods, they might still support more complex connectivity interplay in the emergence of consciousness.

### 3. Detection of awareness in disorders of consciousness

Detection of potential awareness in uncommunicative brain-damaged patients raises important ethical and medical concerns regarding end-of-life decisions and palliative treatment [5]. At present, the gold standard to assess the level of consciousness is behavioral assessment [5]. Lack of behavioral responsiveness does not, however, imply absence of consciousness. Clinical studies have shown that up to 40% of patients with a diagnosis of VS/UWS may, in fact, retain some level of awareness [39–41]. The main causes of misdiagnosis are associated with patient's disabilities such as paralysis or aphasia, confusion of terminology, and the use of nonstandardized diagnostic methods [42]. Even with the best clinical assessment, the level of awareness in patients with DOC can still be underestimated [43]. Indeed, neuroimaging

Download English Version:

<https://daneshyari.com/en/article/6012456>

Download Persian Version:

<https://daneshyari.com/article/6012456>

[Daneshyari.com](https://daneshyari.com)