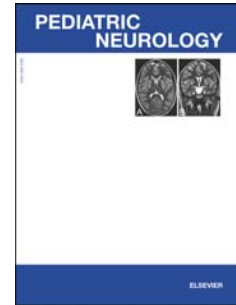


# Accepted Manuscript

Vanishing white matter disease presenting as opsoclonus myoclonus syndrome in childhood – a case report and review of the literature

Lisa Klingelhofer, Anjum Misbahuddin, Tania Jawad, John Mellers, Jozef Jarosz, Robert Weeks, K. Ray Chaudhuri



PII: S0887-8994(14)00159-3

DOI: [10.1016/j.pediatrneurol.2014.03.008](https://doi.org/10.1016/j.pediatrneurol.2014.03.008)

Reference: PNU 8305

To appear in: *Pediatric Neurology*

Received Date: 20 February 2014

Revised Date: 4 March 2014

Accepted Date: 7 March 2014

Please cite this article as: Klingelhofer L, Misbahuddin A, Jawad T, Mellers J, Jarosz J, Weeks R, Chaudhuri KR, Vanishing white matter disease presenting as opsoclonus myoclonus syndrome in childhood – a case report and review of the literature, *Pediatric Neurology* (2014), doi: 10.1016/j.pediatrneurol.2014.03.008.

This is a PDF file of an unedited manuscript that has been accepted for publication. As a service to our customers we are providing this early version of the manuscript. The manuscript will undergo copyediting, typesetting, and review of the resulting proof before it is published in its final form. Please note that during the production process errors may be discovered which could affect the content, and all legal disclaimers that apply to the journal pertain.

**Vanishing white matter disease presenting as opsoclonus  
myoclonus syndrome in childhood – a case report and review of  
the literature**

Lisa Klingelhofer<sup>1,2</sup>, Anjum Misbahuddin<sup>3</sup>, Tania Jawad<sup>4</sup>, John Mellers<sup>5</sup>, Jozef Jarosz<sup>6</sup>,  
Robert Weeks<sup>7</sup>, K Ray Chaudhuri<sup>1</sup>

<sup>1</sup> National Parkinson Foundation International Centre of Excellence, Department of Neurology, King's College Hospital and King's College, Denmark Hill, London, UK

<sup>2</sup> Department of Neurology, Technical University Dresden, Fetscherstraße 74, Dresden, Germany

<sup>3</sup> Essex Centre for Neurological Sciences, Romford, UK

<sup>4</sup> National Hospital for Neurology and Neurosurgery, Denmark Hill, London, UK

<sup>5</sup> Department of Neuropsychiatry, Maudsley Hospital, Denmark Hill, London, UK

<sup>6</sup> Department of Neuroradiology, King's College Hospital, Denmark Hill, London, UK

<sup>7</sup> Department of Neurology, King's College Hospital, Denmark Hill, London, UK

Corresponding author: **Lisa Klingelhofer**, MD, Fellow, National Parkinson Foundation International Centre of Excellence, Department of Neurology, King's College Hospital and King's College, Denmark Hill, London SE5 9RS, UK, Phone: 00447456786911, email: [lisa.klingelhofer@nhs.net](mailto:lisa.klingelhofer@nhs.net) AND Department of Neurology, Technical University Dresden, Fetscherstraße 74, Dresden, Germany

Coauthors:

**Anjum Misbahuddin**, FRCP, PhD, Consultant, [anjum\\_m@hotmail.com](mailto:anjum_m@hotmail.com), Essex Centre for Neurological Sciences, Romford, UK

**Tania Jawad**, MRCP, PhD, Fellow, [taniajawad@nhs.net](mailto:taniajawad@nhs.net), National Hospital for Neurology and Neurosurgery, Denmark Hill, London, UK

**John Mellers**, MD FRCPsych, Consultant Neuropsychiatrist, [John.Mellers@slam.nhs.uk](mailto:John.Mellers@slam.nhs.uk), Department of Neuropsychiatry, Maudsley Hospital, Denmark Hill, London, SE5 8AZ, UK

**Jozef Jarosz**, MD FRCP, Consultant Neuroradiologist and Clinical Director Neurosciences, [jozef.jarosz@nhs.net](mailto:jozef.jarosz@nhs.net), Department of Neuroradiology, King's College Hospital, Denmark Hill, London, SE5 9RS, UK

Download English Version:

<https://daneshyari.com/en/article/6042270>

Download Persian Version:

<https://daneshyari.com/article/6042270>

[Daneshyari.com](https://daneshyari.com)