
Gap coronoidotomy for management of coronoid process hyperplasia of the mandible

Chun-Ming Chen, DDS, MS,^{a,b} Chao-Ming Chen, DDS,^a Cho-Ming Ho, DDS, DDS,^a and I-Yueh Huang, DDS, MS,^{a,b} Kaohsiung, Taiwan
KAOHSIUNG MEDICAL UNIVERSITY

Patients with coronoid process hyperplasia of the mandibular area are rare. The treatment of this disease is to increase the patient's mouth opening by surgery. There are various, but controversial, methods to treat it. We present a modified (gap) coronoidotomy procedure in detail and compare it with other conventional methods to treat coronoid process hyperplasia. (**Oral Surg Oral Med Oral Pathol Oral Radiol Endod 2011;112:e1-e4**)

Coronoid process hyperplasia (CPH) of the mandible is a rare disease, with the main symptoms of limited mouth opening and possible misdiagnoses as temporomandibular joint (TMJ) ankylosis or TMJ disorder. An increase in cases reported has helped dentists to make an accurate diagnosis by panoramic examination¹ and 3D computed tomography,²⁻⁴ but the treatment of CPH is still controversial. Several methods have been applied, such as extraoral coronoidectomy,⁵ intraoral coronoidectomy, and intraoral coronoidotomy. According to McLoughlin et al.'s research,⁶ the most common surgical method is intraoral coronoidectomy and the second most common method extraoral coronoidectomy. Intraoral coronoidotomy is seldom applied.^{7,8} We treated our first and second cases of CPH in our department by conventional intraoral coronoidotomy, but mild disocclusion was noted in 1 of the 2 patients owing to the coronoid process interfering with the upper part of the ramus on closing the mouth (Fig. 1). When we had our third and fourth cases of (CPH) in 2007 and 2008, we used modified (gap) coronoidotomy to avoid this minor but significant complication. The purposes of the present report are to introduce this method in detail and to compare its advantages and disadvantages with other methods.

SURGICAL PROCEDURE OF GAP CORONIDOTOMY

The gap coronoidotomy is removal of a bone segment from the coronoid process instead of only cut-

ting the coronoid process through. The patient is in a supine position under general anesthesia, and an incisional line is made anterior to the ramus. Then the periosteum is reflected from the anterior border of the ramus to the outer surface of the middle part of the ramus, upward to the inner and outer surface of the coronoid process ~1 cm above the sigmoid notch. The lower border of the reflected periosteum is slightly below the occlusal plane level, similar to the procedure for conventional coronoidotomy, but the reflected area is smaller than that of coronoidectomy. It is not necessary to strip the temporalis muscle attachment completely (Fig. 2). Then a channel retractor is inserted from the outer side of the ramus and a malleable retractor on the inner side to protect the soft tissue and the inferior neurovascular bundle when cutting the coronoid process. A reciprocal saw is used first to perform the upper osteotomy of the gap coronoidotomy, ~6-7 mm above the lower cut which is made just at the anterior part of the sigmoid notch (Fig. 3). When making the lower osteotomy, the bone segment is retained with a bone holder removed (Fig. 4), and the cutting surface is smoothed with a bone file. The interincisor mouth opening is measured, which will be the objective of the postoperative mouth opening exercise. After irrigation with copious normal saline solution, the wound is closed in layers. Extraoral pressure dressing is placed over the skin above the ramus to prevent severe swelling after surgery. Mouth opening exercise commences 1 week after surgery.

DISCUSSION

Coronoid process hyperplasia is a rare disorder of uncertain etiology that can occur in both unilateral and bilateral forms. It appears as a slow but progressive reduction in mouth opening. A definitive diagnosis is established by the findings of a detailed history review, physical examination, panoramic ra-

^aDivision of Oral and Maxillofacial Surgery, Kaohsiung Medical University Hospital.

^bSchool of Dentistry, College of Dental Medicine, Kaohsiung Medical University, Kaohsiung, Taiwan.

Received for publication Feb. 20, 2011; returned for revision Mar. 27, 2011; accepted for publication Mar. 31, 2011.

1079-2104/\$ - see front matter

© 2011 Mosby, Inc. All rights reserved.

doi:10.1016/j.tripleo.2011.03.040

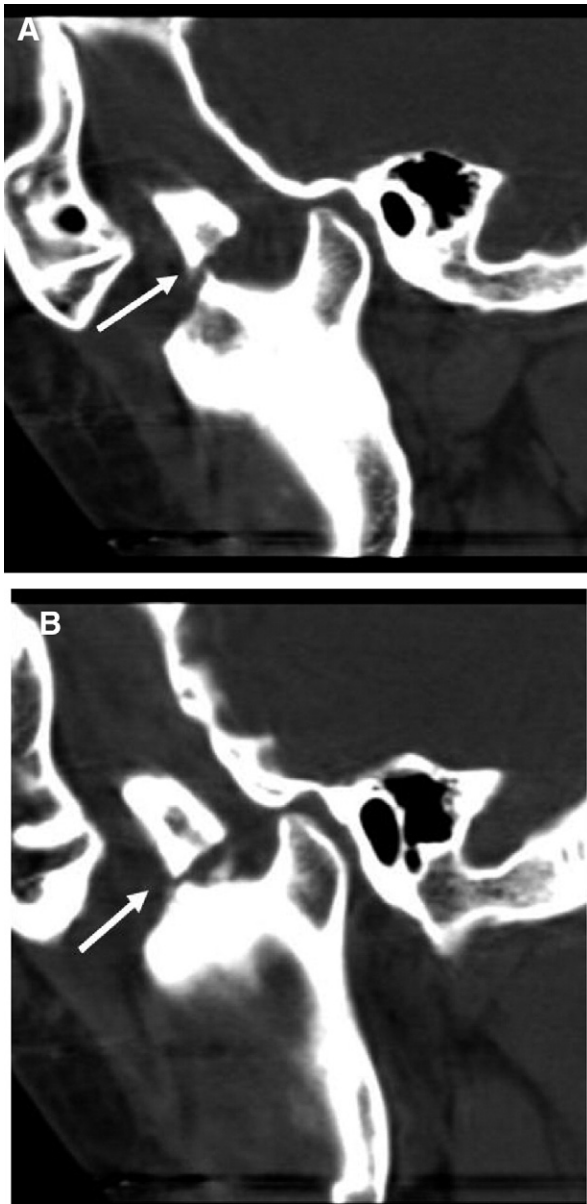


Fig. 1. An improper direction of bone cutting and less upward displacement of the coronoid process makes the gap between 2 segments insufficient (as indicated) which may cause interference to the upper part of the ramus in a centric occlusion position and cause mild disocclusion.

diographic analysis, and 3-dimensional computerized tomography image. In 1 CPH patient, mouth opening limitation was caused by interference of the coronoid process movement by the zygoma^{7,8}; the goal of management for CPH is to surgically remove this interference.⁹ The objective of coronoidectomy, which removes the coronoid process completely, is to relieve the interference between an elongated

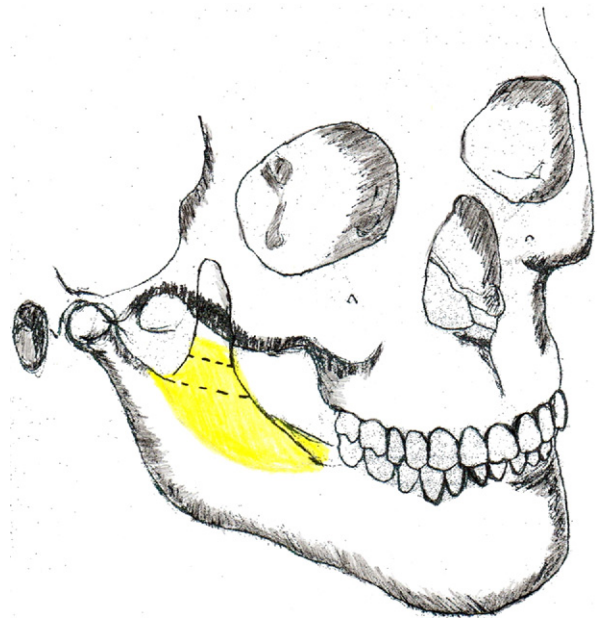


Fig. 2. Exposed area is limited to the sigmoid notch, lower part of the coronoid process, and outer and inner part of the ramus, enough to insert malleable and channel retractors.

coronoid process and the zygoma, or an articulation between them, as well as to prevent the upper displaced coronoid process from interfering with the movement of the mandible by contacting the upper part of the ramus. However, coronoidectomy needs wider tissue reflection, which causes more tissue damage and creates more scarring after surgery, which may cause trismus to recur. It is usually difficult to perform coronoidectomy if articulation of the coronoid process and zygoma exists. Some surgeons approach by extraoral method to ensure complete coronoidectomy combined with myotomy,⁹ fasciotomy, and zygomatic osteotomy.

In the literature, there are few reports of coronoidectomy. Gerbino et al. used conventional coronoidectomy to treat 5 cases of CPH with good results⁷ and concluded that coronoidotomy with less trauma can decrease fibrosis and prevent recurrence of trismus. The gap created by upward displacement of the coronoid process after coronoidotomy can also prevent reunion of the 2 bone segments.^{6,9} In our first case, we found that the displacement of the coronoid process was not enough and interfered with the upper part of the ramus, and mild disocclusion in centric occlusion position was noted. To prevent this unpredictable problem, we treated subsequent CPH cases by gap coronoidotomy with good results. This modification has the same approach procedures as conventional coronoidotomy, with only 1 additional

Download English Version:

<https://daneshyari.com/en/article/6059381>

Download Persian Version:

<https://daneshyari.com/article/6059381>

[Daneshyari.com](https://daneshyari.com)