



Lymphedema in a 7-year-old boy infected with *Wuchereria bancrofti* in Sierra Leone: A case report



Mackenzie Dome^{a,1}, Rashid Ansumana^{b,c,*,1}, Andrea L. Covington^b, Maria P. Rebollo^c, Santigie Sesay^d, Kathryn H. Jacobsen^e, Dziedzom K. de Souza^f, Benjamin G. Koudou^c, Edwin Michael^g, Moses J. Bockarie^c

^a Eck Institute for Global Health, University of Notre Dame, Notre Dame, IN, USA

^b Mercy Hospital Research Laboratory, Bo, Sierra Leone

^c Centre for Neglected Tropical Diseases, Liverpool School of Tropical Medicine, Liverpool, UK

^d Ministry of Health and Sanitation, Freetown, Sierra Leone

^e Department of Global and Community Health, George Mason University, Fairfax, VA, USA

^f Noguchi Memorial Institute for Medical Research, University of Ghana, Legon, Ghana

^g Department of Biological Sciences, University of Notre Dame, Notre Dame, USA

ARTICLE INFO

Article history:

Received 23 October 2013

Received in revised form 2 February 2014

Accepted 10 February 2014

Available online 18 February 2014

Keywords:

Lymphatic filariasis

Filarial elephantiasis

Lymphedema

Milroy's disease

Child

Complications

ABSTRACT

We present a case of congenital lymphedema in a 7-year-old boy in Sierra Leone with active filarial infection and penile edema. The genital edema with onset at 6 months of age may have been due to a congenital abnormality in lymphatic drainage. Other possible causes of childhood lymphedema, including Milroy's disease, are discussed.

© 2014 The Authors. Published by Elsevier B.V. This is an open access article under the CC BY-NC-SA license (<http://creativecommons.org/licenses/by-nc-sa/3.0/>).

1. Introduction

Lymphatic filariasis (LF) is a major cause of acute and chronic morbidity manifested as lymphedema and hydrocele. The clinical signs and symptoms of LF affect more than 40 million people globally, making the disease the second-largest cause of permanent and long-term disability worldwide (Shenoy and Bockarie, 2011; Chu et al., 2010). LF is a major obstacle to socioeconomic development in the 73 countries across Africa, Southeast Asia, the Americas, and the Pacific region that are known to be endemic for the mosquito-borne disease (WHO, 2013; Addiss, 2010).

LF infection is often acquired in childhood in areas of high transmission intensity, but infected individuals usually do not develop clinical disease until years later when they are adults. More than 250 million children are exposed to LF worldwide, and in high

endemic areas up to 10% of children under the age of 15 years are infected (Bockarie et al., 2002). In 2000, the World Health Organization launched the Global Program to Eliminate LF (GPELF) using the pro-poor strategy of preventive chemotherapy and transmission control (PCT) together with vector control, morbidity management, and disability prevention (WHO, 2013). The mass drug administration (MDA) strategy used for PCT combines albendazole with either ivermectin or diethylcarbamazine citrate (DEC). However, not all at-risk children in high-risk areas are able to access MDA.

Lymphatic filariasis caused by *Wuchereria bancrofti* is highly endemic in Sierra Leone, where more than 90% of the 6.6 million people are at risk of acquiring the infection. (Hodges et al., 2012; Koroma et al., 2012) Filarial disease is common in all the endemic districts in the country, but there is no record previously of lymphedema in a child less than 10 years old. Here we present a case of lymphedema in a 7-year-old boy with patent LF.

2. Case report

During a transmission assessment survey to determine the success of four rounds of MDA on reducing LF transmission in north

* Corresponding author at: Mercy Hospital Research Laboratory, Kulanda Town, Bo, Sierra Leone. Tel.: +232 76 683832.

E-mail address: r.ansumana@liverpool.ac.uk (R. Ansumana).

¹ These authors contributed equally to this study.

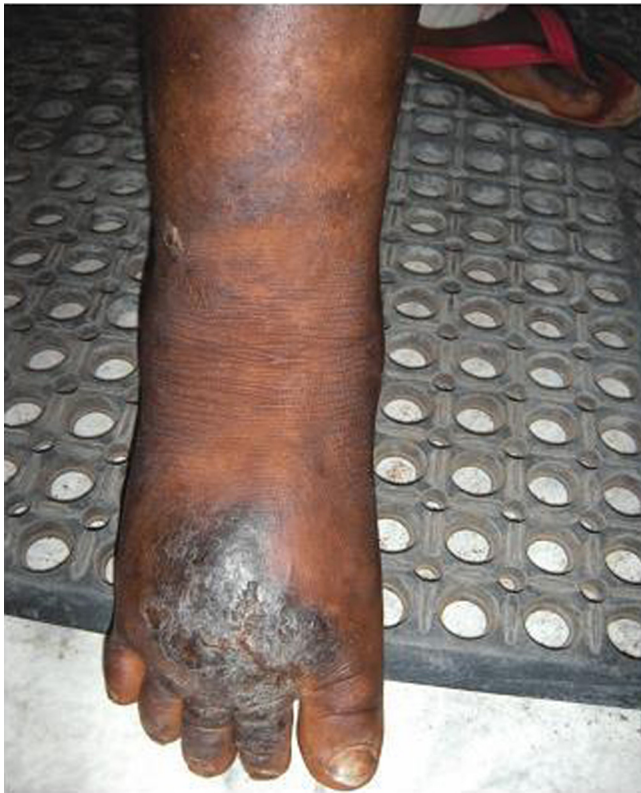

Fig. 1. Lymphedema of Right Lower Extremity.

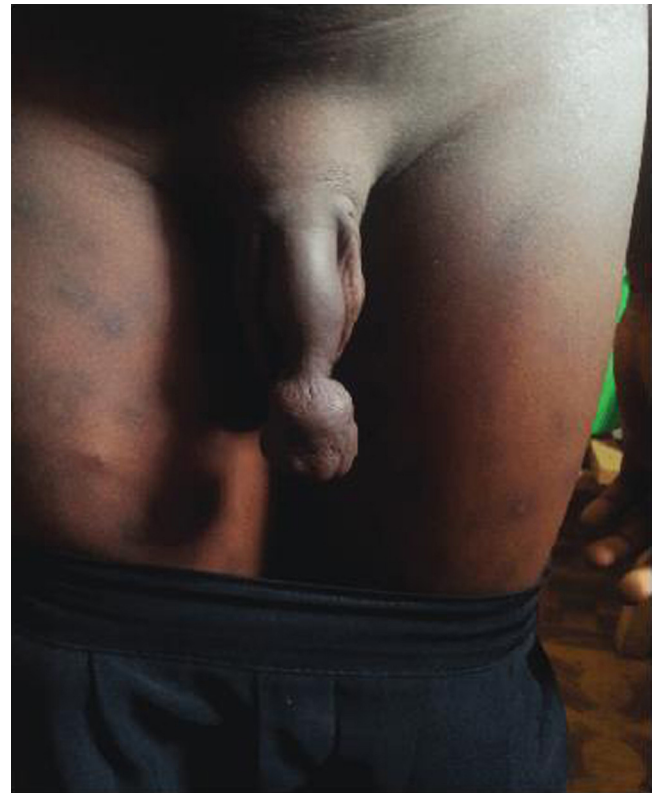


Fig. 2. Deformed Prepuce.

central Pujehun District, Sierra Leone, a 7-year-old boy from a rural village presented with chronic progressive lymphedema of the right lower extremity. The overlying tissue of the distal extremity was indurated, possibly due to secondary infection and tissue trauma, and there were dermatologic changes of the right foot consistent with elephantiasis (Fig. 1). The temperature of the swollen areas was normal, with no signs of nodular or warty excrescences. The boy's father reported that asymmetrical non-pitting edema had been present since birth, and had increased in severity over time. Keratosis spots were present over the entire body, and the prepuce of the penis showed a significant deformity that the father said had been present since the child was six months of age (Fig. 2). The father gave permission for photographs of the child and case information to be published.

The boy tested positive for circulating filarial antigenemia using a BinaxNOW filariasis Immuno Chromatographic Test (ICT) (Inverness Medical Professional Diagnostics, Prehold, NJ, USA), and a night blood smear examination with Giemsa stain confirmed Bancroftian filariasis with 313 *W. bancrofti* mf/ml of blood prior to treatment. The parasite was sheathed with nuclei in the tail end and was morphologically distinguishable from the *Mansonella* species which can also be found in human blood in Africa. These observations and the species-specific ICT positive result confirmed that the microfilaria observed in the blood were *W. bancrofti*. Initial treatment prescribed for the active filarial infection was a 6 mg dose of ivermectin and a 400 mg dose of albendazole every three months with follow-up. The father reported that the boy had not been previously treated for LF infection.

The boy had lived with his parents in rural Pujehun District for the past four years, and they previously resided in Kono District (Fig. 3). Before her pregnancy with the boy and during the end of her first trimester, his mother had resided in Kono District with her grandmother, a resident of Bombali District, who had elephantiasis.

Both Bombali and Kono Districts were endemic for LF prior to the MDA and the birth of the boy (Koroma et al., 2013).

As part of the investigation of the child's disease, family members were examined for LF. The mother tested LF positive based on both ICT and night blood smear examination, and reported taking only one round of MDA during her lifetime. The boy's father and the boy's only sibling both tested negative. None of the immediate family members had anatomical abnormalities related to LF. However, a family history suggested that the boy's deceased maternal grandmother likely also had an advanced filarial infection, as she had progressive lymphedema of the lower right extremity that developed over the last five years of her life.

Two months after the boy's initial diagnosis, following prescribed treatment with ivermectin and albendazole, a night blood smear test showed no evidence of circulating microfilaria. A complete blood count, comprehensive metabolic panel, and urinalysis were all found to be within normal limits. A physical examination revealed no evidence of another inciting condition. Both the child and his father were also tested at this time for several other infectious diseases, including human immunodeficiency virus (HIV), dengue, leptospirosis, chikungunya, malaria, syphilis, onchocerciasis, and hepatitis A, B, and C. Both tested positive for malaria, with all other tests negative.

The patient was prescribed a daily dose of 200 mg of doxycycline, which has been shown to cause significant reductions in lymphedema in patients with Grade II–III LF following 12–24 months of treatment, regardless of circulating filarial status (Mand et al., 2012). Although some risk of adverse effects has been reported in administration of doxycycline to children under 10 years old, the treating physician concluded that with appropriate safety monitoring the benefits of doxycycline for this patient outweighed the potential risks. Additionally, the ballooning foreskin of the boy was removed through circumcision. The biopsied tissue was unremarkable.

Download English Version:

<https://daneshyari.com/en/article/6127378>

Download Persian Version:

<https://daneshyari.com/article/6127378>

[Daneshyari.com](https://daneshyari.com)