

Clinical note

# Incidental pathologic extracardiac uptake of $^{99m}\text{Tc}$ -tetrofosmin in myocardial perfusion imaging: Importance of patient background evaluation

B. González García\*, A.M. García Vicente, A. Palomar Muñoz, V.M. Poblete García, G.A. Jiménez Londoño, A.M. Soriano Castrejón

Servicio de Medicina Nuclear, Hospital General Universitario de Ciudad Real, Spain

## ARTICLE INFO

### Article history:

Received 6 February 2015

Accepted 13 March 2015

Available online xxx

### Keywords:

Myocardial perfusion SPECT

Extracardiac findings

Non-cardiac chest pain

$^{99m}\text{Tc}$ -tetrofosmin

## ABSTRACT

$^{99m}\text{Tc}$ -tetrofosmin single photon emission computed tomography ( $^{99m}\text{Tc}$ -tetrofosmin SPECT) has an important role in the assessment of coronary artery disease. Despite being its main indication, this study does not only evaluate myocardial perfusion, but much more. Moreover, during the SPECT acquisition, the field area covered includes many important organs of the thorax and abdomen, so extracardiac abnormalities can be observed. The correct etiologic diagnosis of them is only possible if we understand how  $^{99m}\text{Tc}$ -tetrofosmin works and make a comprehensive investigation of the clinical history of the patient.

© 2015 Elsevier España, S.L.U. and SEMNIM. All rights reserved.

## Captación extracardíaca patológica de $^{99m}\text{Tc}$ -tetrofosmin, detectada incidentalmente en un estudio de perfusión miocárdica: importancia de la evaluación de los antecedentes clínicos del paciente

## RESUMEN

La tomografía con  $^{99m}\text{Tc}$ -tetrofosmin ( $^{99m}\text{Tc}$ -tetrofosmin SPECT) desempeña un papel fundamental en la evaluación de la enfermedad coronaria. A pesar de que esta es su principal indicación, debemos recordar que estos estudios no evalúan únicamente la perfusión miocárdica, sino mucho más. Además, durante la adquisición de la SPECT, el campo incluye gran parte del tórax y abdomen, por lo que podemos observar enfermedad extracardíaca en las regiones incluidas. Llegar a un correcto diagnóstico etiológico de esas alteraciones solo es posible si entendemos cómo funciona el  $^{99m}\text{Tc}$ -tetrofosmin y realizamos una exhaustiva investigación de los antecedentes e historia clínica del paciente.

© 2015 Elsevier España, S.L.U. y SEMNIM. Todos los derechos reservados.

### Palabras clave:

SPECT de perfusión miocárdica

Captación extracardíaca

Dolor torácico no cardiológico

$^{99m}\text{Tc}$ -tetrofosmin

## Introduction

$^{99m}\text{Tc}$ -tetrofosmin single photon emission computed tomography ( $^{99m}\text{Tc}$ -tetrofosmin SPECT) is a well-established, non-invasive imaging technique in the management of angina and myocardial infarction, and has become widely used for diagnosis and assessment of prognosis in patients with known or suspected coronary artery disease. Furthermore it is important to note that  $^{99m}\text{Tc}$ -tetrofosmin is an agent that has been used as oncotropic radiotracer, and is highly concentrated within neoplastic processes of several varieties because of its uptake in mitochondria, being excreted by hepatobiliary system.<sup>1</sup>

In  $^{99m}\text{Tc}$ -tetrofosmin SPECT, although most of the information is obtained from the tomographic slices, the raw projection images

should be examined in order to evaluate incidental cardiac or extracardiac findings, and to assess the quality of the study.<sup>2</sup>

We present a case in which myocardial perfusion imaging (MPI) revealed an unexpected extracardiac activity in posteromedial region of the right hemithorax. Exhaustive clinical history revision was paramount to a correct evaluation of the finding.

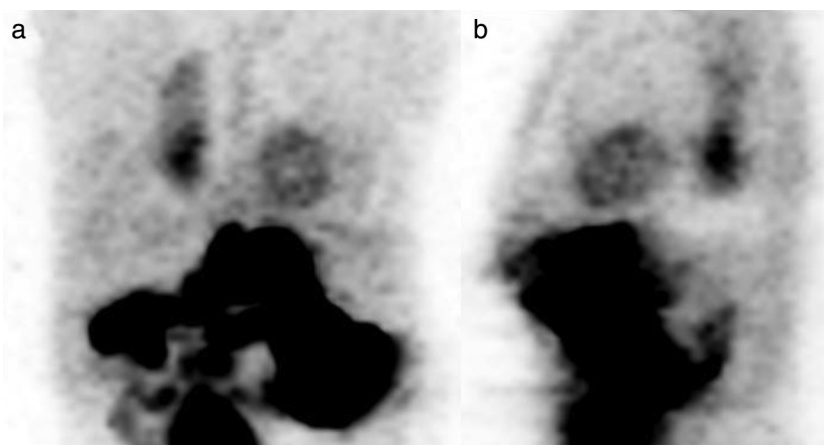
## Case report

A 71-year-old man, with a history of alcoholism until 5 years ago, without diabetes or hypertension, was referred for a  $^{99m}\text{Tc}$ -tetrofosmin SPECT/CT because of chest pain. Patient was diagnosed of one year ago of squamous cell esophageal carcinoma stage pT2N0M0 and underwent esophagectomy. No chemotherapy or radiotherapy was required.

The day of the MPI, the patient underwent adenosine stress, and subsequently 740 MBq  $^{99m}\text{Tc}$ -tetrofosmin was injected intravenously. Thirty minutes after radiotracer injection, a SPECT/CT

\* Corresponding author.

E-mail address: [bgg-ist@hotmail.com](mailto:bgg-ist@hotmail.com) (B. González García).



**Fig. 1.** Anterior and lateral raw data of  $^{99m}\text{Tc}$ -tetrofosmin SPECT images at stress show vertical extracardiac linear activity, located in right posterior thorax, near the midline.

imaging with a dual head gamma-camera (Infinia Hawkeye, GE) was acquired. The cardiac images showed normal myocardial perfusion but, on the raw projection image, an extracardiac uptake, located in right posterior thorax, near the midline, was noted (Fig. 1). Reconstructed SPECT/CT slices confirmed the activity in the right-posterior mediastinum, with a linear morphology, in correspondence with an elongated mass on CT obtained for attenuation correction purpose (Fig. 2). Additionally, this CT showed massive left pleural effusion, without increased activity of the radiotracer.

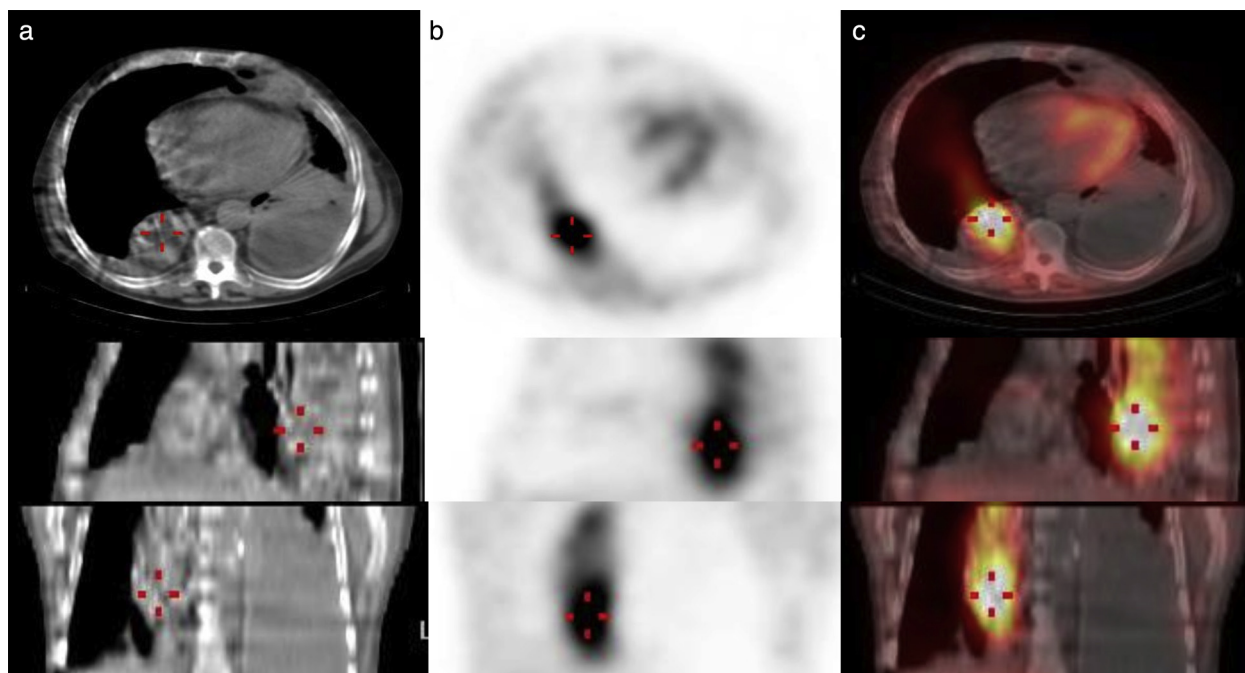
This finding led us to consider on a dilemma: Was related to esophageal cancer recurrence or was a complication due to the received treatment? To clarify the finding interpretation, a revision of clinical and surgical patient background was performed.  $^{18}\text{F}$ -FDG PET/CT at diagnosis, revealed the primary tumor in upper thoracic esophagus, without lymphadenopathy or distant metastasis (Fig. 3). Patient underwent surgery (esophagectomy, gastric tube reconstruction and esophago-gastric anastomosis), and one month before the MPI request, another  $^{18}\text{F}$ -FDG PET/CT was performed due to suspicion of relapse. The metabolic imaging confirmed locoregional and distant recurrence (Fig. 4), showing relapse in proximal

esophagus, while no significant increase in glucose metabolism was evident in the lower 2/3 of the gastroplasty (which showed increased activity in  $^{99m}\text{Tc}$ -tetrofosmin SPECT).

The comparison between SPECT/CT and PET/CT images (Fig. 5) showed that gastroplasty was dilated with liquid content, especially in distal region. Careful re-inspection of SPECT/CT determined that the increased activity corresponded to the content of the gastroplasty, so the findings were due to duodeno-gastro-esophageal reflux.

## Discussion

$^{99m}\text{Tc}$ -tetrofosmin is cleared from the blood and trapped into mitochondria, reflecting viable myocytes. Furthermore it has shown potential usefulness as tumor-imaging agent. Uptake in tumoral cells depends on the regional blood flow and cell membrane integrity, as well as mitochondrial density, which are increased in these cells. For that reason, many authors have explored the utility of  $^{99m}\text{Tc}$ -tetrofosmin in the diagnosis of



**Fig. 2.**  $^{99m}\text{Tc}$ -tetrofosmin SPECT (b) and fused SPECT/CT (c) slices reveal an elongated mass with increased activity in right-posterior mediastinum.

Download English Version:

<https://daneshyari.com/en/article/6129323>

Download Persian Version:

<https://daneshyari.com/article/6129323>

[Daneshyari.com](https://daneshyari.com)