




Disponible en ligne sur  
**SciVerse ScienceDirect**  
[www.sciencedirect.com](http://www.sciencedirect.com)

Elsevier Masson France  
**EM|consulte**  
[www.em-consulte.com](http://www.em-consulte.com)



Clinical case

## Uncal decompression in gliomatosis cerebri

### *Décompression de l'uncus dans la gliomatose cérébrale*

J. Pérez-Bovet\*, J. Rimbau Muñoz, S. Martín Ferrer

Neurosurgery Department, University Hospital Dr. Josep Trueta, Girona, Spain

#### ARTICLE INFO

##### Article history:

Received 1<sup>st</sup> November 2012

Accepted 25 February 2013

##### Keywords:

Gliomatosis cerebri  
 Temporal lobectomy  
 Decompressive surgery

##### Mots clés :

Gliomatose cérébrale  
 Lobectomie temporale  
 Chirurgie décompressive

#### ABSTRACT

Gliomatosis cerebri is defined as an infiltration, by an infiltrative glioma, of more than two cerebral lobes. Depending on response to treatment (chemotherapy and radiotherapy), clinical course may prolong over several months. Surgical excision has a very limited role in the management of this diagnosis. We present the case of a 48 year-old woman in whom a decompressive temporal lobectomy was performed in the context of a gliomatosis. Relief of intracranial hypertension allowed further treatment and a survival of 23 months. Relevant literature on the subject has been reviewed. There is the possibility of offering a decompressive lobectomy in selected cases of gliomatosis, allowing to undergo other treatment modalities.

© 2013 Elsevier Masson SAS. All rights reserved.

#### R É S U M É

Les gliomatoses cérébrales sont définies comme une infiltration, par un gliome infiltrant, de plus de deux lobes cérébraux. Dépendante de la réponse aux traitements (chimio- et radiothérapie), l'évolution peut être prolongée sur plusieurs mois. La chirurgie d'exérèse a très peu de place dans la prise en charge de ce type d'affections. Nous présentons le cas d'une femme de 48 ans chez laquelle a été réalisée une lobectomie temporale de décharge dans un contexte de gliomatose. L'amélioration de l'hypertension intracrânienne a été suffisamment satisfaisante pour mettre en place une chimiothérapie et obtenir une survie de 23 mois. Les principales données de la littérature ont été revues. Il est possible de proposer une lobectomie de décharge dans certains cas de gliomatose, permettant ainsi la mise en route des autres modalités thérapeutiques.

© 2013 Elsevier Masson SAS. Tous droits réservés.

## 1. Introduction

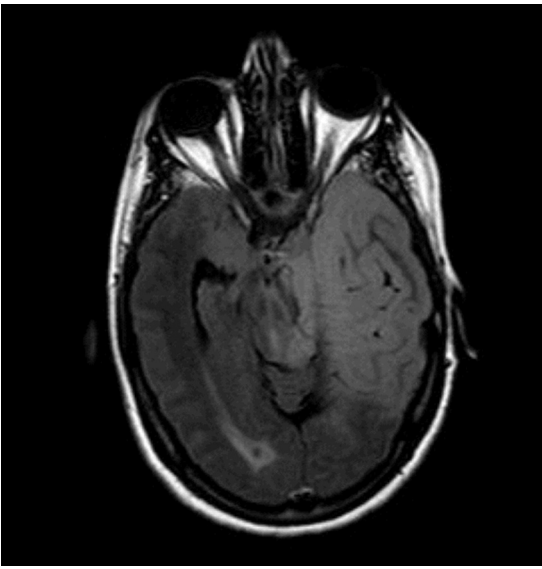
Gliomatosis cerebri (GC) is a diffuse glial neoplasm, usually astrocytic [1–3], defined by the presence of a continuous infiltrative disease in more than two cerebral lobes. Clinical course depends on initial and evolutive tumor grade, with 3 months of median time between initial symptoms and diagnosis, and months to 2 years of survival after diagnosis [4–7]. The World Health Organization (WHO) classifies GC as a grade III neoplasm [1]. Actual histology can correspond to that of grade II, III or IV glioma, thus influencing evolutive course and prognosis [6]. A tumor biopsy is required to obtain a histological diagnosis, but the extension of the neoplasm usually excludes surgical resection [6]. Current treatment is based on

radiotherapy and chemotherapy [4,6,7]. Surgery has been indicated only sporadically, although information regarding surgical treatment is limited to short and heterogeneous series. We present a case of GC with acute symptoms of raised intracranial pressure (ICP). Considering that rapid deterioration due to brain herniation was conditioning the prognosis, a decompressive surgery was performed.

## 2. Case report

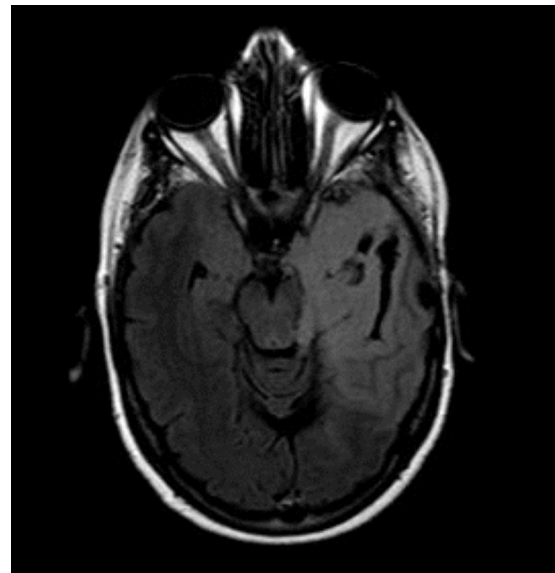
A 48-year-old, previously healthy woman presented at the emergency room for sudden loss of consciousness after a Valsalva maneuver. Her relatives reported that in the previous year, she had presented anorexia and a personality disorder that were considered to have a depressive, psychiatric etiology. On neurologic exploration, she had a Glasgow Coma Scale (GCS) 14 and presented right hemiparesis and multiple cranial nerve palsies, including

\* Corresponding author. Avinguda de França S/N, 17007, Girona, Spain.  
 E-mail address: [sgf.39@hotmail.com](mailto:sgf.39@hotmail.com) (J. Pérez-Bovet).



**Fig. 1.** Pre-operative MR, axial T1 sequence, infiltrative lesion affecting, on the left hemisphere, the temporal and parietal lobes, insula, amygdala, thalamus, hippocampus and parahippocampal gyrus; the anterior commissure and bilateral basal ganglia; on the right hemisphere, the basal fronto-temporal lobes, with mass effect on the uncus, brain stem, midline, ventricular system and Sylvian aqueduct.

*IRM préopératoire, séquence axiale en T1. Lésion infiltrante touchant, au niveau de l'hémisphère gauche, les lobes temporaux et pariétaux, l'insula, l'amygdale, le thalamus, l'hippocampe et le gyrus parahippocampique; la commissure antérieure et les noyaux gris centraux bilatéraux; et sur l'hémisphère droit, les lobes fronto-temporaux, avec effet de masse sur l'uncus, le tronc cérébral, la ligne médiane, le système ventriculaire et l'aqueduc de Sylvius.*



**Fig. 2.** Post-operative MR, axial T1 sequence, temporal lobectomy, improvement of the mass effect on the uncus and the brain stem.

*IRM postopératoire, séquence axiale en T1. Lobectomie temporale de décharge suivie d'une amélioration de l'effet de masse sur l'uncus et le tronc cérébral.*

facial asymmetry, anisocoria due to right midriasis, and persistent hiccups. Urgent CT and MR scans were performed, showing an infiltrative, non-contrast enhancement lesion affecting the left temporal and parietal lobes, the right frontal and temporal lobes, the left thalamus and hippocampus and the basal ganglia bilaterally. The left hemisphere lesion caused severe mass effect, as well as hydrocephalus (Fig. 1). The patient was monitored at the intensive care unit. Level of consciousness fluctuated and was strictly dependent of the administration of dexamethasone, mannitol and furosemide to maintain a GCS over 13. Episodes of severe decline in level of consciousness were accompanied by anisocoria, requiring the mentioned drugs for its reversal. In this setting, we considered that the relatively prolonged survival that is generally attributed to GC was hampered in the short term due to an acute deterioration. We believed that the patient could benefit from additional oncologic therapies and drastically improve outcome if the acute, life-threatening brain stem symptoms could be reversed. A decompressive surgery was therefore considered. Hippocampectomy was discarded to obviate neurological impairment in the context of a malignant neoplasm. Decompressive craniectomy was not considered to be an adequate procedure for neoplastic patients. A left temporal lobectomy was decided, with the intention to relieve the uncus and brain stem herniation. The surgical intervention was uneventful. The lobectomy was limited by the usual anatomic landmarks, and was performed through a fronto-temporal osteoplastic craniotomy. After the operation, level of consciousness was maintained on GCS 15, and the initial focal deficits slowly improved. Radiological follow-up with CT and MR showed a progressive, dramatic improvement of the herniations and mass effect previously described (Fig. 2). Histopathological analysis confirmed the diagnosis of GC, WHO grade II. The patient underwent radiation therapy, and survived for 23 months after diagnosis and surgical treatment.

### 3. Discussion

GC is, by definition, a diffuse neoplasm, affecting more than two cerebral lobes in a continuous manner. In that setting, surgical treatment is not considered an adequate treatment, and studies are based almost universally on response to chemotherapy and radiation therapy [4,6,8,9]. The relative rarity of the diagnosis, with about 300 cases reported in the literature, contributes to the scarcity of data [5]. Open or stereotactic biopsy can be considered part of the usual management of GC, but resective surgery has been very rarely indicated [6]. A systematic analysis of surgical treatment has never been performed. We have reviewed the available literature on surgical cases (Table 1). Most authors describe patients in which surgery was performed as part of the oncologic treatment. Only the reports by Kim et al., Fukushima et al. Tancredi et al., and Weinberg et al. describe cases in which surgery had an explicit decompressive objective [2,3,10,11].

To our knowledge, the issue of surgical treatment in GC has not been specifically addressed in other studies. Moreover, current literature on the subject shows a lack of consensus regarding clinical and radiological definition of the disease, complicating any analysis of treatment and outcome. Strict definition considers GC as a particular type of glial neoplasm, with the aforementioned biological behavior and radiological appearance. Some authors, however, consider that any progression of focal gliomas of any grade can be labelled as GC when they affect more than two cerebral lobes in a diffuse manner. In the most complete review on GC, Taillibert et al. acknowledged the need for restrictive diagnostic criteria and definition, and consider that the important variability in reported outcomes may be caused by the lack of homogenization in the diagnosis [5]. This review, however, does not provide information on surgical treatment.

GC can follow a relatively prolonged clinical course. Prognosis may be better in oligodendroglial histology, young age and male sex [5]. As a diffuse neoplasm with extensive brain infiltration, surgical removal is only sporadically performed. Even so, selected cases may benefit from surgical treatment. The patient we describe represents one such case. Surgical options in malignant neoplasms are influenced by ethical issues. Simple decompressive

Download English Version:

<https://daneshyari.com/en/article/6152602>

Download Persian Version:

<https://daneshyari.com/article/6152602>

[Daneshyari.com](https://daneshyari.com)