



Immune thrombocytopenia exacerbated by nivolumab in a patient with non-small-cell lung cancer

Stephen J. Bagley*, John A. Kosteva, Tracey L. Evans, Corey J. Langer

Abramson Cancer Center at the University of Pennsylvania, Perelman Center for Advanced Medicine, West Pavilion, 2nd Floor, 3400 Civic Center Boulevard, Philadelphia, PA 19104, United States of America

ARTICLE INFO

Article history:

Received 10 February 2016
Accepted 13 February 2016

Keywords:

Nivolumab
Non-small-cell-lung cancer
Programmed death 1
Immune thrombocytopenia
Immune-related adverse events

ABSTRACT

Introduction: Nivolumab is a programmed death 1 (PD-1) immune-checkpoint inhibitor antibody currently approved for second-line therapy of metastatic non-small-cell lung cancer (NSCLC). PD-1 inhibitors including nivolumab are associated with a unique spectrum of immune-related adverse events (irAEs), though hematologic irAEs are rare and have not been previously reported in patients with NSCLC.

Presentation of case: Here we report a patient who experienced an exacerbation of underlying immune thrombocytopenia (ITP) while receiving nivolumab for NSCLC. The patient's ITP was successfully managed with romiplostim during nivolumab therapy, allowing for 7 months of clinical benefit and a partial tumor response.

Discussion: Using this case as an example, we provide a brief review of irAEs associated with PD-1 blockade, with particular attention to hematologic events. We also describe our approach to the use of nivolumab in this patient with underlying autoimmune disease.

Conclusion: Patients with NSCLC and underlying autoimmune disease may experience a flare of the autoimmune condition while receiving immune checkpoint inhibition. As illustrated by this case of ITP exacerbated by nivolumab, careful management of the autoimmune disease may allow for the safe administration of PD-1 directed agents in these patients.

© 2016 Elsevier Ltd. All rights reserved.

1. Introduction

Nivolumab is a fully human monoclonal IgG4 antibody targeting programmed death-1 (PD-1), a co-inhibitory immune signal receptor expressed in T cells. Based on randomized phase III data demonstrating an overall survival benefit compared to docetaxel [1,2], nivolumab is now approved by the U.S Food and Drug Administration (FDA) for second-line therapy of metastatic non-small-cell lung cancer (NSCLC).

Immune checkpoint inhibition agents including nivolumab are associated with a unique spectrum of immune-related adverse events (irAEs), most of which are transient but can occasionally be severe or fatal. These have most commonly included dermatologic, gastrointestinal, hepatic, endocrine, and pulmonary inflammatory events, though other organ systems can also be affected. Hematologic irAEs are rare and have mostly been described in melanoma patients treated with ipilimumab [3–6]. Herein we report

the case of a NSCLC patient with immune thrombocytopenia (ITP) exacerbated by nivolumab.

2. Case report

A 32 year-old man with a 10 pack-year smoking history and a presumed diagnosis of primary ITP presented in December of 2013 with new atrial fibrillation and scant hemoptysis. A computed tomography (CT) scan of the chest demonstrated a 6.2 × 4.5 cm left para-mediastinal mass, and bronchoscopic biopsy of the mass revealed poorly differentiated squamous cell carcinoma. The patient subsequently underwent whole body positron emission tomography (PET) and magnetic resonance imaging (MRI) of the brain, which revealed cT2bNxM1b disease with a hypermetabolic left adrenal nodule and a lytic lesion in the right greater trochanter.

His platelet count was 123,000/μL upon presentation, similar to previous values since a complete blood count (CBC) was first obtained in 2011, three years prior to his diagnosis of NSCLC. There was no previous history of anemia or leukopenia, and prior blood smears had demonstrated scant giant platelets without other abnormalities. He never underwent a bone marrow biopsy, and there

* Correspondence to: Division of Hematology/Oncology, 3400 Civic Center Boulevard, Perelman Center, 7th Floor, South Pavilion Extension, Philadelphia, PA 19104, United States of America.

E-mail address: stephen.bagley@uphs.upenn.edu (S.J. Bagley).

were no other apparent causes for thrombocytopenia. He was presumed to have mild ITP and never required ITP-directed therapy or platelet transfusions.

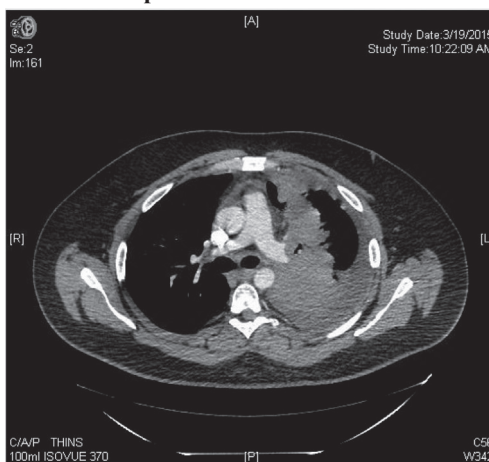Upon initial diagnosis of NSCLC, the patient received six cycles of carboplatin and paclitaxel, complicated by progressive thrombocytopenia with a nadir of 38,000/ μ L following the third cycle. His fourth cycle was subsequently delayed, as the platelet count did not improve despite four weeks off chemotherapy. He was treated with 2 mg/kg intravenous immunoglobulin (IVIG), with improvement of his platelet count from 38,000/ μ L to 148,000/ μ L over the course of three days. Cycles four through six of carboplatin/paclitaxel were administered with an IVIG infusion one day prior to the start of each cycle, and the platelet count remained stable between 90,000 and 100,000/ μ L. Scans after six cycles demonstrated a partial response in the primary lung mass and resolution of the lesion in the greater trochanter, but progression in the left adrenal metastasis. Given the patient's young age, excellent performance status, and oligometastatic disease, he underwent adrenal metastatectomy in July of 2014, followed by 6660 cGy of consolidation radiation to the residual lung mass concurrent with two cycles of cisplatin and etoposide. His platelet count was 122,000/ μ L prior to chemoradiation and decreased following the second cycle of chemotherapy to a nadir of 13,000/ μ L, for which he was transfused two units of platelets. He received corticosteroids as premedication with each of his chemotherapy infusions but was not retreated with IVIG. The platelet count recovered to 161,000/ μ L following completion of chemoradiation.

A subsequent PET/CT in January of 2015 demonstrated progressive metastatic disease in multiple locations, including mediastinal lymphadenopathy, a soft tissue nodule in the left adrenal surgical bed, and new osseous metastases in the left pubic ramus and the right ilium. He received two cycles of single agent docetaxel, and subsequent scans showed continued progression in the left lung mass, left pleura, and mediastinal lymph nodes. His platelet count remained stable between 192,000 and 223,000/ μ L during this therapy, though he received 8 mg of dexamethasone daily for three days as an anti-emetic with each cycle.

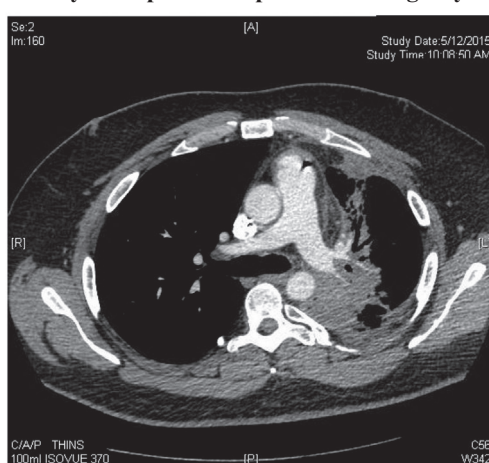
The patient was then switched to nivolumab 3 mg/kg every two weeks with a platelet count of 214,000/ μ L on day 1. Repeat imaging on day 47 demonstrated a partial response in all sites of disease (Fig. 1). On day 71, prior to his 6th infusion of nivolumab, his platelets had begun to decrease consistently with a count of 102,000/ μ L (Fig. 2). By his 8th infusion of nivolumab on day 99, his platelets had fallen further to 65,000/ μ L. Nivolumab was subsequently withheld, and his platelets continued to drop to a nadir of 33,000/ μ L on day 127. He had no bleeding or bruising and was essentially asymptomatic from his malignancy. A peripheral smear again demonstrated reduced platelets and scant giant platelets, and a CBC revealed a white blood cell count of 8000/ μ L and hemoglobin of 14.5 g/dL.

The patient was started on 1 mcg/kg romiplostim weekly beginning on day 127. Romiplostim is a recombinant thrombopoietin (TPO) receptor agonist approved by the FDA for the treatment of chronic ITP, with platelet response rates of 79–88 percent reported in randomized controlled trials [7]. As the platelet count did not improve over the following week, the dose was increased to 2 mcg/kg weekly on day 132. One week later his platelets improved to 188,000/ μ L. Nivolumab was resumed at that time, 41 days after his last nivolumab dose. Romiplostim dose intensity was modified to an every-other-week schedule starting on day 168 in an attempt to coincide with nivolumab infusions, but the platelet count subsequently dropped again on day 185 (Fig. 2). Romiplostim was increased to 3 mcg/kg and changed back to a weekly dosing schedule on day 185, and nivolumab therapy continued. The platelet count improved and his romiplostim dose intensity was again modified to every other week starting on day 199. His

A. Baseline: prior to nivolumab start



B. Day 47: a partial response following 4 cycles of nivolumab



C. Day 246: progression of left lung mass

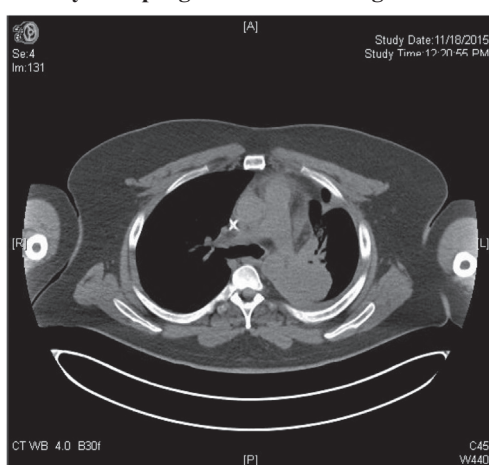


Fig. 1. CT scans demonstrating a partial response during therapy with nivolumab. Baseline: prior to nivolumab start Day 47: a partial response following 4 cycles of nivolumab Day 246: progression of left lung mass.

last romiplostim dose took place on day 227, as he ultimately developed a thrombocytosis (Fig. 2). Around this time, the patient complained of new right tibial pain. An MRI on day 192 revealed a focus of metastatic disease in the proximal right tibia. Of note, he required a brief course of dexamethasone from days 194 through 214 for additional pain control of his right tibial metastasis while undergoing radiation. A PET/CT on day 246 confirmed additional

Download English Version:

<https://daneshyari.com/en/article/6190223>

Download Persian Version:

<https://daneshyari.com/article/6190223>

[Daneshyari.com](https://daneshyari.com)