

Case Report

A late and extreme complication of lumboperitoneal shunt

Murat Vural, MD^{a,*}, Emre Özkara, MD^a, Baki Adapinar, MD^b, Emine DüNDAR, MD^c,
Ali Arslantaş, MD^a

^aDepartment of Neurosurgery, School of Medicine, Eskisehir Osmangazi University, Büyükdere Mh. Meşelik Kampüsü, 26480 Eskisehir-Turkey

^bDepartment of Radiology, School of Medicine, Eskisehir Osmangazi University, Büyükdere Mh. Meşelik Kampüsü, 26480 Eskisehir-Turkey

^cDepartment of Pathology, School of Medicine, Eskisehir Osmangazi University, Büyükdere Mh. Meşelik Kampüsü, 26480 Eskisehir-Turkey

Received 20 February 2014; revised 29 January 2015; accepted 6 February 2015

Abstract

BACKGROUND CONTEXT: Lumboperitoneal (LP) shunting is an effective treatment modality for communicating hydrocephalus, pseudotumor cerebri, postoperative pseudomeningoceles, and cerebrospinal fluid fistulas. However, LP shunts are associated with some complications. Here, we report an extreme complication resulting in the formation of granulation tissue.

PURPOSE: To report a late extreme complication of LP shunt.

STUDY DESIGN: A case report.

METHODS: A late and unusual complication of an LP shunt with unique radiologic findings is presented.

RESULTS: Spinal magnetic resonance imaging studies depicted a mass on the right anterior section of the dural sac encircling the catheter throughout its course from the L3–L4 interspinous level to the catheter tip.

CONCLUSIONS: The etiopathologic mechanism, the prolonged duration, and the unusual radiologic findings in this case are unique and remarkable. © 2015 Elsevier Inc. All rights reserved.

Keywords:

Lumboperitoneal shunt; Complication; Arachnoiditis; Granulation; Surgery; Malfunction

Introduction

Lumboperitoneal (LP) shunting is generally accepted to be an effective treatment modality for communicating hydrocephalus, pseudotumor cerebri, postoperative pseudomeningoceles, and cerebrospinal fluid fistulas [1–6]. Despite several advantages of LP shunts, such as low rates of infection, minimal rates of occurrence of serious intracranial hemorrhages, and no direct damage to brain tissue, their use has been restricted by associated complications that usually require revisions [4,7–9]. Commonly occurring

complications include obstruction, infection, over-drainage, tonsillar herniation, arachnoiditis, catheter migration, radiculopathy, and back pain [4,6,7,10,11]. Here, we report a late and unusual complication of an LP shunt. The patient presented with low back pain 20 years after the placement of the shunt; radiologic findings will also be discussed.

Materials and methods

Case report

A 32-year-old woman was admitted with a 2-year history of low back pain. The patient had undergone surgery to remove a posterior fossa astrocytoma in 1988. Shortly after this operation, an LP shunt was placed to treat a developing posterior fossa pseudomeningocele. She was followed-up as an outpatient for 2 years after her initial surgical intervention. For the subsequent 18 years there are no records of follow-ups and no additional clinical information was recorded until she reported the low back pain. This period without clinical monitoring could be referred to as the patient's "no complaints interval." A neurologic examination revealed no abnormality at the time of admission. A

FDA device/drug status: Not applicable.

Author disclosures: **MV:** Nothing to disclose. **EÖ:** Nothing to disclose.

BA: Nothing to disclose. **ED:** Nothing to disclose. **AA:** Nothing to disclose.

The manuscript submitted does not contain information about medical devices or drugs. No funds were received in support of this work. There were no relevant financial activities outside the submitted work.

* Corresponding author. Department of Neurosurgery, School of Medicine, Eskisehir Osmangazi University, Büyükdere Mh. Meşelik Kampüsü, 26480 Eskisehir, Turkey. Tel.: (90) 222-239-2979.

E-mail address: mvural@ogu.edu.tr (M. Vural)

lateral radiograph revealed an LP catheter, which entered the sac posteriorly, extending from the L3–L4 interspinous level to the L1 level (Fig. 1). Spinal magnetic resonance imaging studies depicted a mass on the right anterior section of the dural sac; the mass encircled the catheter throughout its course from the L3–L4 interspinous level to the catheter tip. At the level at which the catheter entered the dural sac, the subarachnoid space was completely obliterated. It was impossible to distinguish any adjacent roots or the dural sac from the mass; this finding was compatible with arachnoiditis. The mass was hypointense on both T1- and T2-weighted images and was enhanced heterogeneously and vividly after intravenous gadolinium administration (Figs. 2–5). A striking feature was that the mass was found to be enclosing the catheter tip, which may suggest the catheter malfunction. The patient rejected an offer of exploratory surgery and instead underwent an epidural analgesic procedure, which resulted in decreased but continuing pain. After this procedure, her complaints did not

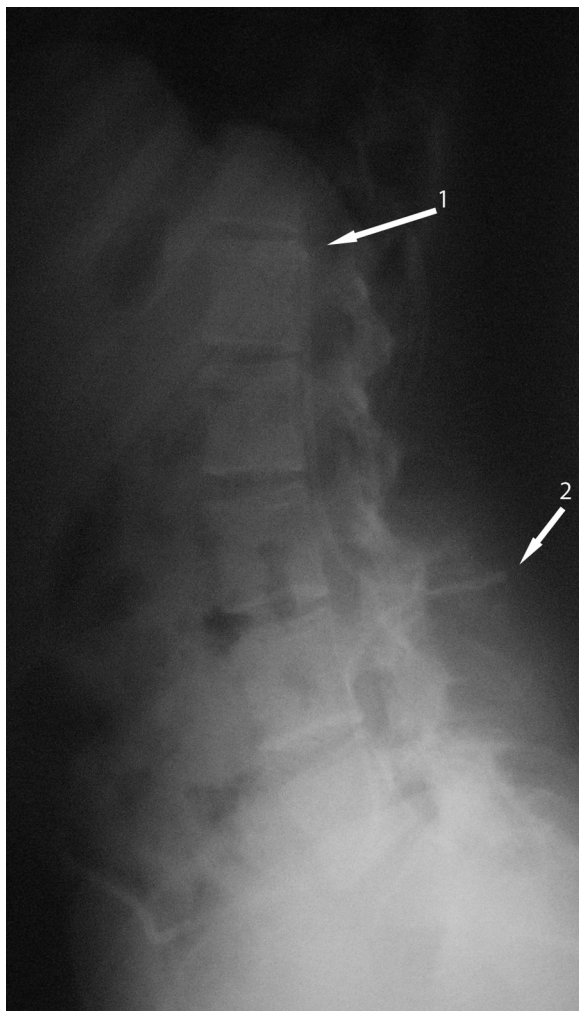


Fig. 1. A lumboperitoneal catheter entering the sac posteriorly and extending from the L3–L4 interspinous level (Arrow 2) to the L1 level (Arrow 1), as seen on an X-ray image.

decrease; thus, she chose to undergo exploratory surgery. The LP shunt was removed and the mass was resected only partially because of the extent to which it had infiltrated the surrounding tissues. Both biopsy material and the catheter were sent for histopathologic examination. The harvested catheter appeared to be made of silastic material, and the integrity of the device was preserved during inspection. No tissue samples encircling the device were detected histopathologically. Under polarized light, no polymeric wear particles were detected. A tissue sample was taken from the entry point at which the catheter had been inserted after performing a limited laminectomy at L3. A $0.5 \times 0.5 \times 0.4$ cm³ tissue sample was processed in one block. Pathologic examination revealed the lesion to be composed of granulation tissue (Figs. 6 and 7). All pre- and postoperative laboratory studies were within normal ranges. No potential source of infection was detected that could have been responsible for this complication.

Discussion

This report presents a rare case of an LP shunt complication resulting in arachnoiditis. Radicular pain and arachnoiditis are expected but relatively rare complications of LP shunts. Aoki [1] reported that after LP shunt placement, 5% patients develop radiculopathy; Wang et al. [6] reported three cases in a series of 74 patients. A retrospective study by Chumas et al. [7] of 143 patients noted that in pediatric patients who had undergone LP shunting, the incidence of back pain was 10%, the incidence of sciatica was 10%, and neurologic changes in the lower limbs were present in 6%.

Radiculopathy usually occurs shortly after LP shunt placement in approximately 1% to 10% of cases [1,6]. Aoki [1] suggested that radiculopathy occurs secondarily to compression of the nerve roots by mechanical impression of the catheter and that it is usually seen unilaterally. Furthermore, Solaroglu et al. [11] reported the intraforaminal migration of an LP shunt catheter that had caused radiculopathy.

The LP shunt catheter may also cause irritation and inflammatory responses resulting in arachnoiditis and granulomatosis. Granulomatosis is characterized by an aggregation of active macrophages, termed epithelioid cells. Although several cases of arachnoiditis resulting from the polyethylene material used in these systems have been reported in the literature, the introduction of silastic catheters has played an important role in reducing the chance of developing arachnoiditis [6,7,12].

In the present case, it is believed that the patient was asymptomatic for 18 years because arachnoiditis and the effects of the granulation mass on neural tissue developed very gradually. We suggest that prolonged irritation of the shunt catheter had led to a foreign-body reaction that resulted in chronic inflammation and the development of granulation tissue. Subsequently, the mass effect of the granulation tissue compressed neural tissue in the spinal

Download English Version:

<https://daneshyari.com/en/article/6212083>

Download Persian Version:

<https://daneshyari.com/article/6212083>

[Daneshyari.com](https://daneshyari.com)