



CASE REPORT

Traumatic asphyxia combined with diffuse axonal injury



Chi-Yi Lin*, Yu-Kun Chen, Chun-Hsiung Huang

Division of General Surgery, Department of Surgery, Armed Forces Taoyuan General Hospital, Taoyuan, Taiwan

Received 10 September 2014; received in revised form 29 December 2014; accepted 13 May 2015
Available online 19 August 2015

KEYWORDS

diffuse axonal injury;
magnetic resonance
imaging;
traumatic asphyxia

Abstract Traumatic asphyxia, a rare, blunt chest trauma-related condition, indicates severe injury and is characterized by subconjunctival hemorrhage, facial edema, cyanosis, and petechiae. This condition mostly appears on the upper chest and face. Rapid oxygen administration with effective ventilation is essential in the treatment of traumatic asphyxia. Prognosis depends on rescue time and associated injuries. Most neurologic symptoms resolve within 24–48 hours and have relatively satisfactory results over a long-term follow-up. We herein report the case of severe and complicated thoracoabdominal compression with a delayed change in consciousness. Susceptibility-weighted magnetic resonance imaging revealed diffuse axonal injury with multifocal microhemorrhages in the brain stem, basal ganglia, internal capsules, and the genu and splenium of the corpus callosum. The patient was in the intensive care unit for more than 21 days.

Copyright © 2015, Taiwan Surgical Association. Published by Elsevier Taiwan LLC. All rights reserved.

1. Introduction

Accidents resulting in blunt chest trauma incidences are increasingly common and can potentially result in death if

Conflicts of interest: The authors declare no conflicts of interest.

* Corresponding author. Department of Surgery, Armed Forces Taoyuan General Hospital, Number 168, Zhongxing Road, Longtan Township, Taoyuan Country 32551, Taiwan.

E-mail address: thanksthegod@gmail.com (C.-Y. Lin).

diagnosis is incorrect or if treatment is delayed. Traffic-related accidents are the most common causes of blunt chest trauma.^{1,2} Traumatic asphyxia, first mentioned by Ollivier in 1837,³ is a rare, blunt chest trauma-related condition and an indicator of severe injury, including subconjunctival hemorrhage, facial edema, cyanosis, and petechiae on the upper chest and face,⁴ with compression of the chest or upper abdomen being the causal factor. Associated injuries, such as pulmonary contusion, rib fractures, hemopneumothorax, diaphragmatic rupture, and myocardial injury, have also been described.^{2,4–6}

2. Case Report

A healthy 25-year-old Vietnamese man working at an electronics factory was involved in an accident while cleaning the factory conveyor belts. This resulted in the compression of his thorax and limbs. He was extricated from the machine and was conscious and alert. The Glasgow Coma Scale (GCS) score upon arrival to hospital was 15 (E4M6V5). His vital signs were as follows: blood pressure, 151/94 mmHg; heart rate, 167 beats/min; respiratory rate, 18 breaths/min; and body temperature, 36.6°C. Physical appearance was characterized by facial cyanosis with bilateral subconjunctival hemorrhage, multiple abrasive wounds from the left chest to the left arm, and deformity of the left upper arm and thigh (Figure 1). Chest X-ray revealed a fracture in the left ribs (third to eighth ribs to be precise) with bilateral pulmonary hemorrhages (Figure 2). Additional X-rays showed a midshaft left humerus fracture, a midshaft left femur fracture, and proximal left tibia and fibula fractures. Chest-to-pelvis computed tomography (CT) revealed multiple rib fractures, left hemothorax, right pneumothorax, and pulmonary contusion (Figure 3). After 20 minutes, a sudden decline of O₂ saturation from 98% to 88% was observed, and an endotracheal tube intubation with mechanical ventilator support was arranged. Tube thoracostomy was performed because of decreased respiration on the left side, and the patient was admitted to the intensive care unit. After 2 days, the patient developed a change in consciousness and underwent a follow-up brain CT. There was no obvious hemorrhage or ischemic change. An electrolyte level analysis revealed an elevated serum creatine kinase concentration. Massive hydration with 3 L of isotonic saline/d and mannitol was administered. Because no change in the GCS score was observed, brain magnetic resonance imaging (MRI) was performed and extensive microhemorrhaging in the brain stem, basal ganglia, internal capsules, and the genu and splenium of the corpus callosum was observed (Figure 4). Therefore, a diffuse axonal injury was diagnosed. The patient's consciousness progressively improved after approximately 27 days of hospitalization, and he was transferred to the ward.

3. Discussion

Traumatic asphyxia has characteristic pathophysiologic mechanisms, including elevation of thoracoabdominal

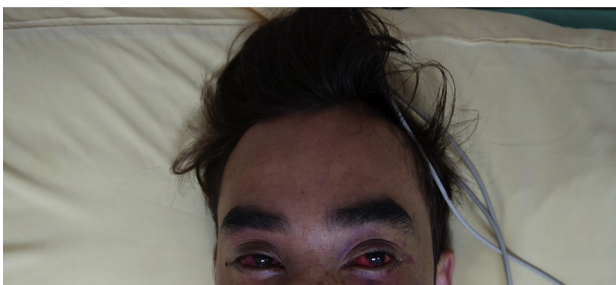

Figure 1 Patient with bilateral subconjunctival hemorrhage due to a crushing injury to the thorax.

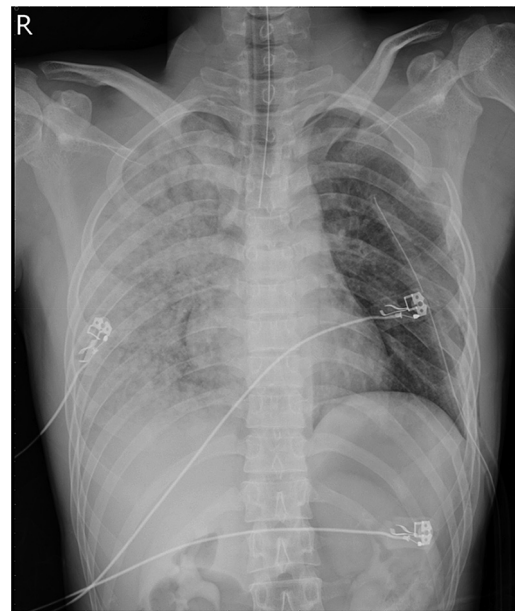


Figure 2 Chest radiography after tube thoracostomy was performed. Multiple rib fractures on the left side with bilateral pulmonary hemorrhages are clearly visible.

pressure with closure of the glottis and the airway (Figure 5).^{1,5,6}

Venous backflow and an increasing capillary pressure may cause inadequate tissue perfusion and capillary rupture. The most common clinical manifestations are craniocervical cyanosis, edema, and petechiae; in addition, neurologic symptoms are commonly associated with traumatic asphyxia and determine the patient outcome.⁵⁻⁷ Brain edema and central nervous system ischemia have been described in various cases. In 1992, Jongewaard et al⁸ reported 14 cases of sustained thoracic compression associated with varying degrees of neurologic symptoms, including loss of consciousness, brachial plexopathy, visual

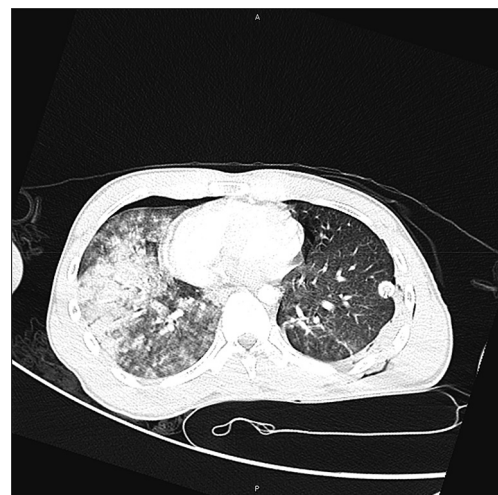

Figure 3 Computed tomography chest scan shows left hemothorax, right pneumothorax, and pulmonary contusion.

Download English Version:

<https://daneshyari.com/en/article/6250815>

Download Persian Version:

<https://daneshyari.com/article/6250815>

[Daneshyari.com](https://daneshyari.com)