



CASE REPORT

Advanced esthesioneuroblastoma with hyperostosis of the anterior skull base



Kuo-Feng Huang ^{a,b,*}, Tin-Chou Li ^a, Hsien-Ta Hsu ^a,
Hsing-Hong Chen ^a

^a Division of Neurosurgery, Department of Surgery, Taipei Tzu-Chi Hospital, Buddhist Tzu-Chi Medical Foundation, New Taipei City, Taiwan

^b School of Medicine, Tzu Chi University, Hualien, Taiwan

Received 23 April 2015; received in revised form 9 July 2015; accepted 3 August 2015

Available online 14 November 2015

KEYWORDS

anterior skull base;
craniotomy;
esthesioneuroblastoma;
hyperostosis;
olfactory
neuroblastoma

Abstract Esthesioneuroblastoma, also known as olfactory neuroblastoma, is a rare type of neuroectodermal tumor arising from the superior portion of the nasal cavity, sometimes locally invading the anterior skull base. We report the case of a 44-year-old man having a 3-year history of nasal obstruction and anosmia, acute worsening of vision in his right eye, and facial numbness on the right side. Brain computed tomography and magnetic resonance imaging revealed an extensively enhanced soft tissue tumor involving bilateral nasal and orbital cavities, ethmoid sinuses, the floor of the anterior cranial fossa, and intradural invasion. In particular, prominent hyperostosis, a rare associated radiological finding, was observed on both sides of the orbital roofs. Bifrontobasal craniotomy involving a radical removal of the soft tissue mass, including the intradural extension, was performed; the bilateral hyperostosis of the orbital roofs was drilled off for decompression of the narrowed orbital cavities. Pathological reports confirmed esthesioneuroblastoma. The postoperative course was smooth, and the vision improved. The tumor did not recur for 1 year after postoperative radiotherapy and adjuvant chemotherapy.

Copyright © 2015, Taiwan Surgical Association. Published by Elsevier Taiwan LLC. All rights reserved.

1. Introduction

Esthesioneuroblastoma (ENB), also known as olfactory neuroblastoma (ONB), is a rare type of neuroectodermal

tumor, generally originating in the specialized olfactory epithelium of the upper nasal cavity. It often invades the orbital space and anterior skull base.¹ Treatment strategy includes a wide range of surgical resection plus adjuvant

Conflicts of interest: All authors declare no conflicts of interest relevant to this article.

* Corresponding author. Division of Neurosurgery, Department of Surgery, Taipei Tzu Chi Hospital, Buddhist Tzu Chi Medical Foundation, 289 Jianguo Road, Xindian District, New Taipei City 23143, Taiwan.

E-mail address: kuofeng1234@gmail.com (K.-F. Huang).

<http://dx.doi.org/10.1016/j.fjs.2015.08.001>

1682-606X/Copyright © 2015, Taiwan Surgical Association. Published by Elsevier Taiwan LLC. All rights reserved.

postoperative radiotherapy and chemotherapy. The overall prognosis mainly depends on the histological grade and severity of the tumor invasion.²

Associated hyperostosis of the anterior skull base is extremely rare for patients with ENBs. Meningioma-associated hyperostosis is relatively common, generally localized, and proportional to the tumor size; the potential pathogenesis of tumor-associated hyperostosis was considered to include hypervascularity, noninvasive bone irritation, hormone-mediated osteoblast stimulation, tumor-induced bone formation, and direct tumor invasion.¹

Herein, we report a case of an advanced ENB with hyperostosis of the anterior skull base, in which the hyperostotic bone was maximally resected. In addition, we review relevant literature.

2. Case Report

A 44-year-old man having a 3-year history of nasal obstruction and anosmia experienced worsened vision in his right eye and right side facial numbness 1 year ago. The patient had no history of alcohol, tobacco, or drug use. A neurological examination revealed total anosmia, decreased right visual acuity (VA; right eye, light sense only; left eye, 1.0), impaired visual field (VF; generalized defect, right), proptosis of the right eye with moderately limited eyeball movement in all directions, and mild hypoesthesia in the right malar area. Cervical lymph nodes were not palpable, and blood tests revealed no abnormalities. Nasal endoscopy disclosed a large reddish tumor in the right middle meatus. Brain computed tomography (CT) and magnetic resonance imaging (MRI) revealed an extensively enhanced soft tissue tumor involving bilateral nasal and orbital cavities, ethmoid sinuses, the floor of the anterior cranial fossa, and intradural invasion. Beneath the intracranial skull base tumor growth, prominent hyperostosis was observed on both sides of the orbital roofs, particularly on the right side (Figure 1). The soft tissue tumor was removed from the nasal cavity by using an endonasal approach, and pathological reports confirmed ONB. A systemic survey revealed no distant metastasis, and bifrontobasal craniotomy was performed for radically removing the soft tissue mass, including intradural extension. Furthermore, the dural opening was repaired using a temporalis muscle fascia graft. The bilateral hyperostosis of the orbital roofs was drilled off to decompress the narrowed orbital cavities, and the frontal skull base was reconstructed using a pericranial flap. Pathological reports confirmed ENB (Figure 2). The postoperative course was uneventful, and the vision improved (VA, right: counting finger, 20 cm; left: 1.0; VF: partial central defect, right). After the operation, radiotherapy at a dose of 65 Gy and adjuvant cisplatin-based chemotherapy were administered according to the treatment guidelines. No tumor recurrence was observed after 1 year (Figure 3).

3. Discussion

ENB arises in the sinonasal tract and accounts for only ~3–6% of all intranasal tumors.² ENB particularly arises in the specialized olfactory epithelium lining the superior

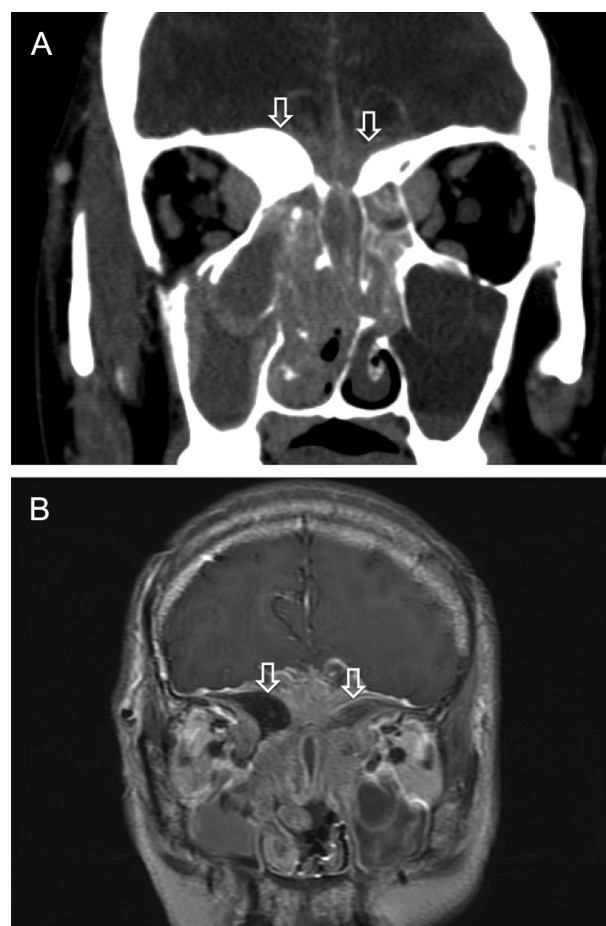


Figure 1 Preoperative coronal images of (A) the contrast brain computed tomography and (B) contrast-enhanced T1-weighted magnetic resonance imaging reveals an extensively enhanced soft tissue tumor involving the bilateral nasal and orbital cavities, ethmoid sinuses, the floor of the anterior cranial fossa, and the posterior part of the cribriform plate, with hyperostotic bones (arrows) at the anterior cranial fossa base.

portion of the upper nasal cavity. Because of its origin, this locally expansive malignant tumor typically invades the superomedial orbit, through the cribriform plate, and the anterior cranial fossa.

Bone invasion occurs because of osteolysis and is observed as a lytic image on CT.³ In extremely rare cases, ENB can cause osteoblastic modification at bone destruction sites and result in exuberant bone formation. Only four cases of hyperostotic ENB have been reported,^{1,4} with the first being the case by Regenboger et al.⁴

According to the Kadish staging system, tumors are divided into three groups: Group A lesions are confined to the nasal cavity, Group B lesions involve the nasal cavity and paranasal sinuses, and Group C lesions extend beyond the paranasal sinuses to the orbital and cranial cavities.³ The present case was classified as Kadish Stage C, which typically causes osteolysis of the anterior skull base and bone remodeling to some extent. Hyperostosis is a rare condition, and the abnormal bone was a noninvasive irritation of the bone as well as a true bony invasion by the

Download English Version:

<https://daneshyari.com/en/article/6250821>

Download Persian Version:

<https://daneshyari.com/article/6250821>

[Daneshyari.com](https://daneshyari.com)