



A case of bone fracture with callus on the right femur of a chicken (*Gallus gallus domesticus*, L. 1758) from the ancient site of Dharih, Jordan



Aurélia Borvon^{a,b,*}, Claude Guintard^{b,c}, Hervé Monchot^d

^a UMR 7041 Équipe Archéologie Environnementale, 21 allée de l'Université, 92000 Nanterre, France

^b Unité d'Anatomie Comparée, Département des Sciences Cliniques, École Nationale Vétérinaire, Agroalimentaire et de l'Alimentation, Nantes-Atlantique ONIRIS, route de Gachet, CS 40706, 44307 Nantes Cedex 03, France

^c Groupe d'Études Remodelage osseux et bioMatériaux (GEROM), Université d'Angers, Unité INSERM 922, LHEA/IRIS-IBS, 4 rue Larrey, CHU d'Angers, Angers, France

^d Labex Resmed, UMR 8167 Orient & Méditerranée, Sorbonne Universités, 1 place Victor Cousin, 75005 Paris, France

ARTICLE INFO

Keywords:

Archaeozoology
Fracture
Chicken
Pathology
Medical imaging
Umayyad period
Jordan

ABSTRACT

Archaeozoology provides bones, which quite regularly present traces of fractures. These fractures are more or less at an advanced level of healing and bear witness to traumas or pathologies. These cases of palaeopathology are not always the subject of publications, which further restricts our knowledge about them. This short note allows the scientific community to be aware of an original case from an archaeological context in Jordan of a fracture on a hen's femur, consolidated by a callus and with displacement of the distal ends. Beyond the "anecdotal" aspect, and without imagining the circumstances in which the fracture occurred, the animal survived.

1. Introduction

In archaeozoology, paleopathological studies have been carried out for about 40 years (Baker and Brothwell, 1980; Etier-Lafon, 1997; Bartosiewicz and Gál, 2013), and more specifically and recently on birds (Brothwell, 1993; Gál, 2008; Waldron, 2009). Until recently, few cases were published (Guintard, 2005) but works of the Animal Palaeopathology Working Group, an ICAZ (International Council for Archaeozoology) working group, fill this gap (<https://animalpalaeopathologywg.wordpress.com/>).

The femur which shows a pathological aspect presented here comes from the ancient sanctuary site of Dharih in Jordan (Fig. 1; Villeneuve and Al-Muheisen, 2000, 2008; Monchot and Béarez, 2016). It comes from a small bone assemblage corresponding probably to a small dump formed during Umayyad occupations of the site i.e. 7th-8th centuries AD. At that time the temple-church was converted by the new Muslim occupants into their residence, with its annexes as jars storeroom, stable and certainly a barnyard. This bone assemblage contains 121 remains including 57 chicken bones. The remainder is composed of 47 sheep/goat remains, 8 bones of non-identifiable teleosts and 8 indeterminate fragments.

The chicken bones seem to belong to two individuals, which appear to have been deposited more or less complete (Fig. 2). Although the right and left bones are fairly easily identifiable, it remains difficult to reassign the different parts to their respective original animals. The absence of spurs on the tarsometatarsus indicates the presence of females (West, 1982; Carey, 1982; Bökönyi and Bartosiewicz, 1983; Coy, 1983; Benecke, 1989, 1993; Clavel et al., 1997; Serjeantson, 2009, pp. 47–49; Borvon, 2012, pp. 228–234). The existence of medullary bone - necessary for the manufacture of the eggshell - within the diaphysis of a fractured humerus indicates the presence of an individual during the laying period (Rick, 1975; Driver, 1982; Coy, 1983; Serjeantson, 1998, 2009, pp. 49–53; Van Neer et al., 2002; Borvon, 2012, pp. 235–241).

2. Methods

The right femur presented in this study was the subject of an osteological description in order to document the bone anomaly present in its diaphysis. At the same time, medical imaging analyses were carried out by the ONIRIS Imaging Department for radiography and scanning. A non-pathological femur from the same archaeological site served as a reference.

* Corresponding author at: UMR 7041 Équipe Archéologies Environnementales, 21 allée de l'Université, 92000 Nanterre, France.

E-mail addresses: aureliaborvon@gmail.com (A. Borvon), claud.guintard@oniris-nantes.fr (C. Guintard), herve.monchot@wanadoo.fr (H. Monchot).

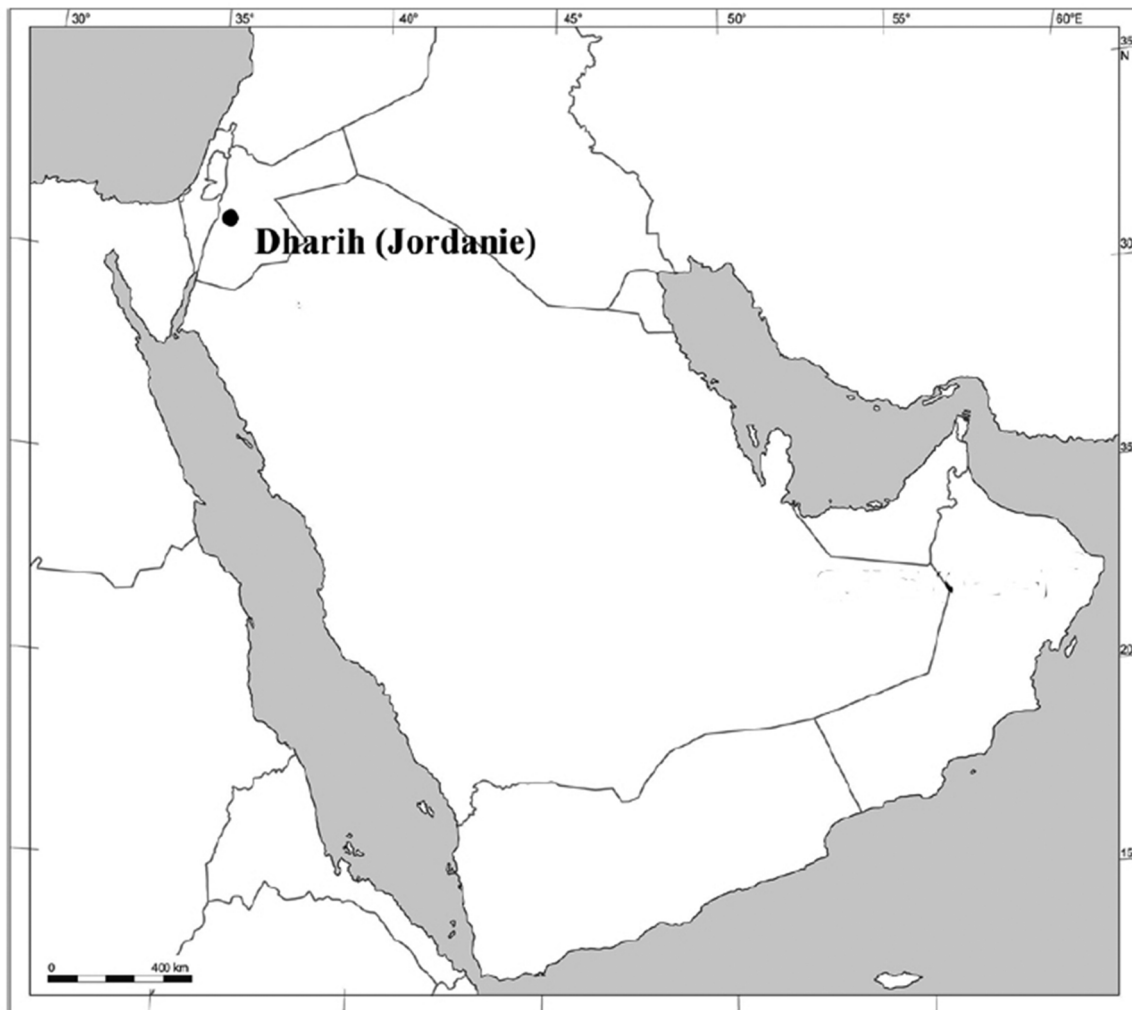


Fig. 1. Location of the archaeological site of Dharrah, Jordan (© DAO H. Monchot and M. Coutureau).

3. Results

The femur shows a significant bone callus, on the proximal half of the bone diaphysis (Fig. 3). The two osseous ends of this diaphysis are displaced. This is particularly noticeable on the imaging pictures (Figs. 4 and 5). These deformations are consecutive to a fracture. The X-ray picture (Fig. 5) shows that the right femur presents a compact, diaphyseal substance that appears to be thickened. This thickening is due to the presence of medullary bones necessary for the manufacture of the eggshells during the laying period (Whitehead, 2004b). A verification slot confirmed this assumption. In the case of the pathological femur, the abnormal aspect of the bone structure at the diaphysis is not related to the presence of medullary bones. The bone has a trabecular aspect, almost spongy and similar to that observed in the consolidation callus. The modification of the bone microarchitecture is related to the absence of mechanical stresses (Aguado, 2015; Aguado et al., 2017; Libouban, 2015; Whitehead, 2004a; Whitehead and Fleming, 2000) induced by loss of support due to pain and a change in vascularization, the phenomenon of bone healing.

4. Discussion and conclusion

The study of bones from archaeological sites provides pathological cases in many assemblages. Rare in general, it is very often fractures more or less consolidated which testify traumas (Wood, 1941; Waldron, 2009). A few cases are thus recorded in the rare synthetic articles dedicated to this subject (Brothwell, 1993; Gál, 2008). The description presented here of a fractured femur with bone callus and displacement of the two parts of the bone, is quite similar to the case reported for example in Hungary at the Kiskundorozsma site for the Avar period (Gál, 2008, Fig. 4, p. 44). Despite the fact that the bird femur is a bone largely protected by a significant muscle mass, it is not unusual that this bone is the object of fracture with consolidation (Atherton et al., 2012). The voluminous and powerful muscles (Ghete et al., 1981) systematically cause a displacement of the osseous parts and concomitantly a reduction of the long length of the bone. The consecutive bone callus consolidates the healing so that the animal resumes normal activity.

In Dharrah, all archaeological levels combined, 461 bone remains and 49 eggshell fragments, belonging to dozens of chickens, have been

Download English Version:

<https://daneshyari.com/en/article/6554750>

Download Persian Version:

<https://daneshyari.com/article/6554750>

[Daneshyari.com](https://daneshyari.com)