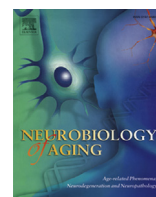




Contents lists available at ScienceDirect

## Neurobiology of Aging

journal homepage: [www.elsevier.com/locate/neuaging](http://www.elsevier.com/locate/neuaging)

## Psychotic Alzheimer's disease is associated with gender-specific tau phosphorylation abnormalities

Jeremy Koppel<sup>a,b,\*</sup>, Chris Acker<sup>a</sup>, Peter Davies<sup>a</sup>, Oscar L. Lopez<sup>c,d</sup>, Heidy Jimenez<sup>a</sup>, Miriam Azose<sup>e</sup>, Blaine S. Greenwald<sup>b</sup>, Patrick S. Murray<sup>c,d</sup>, Caitlin M. Kirkwood<sup>c,d</sup>, Julia Kofler<sup>c,d</sup>, Robert A. Sweet<sup>a,c,d,f</sup>

<sup>a</sup>The Litwin-Zucker Research Center for the Study of Alzheimer's Disease, The Feinstein Institute for Medical Research, Manhasset, NY, USA

<sup>b</sup>The Zucker Hillside Hospital, The North-Shore LIJ Health System, Glen Oaks, NY, USA

<sup>c</sup>Department of Psychiatry, University of Pittsburgh, Pittsburgh, PA, USA

<sup>d</sup>Department of Neurology, University of Pittsburgh, Pittsburgh, PA, USA

<sup>e</sup>Touro College, Brooklyn, NY, USA

<sup>f</sup>VISN Q2 4 Mental Illness Research, Education and Clinical Center (MIRECC), VA Pittsburgh Healthcare System, Pittsburgh, PA, USA

## ARTICLE INFO

## Article history:

Received 23 December 2013

Received in revised form 26 February 2014

Accepted 3 March 2014

## Keywords:

Alzheimer's disease

Psychosis

Tau

Dementia with Lewy bodies

Alpha-synuclein

Neurofibrillary tangles

## ABSTRACT

Converging evidence suggests that psychotic Alzheimer's disease (AD + P) is associated with an acceleration of frontal degeneration, with tau pathology playing a primary role. Previous histopathologic and biomarker studies have specifically implicated tau pathology in this condition. To precisely quantify tau abnormalities in the frontal cortex in AD + P, we used a sensitive biochemical assay of total tau and 4 epitopes of phospho-tau relevant in AD pathology in a postmortem sample of AD + P and AD – P. Samples of superior frontal gyrus from 26 AD subjects without psychosis and 45 AD + P subjects with psychosis were analyzed. Results of enzyme-linked immunosorbent assay demonstrate that AD + P females, but not males, had significantly higher levels of phosphorylated tau in the frontal cortex. In males, but not females, AD + P was associated with the presence of  $\alpha$ -synuclein pathology. These results support a gender dissociation of pathology in AD + P. The design of future studies aimed at the elucidation of cognitive and/or functional outcomes; regional brain metabolic deficits; or genetic correlates of AD + P should take gender into consideration.

© 2014 Elsevier Inc. All rights reserved.

## 1. Introduction

Evidence garnered from genetic (Hollingsworth et al., 2007; Sweet et al., 2002, 2010) longitudinal (below), and imaging (below) studies of Alzheimer's disease (AD) complicated by a psychotic course (AD + P) support its syndromal distinction from its nonpsychotic counterpart (AD – P); very recent work on the neurobiology of the disorder point toward frontal systems deficits and an overrepresentation of one of the pathologic protein hallmarks of the disease as potentially etiologically related to the development of psychosis. The identification of a specific neuropathological etiology of psychosis could pave the way to new treatment approaches for a condition that currently relies on the use of antipsychotic medication that have been reported to contribute to an exacerbation of cognitive impairment (Schneider

et al., 2006; Vigen et al., 2011) and that carry a “black box warning” for use in the elderly with AD (FDA, 2005).

Converging evidence suggests that AD + P may represent a relative acceleration of frontal pathology, with tau pathology playing a primary role. AD + P can be distinguished from AD – P in its association with a greater burden of cognitive impairment and a more rapid cognitive decline, as concluded by a review of 55 studies of AD + P (Ropacki and Jeste, 2005). This association has subsequently been confirmed in more recent studies (Sweet et al., 2010, 2012; Wilkosz et al., 2010); the decline has consistently been found to predate the onset of psychosis, suggesting a pathologic process that finds expression in both deterioration and psychosis (Emanuel et al., 2011; Paulsen et al., 2000; Weamer et al., 2009). The contribution of neurodegenerative pathology to the psychotic course of AD is suggested by a hastened mortality (Lopez et al., 2013; Scarmeas et al., 2005; Wilson et al., 2005). The constellation of aggravated cognitive deficits in AD + P suggests disruption of frontal systems (Jeste et al., 1992; Paulsen et al., 2000) with working memory tasks particularly affected. (Koppel et al., 2012, 2013c; Murray et al., 2013a) Computer-assisted tomography, magnetic resonance imaging, single-photon

\* Corresponding author at: The Litwin-Zucker Research Center for the Study of Alzheimer's Disease, The Zucker Hillside Hospital, 350 Community Drive, Manhasset, NY 11030, USA. Tel.: +1 516 562 3492; fax: +1 516 562 0401.

E-mail address: [jkoppel@nshs.edu](mailto:jkoppel@nshs.edu) (J. Koppel).

**Table 1**  
Demographics of AD subjects with psychosis (AD + P, N = 45) and without psychosis (AD – P, N = 26). Means (SEM) shown

	AD + P	AD – P
Total sample		
Male	22	13
Female	23	13
Age	82.9 (1.0)	83.4 (1.8)
Braak	4.9 (0.1)	4.9 (0.2)
Females		
Age	83.5 (1.3)	87 (2.4)
Braak	5.1 (0.1)	4.6 (0.3)
Males		
Age	82.2 (0.7)	79.9 (2.4)
Braak	4.7 (0.2)	5.1 (0.2)

Key: AD, Alzheimer's disease; P, psychosis.

emission computed tomography, and [<sup>18</sup>F]-fluorodexyglucose positron emission tomography studies of AD + P also consistently but not exclusively implicate frontal systems (Murray et al., 2013b).

A number of reports suggest that tau may be a unique contributor to the putative neurodegenerative process in AD + P. Neurofibrillary tangles (NFTs) are one of the pathologic hallmarks of AD whose distribution correlates with the severity of disease (Arriagada et al., 1992). Tau is abnormally phosphorylated in AD, a critical event leading to abnormal folding and cleavage with aggregation of the protein and the eventual development of NFT pathology (Goedert, 1993; Mondragon-Rodriguez et al., 2008). Tau is hyperphosphorylated in AD at 19 specific amino acid sequences, with evidence indicating that phosphorylation at particular sites correlate with the maturity of pathology and that individual sites may be critical for conformational changes from pre-tangles leading to neuronal tangles to eventual extracellular tangles. (Augustinack et al., 2002; Kimura et al., 1996) Previous studies have reported an increased burden of NFT pathology in frontal cortex in AD + P, although these studies have relied on semi-quantitative transformation of histochemical detection of fibrillar tau. (Farber et al., 2000; Zubenko et al., 1991) A recent neuropathological correlation study of pre-frontal cortical sections from a postmortem AD + P sample used quantitative fluorescence microscopy and observed an increased burden of intraneuronal tau phosphorylated at Ser199/Ser202/Thr205 (Murray et al., 2013a). In a study conducted on a data sample drawn from the Alzheimer's Disease Neuroimaging Initiative, cerebrospinal fluid (CSF) biomarkers of AD (total tau, Thr181 phospho-tau, and amyloid-beta [Aβ]) were explored as predictors of the development of psychosis. Elevation of total tau was associated with the future development of AD + P (Koppel et al., 2013a). An association of CSF total and Thr181 phospho-tau with gender was also observed when the genders were separated; females but not males with subsequent development of AD + P manifested baseline elevations of Thr181 phospho-tau and total tau.

No previous studies have used a biochemical approach to precisely quantify concentrations of pathogenic tau in brains of those with AD + P, or explored whether particular tau phosphorylation sites predominate in AD + P that could distinguish it from AD – P. To quantify tau abnormalities in the frontal cortex in AD + P across a range of phosphorylation sites, and to explore the impact of gender on those abnormalities, we used a sensitive biochemical assay of 4 epitopes of phospho-tau (Ser396/404; Ser202; Thr231; Ser199/202/Thr205) using monoclonal antibodies known to recognize a wide range of tau pathology in a postmortem sample of AD + P and AD – P.

## 2. Methods

All subjects (Table 1) underwent neurologic, neuropsychologic, and psychiatric diagnostic evaluations as part of their participation

in the Clinical Core of the Alzheimer Disease Research Center (ADRC) at the University of Pittsburgh. (Murray et al., 2013b; Sweet et al., 2000, 2001) Psychiatrists with specialized training in geriatric psychiatry conducted semi-structured examinations, and the patient, primary caregiver, and all other available informants were interviewed. As part of the semi-structured examinations, the presence or absence of hallucinations and delusions was determined and rated on the Consortium to Establish a Registry for Alzheimer's disease (CERAD) Behavioral Rating Scale (Tariot et al., 1995). Hallucinations were defined as sensory perceptions with no basis in reality. Delusions were defined as a false belief based on incorrect inference about reality and not attributable to membership in a social or cultural group. Psychosis was the presence of hallucinations or delusions at any visit. Subjects with psychosis occurring solely during an episode of delirium were not rated as AD + P. No patient had a history of schizophrenia, schizoaffective disorder, or other idiopathic psychosis. Years of death ranged between 2000 and 2011.

A neuropathologic diagnosis of AD was made at postmortem examination (Mirra et al., 1991). At the time of brain removal, the postmortem interval in hours was recorded, and the brain was removed intact, examined grossly, and divided in the midsagittal plane. Gray matter samples from the right superior frontal gyrus were dissected and frozen at –80 °C. The left hemisphere was immersion fixed in 10% buffered formalin for at least 1 week, sectioned into 1.0–2.0 cm coronal slabs, and sampled according to CERAD protocol for neuropathological diagnosis (Mirra et al., 1991). Samples from the midfrontal cortex, cingulate gyrus, and caudate nucleus, hippocampus at the level of the lateral geniculate nucleus, inferior parietal lobule, superior and middle temporal cortex, primary visual cortex, amygdala, and transentorhinal cortex were stained using the Bielschowsky technique according to the Yamamoto and Hirano modification (Yamamoto and Hirano, 1986). Samples from amygdala, midbrain, pons, and medulla were immunostained for ubiquitin and  $\alpha$ -synuclein and Lewy body pathology was rated (McKeith et al., 1996). If any of these sections were positive, sections from cortex, hippocampus, and remaining brainstem were also stained for  $\alpha$ -synuclein. Neuritic plaques were semiquantitatively scored according to CERAD criteria; (Mirra et al., 1991) plaque density per 100 $\times$  microscopy field was rated as “none,” “sparse,” “moderate,” or “frequent,” with most subjects scored as “frequent.” Braak staging was done on Bielschowsky stained sections of mesial temporal lobe (hippocampus with entorhinal, transentorhinal and inferior temporal lobe cortex), mid-frontal, inferior parietal, superior temporal gyri, and occipital lobe containing the primary visual cortex and adjacent cortex (Braak and Braak, 1991).

### 2.1. Brain sample preparations and/or tau sandwich enzyme-linked immunosorbent assay

Previous studies have suggested that accelerated frontal neurodegeneration may be a feature of the pathogenic process in psychotic AD (Koppel et al., 2013c; Murray et al., 2013a). For this reason, the present study focused on the frontal cortex. Brain samples of superior frontal gyrus drawn from 26 AD – P subjects and 45 AD + P subjects. There were 35 males and 36 females included in the study. AD + P and AD – P groups were well balanced for gender, age at death, and postmortem Braak staging (Table 1). The Braak staging system (I–VI) is based on the gradual appearance of neurofibrillary tangle pathology in a hierarchical pattern beginning in the perirhinal cortex (stage I) in preclinical disease and eventually appearing to all areas of association cortex in severe disease (stage VI) (Braak and Braak, 1995). The approximate equivalence of Braak stage between AD + P and AD – P sample

Download English Version:

<https://daneshyari.com/en/article/6805591>

Download Persian Version:

<https://daneshyari.com/article/6805591>

[Daneshyari.com](https://daneshyari.com)