

# Anterior Glottic Web Formation for Voice Feminization: Experience of 27 Patients

Taner Yılmaz, Oğuz Kuşçu, Tefrik Sözen, and Ahmet Emre Süslü, Ankara, Turkey

**Summary: Objective.** Voice feminization is needed for male-to-female transsexuals, males with testicular feminization, and females with constitutional androphonia. Anterior glottic web formation affords advantages: endoscopic surgery without skin incision and scar, outpatient surgery, potential reversibility, and low risk for vocal fold and airway damage.

**Study Design.** This is a nonrandomized prospective cohort study.

**Setting.** University hospital.

**Materials and Methods.** All 27 cases of androphonia were treated with endoscopic anterior glottic web formation. Voice Handicap Index (VHI-30); acoustic analysis with /a/ including  $F_0$ , jitter, shimmer, noise-to-harmonic ratio; and acoustic analysis of connected speech for speaking  $F_0$  were determined pre- and postoperatively. Patients and medical students rated pre- and postoperative voices as feminine, masculine, or neither.

**Results.** The pre- and postoperative mean total VHI scores of patients were 38 and 24, respectively; this difference was statistically significant ( $P < 0.001$ ). Their pre- and postoperative mean  $F_0$  and speaking  $F_0$  were 152 and 158 and 195 and 200 Hz, respectively; these differences were statistically significant ( $P < 0.001$ ). Their pre- and postoperative acoustic analysis results were not significantly different ( $P > 0.05$ ). Seven patients (26%) needed laser reduction glottoplasty for voice feminization because they were not satisfied with the voice result. Patients' self-evaluations of their postoperative voice revealed 20 feminine, 2 masculine, and 5 neither results, giving a rise to patient satisfaction rate of 74%. Medical students rated 85% of postoperative voice samples as feminine, giving rise to overall success rate of 85%.

**Conclusion.** Anterior commissure web formation is a successful surgical option for voice feminization. However, additional surgery may be necessary for patient satisfaction.

**Key Words:** Voice–Feminization–Vocal cords–Transsexualism–Transgender persons.

## INTRODUCTION

Male-to-female transsexuals (MFTs), males with testicular feminization who were raised as females, and females with constitutional androphonia seek medical help for their low-frequency male voice. Males with testicular feminization are genotypically XY patients with female secondary sexual characteristics because of complete or partial androgen insensitivity. Patients with partial androgen insensitivity have ambiguous genitalia and testes; these patients attain male voice characteristics before their gonads are removed to be raised as females. Constitutional androphonia is seen in normal females without any apparent androgen source; some of these ladies may have polycystic ovarian syndrome.

There are multiple treatment options for voice feminization. Most of these options are surgical treatments. Voice therapy is the only nonsurgical choice. Cricothyroid approximation,<sup>1</sup> anterior commissure advancement,<sup>2,3</sup> and feminization laryngoplasty<sup>4</sup> are external surgical procedures; therefore, they result in skin

incision and scar. On the other hand, anterior glottic web formation<sup>5</sup> and laser reduction glottoplasty<sup>6,7</sup> are endoscopic procedures that do not result in skin incision. All of these surgeries produce a feminine voice with potential advantages and disadvantages. A voice surgeon needs to have multiple surgical options for voice feminization in his armamentarium, because many, but not all, patients are not satisfied with the postoperative voice result and ask for a more feminine voice.

An ideal surgical procedure for raising vocal pitch should be reliable, with little or no morbidity, and permit the individual to use a normal intent and effort when speaking with an  $F_0$  higher than 165 Hz to be perceived as female.<sup>8</sup> However, our experience shows that speaking with  $F_0 = 165$  Hz is usually not enough and a higher  $F_0$  is necessary to be perceived as feminine.

The authors would like to present their endoscopic anterior glottic web formation technique for voice feminization and their experience on 27 patients, and discuss the potential advantages and disadvantages of this surgical procedure.

## MATERIALS AND METHODS

This study was approved by the institutional ethics committee of our university (number GO 15/710). The study was performed in accordance with the ethical standards as laid down in the 1964 Declaration of Helsinki and its later amendments or comparable ethical standards. Informed consent was obtained from all individual participants included in the study.

This is a nonrandomized prospective cohort study, performed at a tertiary referral center, which is a university hospital. All 27 consecutive cases of androphonia, who applied to our

Accepted for publication March 13, 2017.

Financial Disclosure: The study was financially supported by a Hacettepe University Research Fund.

Conflict of interest: None.

This paper was presented on podium at the ALA section of COSM, May 18–22, 2016, Chicago, IL, USA.

From the Department of Otolaryngology-Head & Neck Surgery, Hacettepe University Faculty of Medicine, Ankara, Turkey.

Address correspondence and reprint requests to Taner Yılmaz, Department of Otolaryngology-Head & Neck Surgery, Hacettepe University Faculty of Medicine, 06100 Sıhhiye, Ankara, Turkey. E-mail: [tyilmaz@hacettepe.edu.tr](mailto:tyilmaz@hacettepe.edu.tr)

Journal of Voice, Vol. ■■, No. ■■, pp. ■■-■■

0892-1997

© 2017 The Voice Foundation. Published by Elsevier Inc. All rights reserved.

<http://dx.doi.org/10.1016/j.jvoice.2017.03.006>

department between 2010 and 2015, were treated with endoscopic anterior glottic web formation and followed for at least 1 year postoperatively. All of the patients lived far away from the city where our hospital was located, so they were unable to attend voice therapy sessions; that is why voice therapy option was not used.

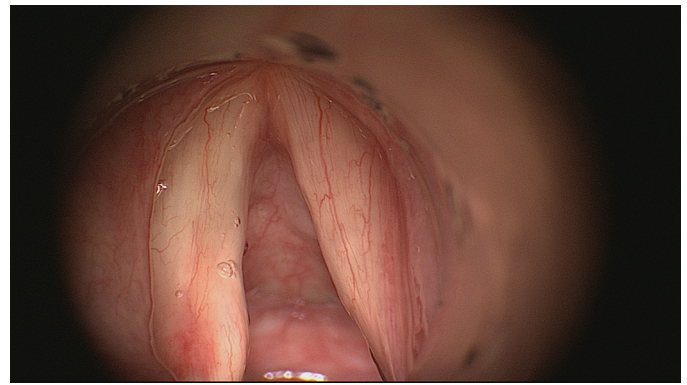
Twenty-one patients were male-to-female transsexuals, three were males with testicular feminization, and three were females with constitutional androphonia. Their ages ranged between 14 and 50, with a mean of 29 and standard deviation of 8.1. None of the patients received pre- or postoperative voice therapy. All patients underwent preoperative psychological evaluation before undergoing surgery. They all had stable psychological condition.

Voice Handicap Index (VHI-30), including physical, functional, emotional, and total scores, was performed preoperatively and 1 year postoperatively on all patients.

Acoustic analysis with /a/ at comfortable pitch and loudness using Computerized Speech Lab Model 4300B (Kay Elemetrics, Lincoln Park, NJ, USA) including  $F_0$  (Hz), jitter (%), shimmer percent (Shim) (%), noise-to-harmonic ratio (NHR), and speaking  $F_0$  using Analysis of Dysphonia in Speech and Voice was performed preoperatively and 1 year postoperatively on all patients.

### Surgical technique (Video S1)

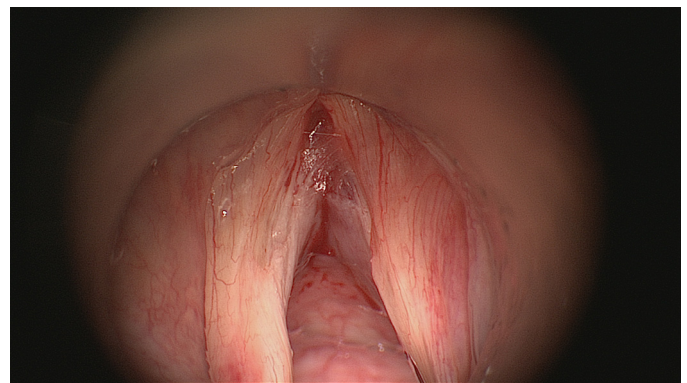
The operations were performed by a senior author (TY) under general anesthesia with endotracheal intubation. Size B or C Kleinsasser laryngoscope (Storz, Tübingen, Germany) was inserted into the patient's larynx and suspended. Anterior commissure must be visualized during microlaryngoscopy; therefore, when necessary, anterior pressure was applied to larynx with adhesive tapes, the ends of which were fixed to operation table. The vocal folds were examined under appropriate magnification with microscope and were palpated with blunt instruments to determine any vocal fold lesion missed during videolaryngostroboscopic examination. Nothing was injected to the vocal folds for hemostasis before surgery. The anterior half of membranous vocal folds was determined. The mucosa of the posterior end of the anterior half of membranous vocal fold was grasped with microlaryngeal forceps and pulled medially. With appropriate microscissors, this mucosa was stripped from the free border of vocal fold toward anterior commissure. The same stripping was repeated on the opposite side. The stripped vocal fold mucosa was removed from anterior commissure with microscissors. Epinephrine was applied with cotton-tipped applicator to the surgical wound for hemostasis. To form anterior glottic web, the denuded vocal folds were sutured to each other. Suturing started at the anterior commissure. The most-difficult-to-perform suture was the one at the anterior commissure; suturing became easier as the surgeon moved posteriorly. Two nonlocking microlaryngeal straight forceps and a knot pusher were utilized during suturing. 5/0 vicryl suture with 11-mm-long, reverse-cutting, curved needle with at least 45 cm thread length was used. The needle was first passed through the right vocal fold from inferior surface to superior surface; then the needle pierced the left vocal fold from superior to inferior surface. The suture was tied to place a single knot subglottically. Usually three to four sutures, sometimes five sutures, were used to bring denuded vocal



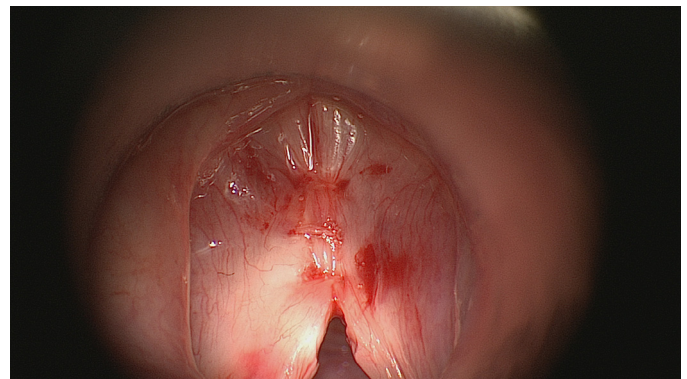
**FIGURE 1.** Endoscopic view of glottis before starting web surgery.

folds together and to create anterior glottic web<sup>9,10</sup> (Figures 1–3). Tissue adhesives have never been used. There were 2.5 units of botulinum toxin A injected to each vocalis muscle to ensure involuntary voice rest. Patients were advised postoperative complete voice rest for 7 days. Postoperative medication was not given.

The patients were asked to rate their postoperative voice as feminine, masculine, or neither. The pre- and postoperative connected speech samples of patients were mixed stored randomly in a voice file and played in the class of 25 fifth year medical students who never had any education about voice evaluation; they were asked to rate the patients' voices as feminine, mas-



**FIGURE 2.** Mucosa of anterior half of both membranous vocal folds was de-epithelialized.



**FIGURE 3.** De-epithelialized portion of both vocal folds was brought together with three sutures.

Download English Version:

<https://daneshyari.com/en/article/7533425>

Download Persian Version:

<https://daneshyari.com/article/7533425>

[Daneshyari.com](https://daneshyari.com)