

Available online at www.sciencedirect.com

ScienceDirect

journal homepage: <http://www.elsevier.com/locate/rpor>

Case report

Bone in the breast? Long term toxicity 21 years after interstitial brachytherapy as a boost



Sara Imboden^{a,*}, Laura Knabben^a, Michael D. Mueller^a,
Andreas R. Günthert^{c,1}, Kristina Lössl^b

^a Department of Obstetrics and Gynecology, University Hospital of Berne and University of Berne, 3010 Berne, Switzerland

^b Department of Radiooncology, University Hospital of Berne and University of Berne, 3010 Berne, Switzerland

^c Department of Obstetrics and Gynecology, Cantonal Hospital, Lucerne, Switzerland

ARTICLE INFO

Article history:

Received 20 October 2017

Received in revised form

2 March 2018

Accepted 23 June 2018

Keywords:

Breast cancer

Radiotherapy

Partial breast irradiation

Fat necrosis

Breast conservation

ABSTRACT

An 81-year-old patient developed an exulcerous tumor in her left breast 21 years after breast cancer treatment with lumpectomy and adjuvant radiotherapy. At the time of the initial treatment 21 years ago, whole breast irradiation was performed with a prescribed dose of 48 Gy and a maximal dose of 69 Gy. In addition, the patient received a 14.7 Gy boost with multicatheter brachytherapy as partial breast irradiation.

In general, fat necrosis after radiotherapy, surgery or trauma is a minor problem for patients, but can lead to diagnostic difficulties. The incidence varies: the literature indicates that it occurs in up to 34% of cases. The direct pathogenesis is not clear; it can be due to high radiation dose to the breast, dosimetric inhomogeneities or surgical complications (seromas and inflammation).

The tumor in the case described here, occurring more than two decades after the primary treatment, is a rarity in this extent and is an unusual clinical, radiological, and histological finding. It provides a good example of the need for an individualized approach to treatment.

© 2018 Greater Poland Cancer Centre. Published by Elsevier Sp. z o.o. All rights reserved.

1. Introduction

Fat necrosis after radiotherapy, surgery or other trauma is rarely a problem for patients; it is described in the literature as occurring in 2–52% of cases following radiotherapy, with a wide spread of occurrence depending on the patient and

treatment characteristics.¹ Since it can be observed also in asymptomatic patients in mammograms, diagnosis can be difficult; such difficulties may even result in an indication for secondary mastectomies.^{2,3}

Fat necrosis can occur after all forms of adjuvant radiotherapy. The pathogenesis is unclear. Risk factors are

* Corresponding author at: Department of Obstetrics and Gynecology, University Hospital of Berne, Inselspital, Effingerstrasse 102, 3010 Bern, Switzerland.

E-mail address: sara.imboden@insel.ch (S. Imboden).

¹ Present address:

<https://doi.org/10.1016/j.rpor.2018.06.002>

1507-1367/© 2018 Greater Poland Cancer Centre. Published by Elsevier Sp. z o.o. All rights reserved.

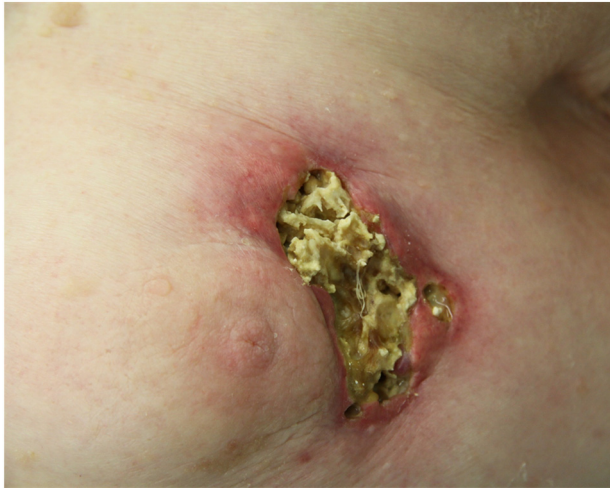

Fig. 1 – Exulcerated tumor in the right breast.

seromas, hematomas, inflammation, and locally high radiation dosage.¹

Partial breast irradiation (PBI) is becoming an accepted alternative treatment in adjuvant therapy for early-stage breast cancer for selected patients. Multicatheter brachytherapy was the first treatment method to be introduced; for this therapy we have the longest period of follow-up data.^{4,5} Long-term analyses now extend up to 12 years, showing recurrence rates equal to recurrence rates following whole breast irradiation.⁶⁻¹⁰ Good cosmetic results have led to this change in treatment options. In the early 2000s, brachytherapy was used in most cases as a boost, in addition to whole breast radiation.¹¹ Higher doses were generally applied, especially as less precise application methods were available at that time; this led to locally high doses known to be associated with a higher rate of long-term toxicity.¹²

1.1. Case report

An 81-year-old patient with a hard, ulcerating tumor of her left breast was referred to our department. Twenty-one years earlier, the patient was treated for early stage breast cancer (pT1) with a lumpectomy, axillary lymphadenectomy, and postoperative irradiation. The radiation was planned with computer tomography and then given first as external beam radiotherapy with Co60 with 1.8 Gy ED/GD 48.6 Gy, dosed to the 70% isodose (leading to a maximal dose of 69 Gy). In addition, she had LDR-brachytherapy as a boost (14.7 Gy in 28 h; 70 cGy/h). The patient underwent the therapy without complications. At the six-month control after radiotherapy, a radiation mastitis was documented, although with few symptoms, such that no therapy was indicated. After that, the cosmetic result was good, and all the follow-up controls showed no sign of recurrence. Almost twenty years later, the patient was treated on multiple occasions for mastitis with skin thickening and then for an ulcerating skin lesion at the lumpectomy site. After conservative treatment, the lesions regressed, but never disappeared entirely; biopsies and radiologic findings were always without signs of malignancy. Over time, the tumor grew, turned harder and the ulceration persisted (Fig. 1).

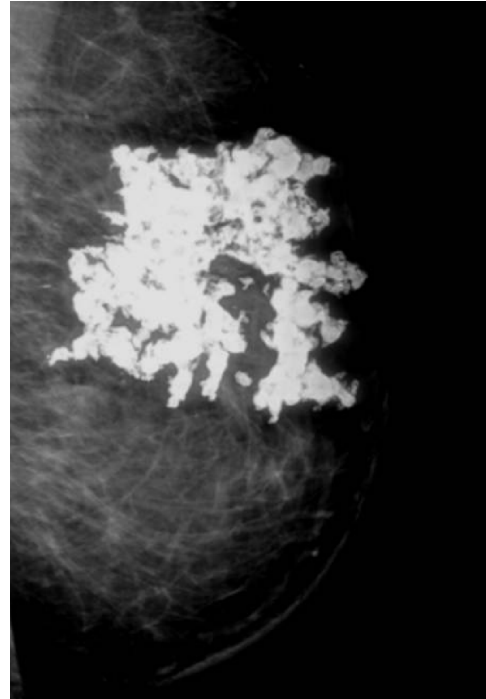


Fig. 2 – Mammogram of the right breast.

The mammogram showed a large inhomogeneous, hyperchogenic lesion corresponding to fat necrosis; a complete mammogram assessment was not possible because of the extent of the lesion (Fig. 2). In breast ultrasound, the same lesion showed a hypoechoic lesion with large posterior acoustic shadowing, which did not, however, provide a definitive diagnosis. We performed multiple biopsies, which showed necrosis but no malignant cells. An indication for resection was given because of uncontrolled ulceration, fetid odor, and also the need to rule out malignancy definitively. This 81-year-old patient had a strong desire for breast conservation therapy, even though an anisomasty was preexistent due to the first operation.

Intraoperatively, the tumor was excised with a macroscopic margin of 1–2 cm. To achieve a good cosmetic result, the infra-axillary tissue was mobilized, and the defect was covered with a V-Y plasty (Fig. 3).

The definitive histology showed ulceration, fibrosis, large-cell foreign-body reaction, and mineralization with ossification, this being the last stage of fat necrosis. No signs of malignancy were seen.

The patient had an uneventful hospital stay of three days. The postoperative control showed a good cosmetic result.

2. Discussion

This case report shows the diagnostic challenge of postoperative and post-radiation breast lesions. Even though multiple biopsies had excluded malignancy, a removal of the lesion had to be considered, also due to the fact that it was becoming a care issue.

Download English Version:

<https://daneshyari.com/en/article/8200952>

Download Persian Version:

<https://daneshyari.com/article/8200952>

[Daneshyari.com](https://daneshyari.com)