



Neuropathology of Parkinson disease



Dennis W. Dickson*

Department of Neuroscience, Mayo Clinic, Jacksonville, FL, United States

ARTICLE INFO

Article history:

Received 16 July 2017

Received in revised form

28 July 2017

Accepted 31 July 2017

Keywords:

Parkinson disease

Neuropathology

α -Synuclein

Lewy body

ABSTRACT

Introduction: Parkinson's disease (PD) is characterized by bradykinesia, rigidity, postural instability and tremor. Several pathologic processes can produce this syndrome, but neurodegeneration accompanied by neuronal inclusions composed of α -synuclein (Lewy bodies) is considered the typical pathologic correlate of PD.

Methods: The neuropathologic features of PD are reviewed based upon personal experience and review of the literature. Molecular pathology of PD is summarized from cell biological and animal studies.

Results: The pathologic feature that correlates with signs and symptoms of PD is neuronal loss in the substantia nigra with dopaminergic denervation of the striatum. Neuronal degeneration in the substantia nigra preferentially affects the ventrolateral cell group that projects to posterolateral putamen and is accompanied by formation of Lewy bodies composed of aggregated α -synuclein. Some patients with PD are found at autopsy to have other pathologic processes, such as multiple system atrophy, progressive supranuclear palsy and cerebrovascular disease (vascular Parkinsonism). The peripheral autonomic nervous system is also affected. The triggering event in PD is unknown, but recent studies suggest a role for loss of nuclear membrane integrity. Once α -synuclein aggregates forms, evidence supports cell-to-cell propagation.

Conclusion: PD is a multisystem synucleinopathy caused by poorly characterized genetic and environmental factors that produces degeneration in selectively vulnerable neuronal populations.

© 2017 Elsevier Ltd. All rights reserved.

1. Introduction

Parkinson's disease (PD) is a progressive neurological disorder characterized by bradykinesia, tremor, rigidity and postural instability. There are a number of disorders that can have some or all of these clinical features, and the clinical syndrome is referred to as "Parkinsonism." Disorders in which Parkinsonism is a prominent feature are referred to as "Parkinsonian disorders." Parkinsonian disorders include degenerative vascular, traumatic and toxic etiology (Table 1). In autopsy series the most common neurodegenerative causes of Parkinsonism are α -synucleinopathies (Lewy body disease (LBD) and multiple system atrophy (MSA)) and tauopathies (progressive supranuclear palsy (PSP) and corticobasal degeneration (CBD)). These disorders are defined based upon the predominant protein that accumulates within degenerating neurons and glia. Some of these are considered atypical Parkinsonian disorders because they have other clinical features, such as autonomic

dysfunction in MSA, vertical gaze palsy in PSP, and higher order cortical deficits (e.g., apraxia) in CBD. While relatively uncommon, cerebrovascular disease can sometimes be associated with Parkinsonism ("vascular PD" (VaP)), usually a lower body Parkinsonism [1].

1.1. Common features of disorders presenting as PD

Degenerative parkinsonian disorders can be inherited or sporadic, but they all have selective loss of dopaminergic neurons in the substantia nigra that project to the basal ganglia. Within the substantia nigra, the ventrolateral cell groups (i.e. A9 or nigrostriatal pathway) are most vulnerable, while dorsal and medial cell groups (i.e. A10 or mesolimbic pathway) are more resistant [2]. The biological basis for selective vulnerability of dopaminergic neurons may reside in pacemaker-like properties of these cells, leading to frequent intracellular calcium transients [3]. Calcium buffering may be relatively deficient in A9 neurons compared with A10 neurons [4], leading to cellular stress and eventual disruption of cellular homeostasis. Cell death is associated with disruption of nuclear membrane integrity and release of proaggregant nuclear factors [5],

* Mayo Clinic, 4500 San Pablo Road, Jacksonville, FL 32224, United States.
E-mail address: dickson.dennis@mayo.edu.

Table 1
Parkinsonian disorders.

Classification	Examples
Degenerative parkinsonism	
α -Synuclein	Parkinson's disease, multiple system atrophy
Tau	Progressive supranuclear palsy; corticobasal degeneration; Guam Parkinson dementia complex; chronic traumatic encephalopathy
TDP-43	Perry syndrome; frontotemporal lobar degeneration (FTLD-TDP)
Nonspecific	Genetic PD (<i>PINK1</i> , <i>PRKN</i> , <i>POLG1</i> , some forms of <i>LRRK2</i>)
Non-degenerative parkinsonism	
Vascular	Vascular parkinsonism
Toxic	MPTP; manganese poisoning
Drug-induced	Antipsychotic medications
Infectious	Influenza virus (post-encephalitic parkinsonism)

Parkinsonian disorders classified by major etiologic factor.

such as histones [6], that may trigger α -synuclein aggregation. Once aggregation begins, it may subsequently spread to other cells by direct or indirect means. Propagation of abnormal forms of α -synuclein can be modeled in cellular [7] and animal systems [8], and it is the most popular hypothesis to explain the progressive involvement of select neuronal systems in PD [9].

1.2. Clinicopathologic findings and frequency of disorders presenting as PD

In the Mayo Clinic brain bank of 132 patients with antemortem diagnosis of PD, without dementia, the most common pathologic finding was LBD (77%) (Fig. 1) and 81% had α -

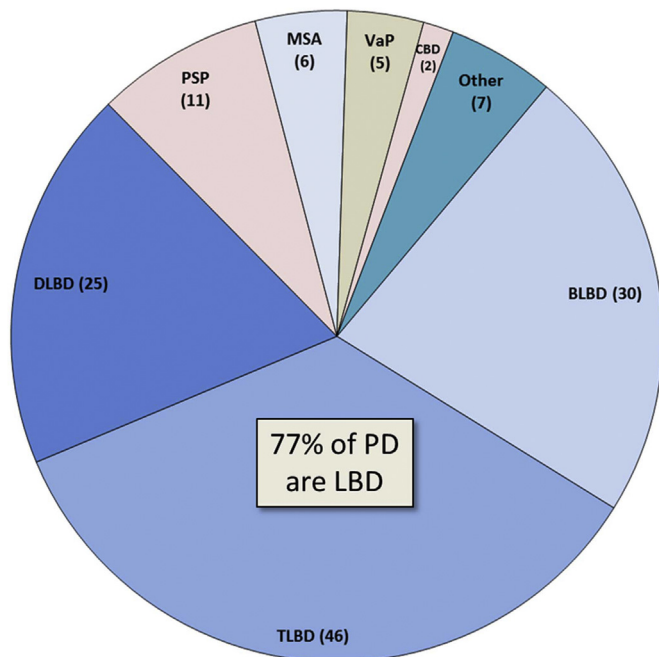


Fig. 1. Frequency of neuropathologic disorders with antemortem clinical diagnosis of PD. The pie chart shows the frequency of pathologic disorders that present with Parkinsonism without dementia in the Mayo Clinic brain bank ($n = 132$). The most common pathology is that of LBD (brainstem predominant (BLBD), transitional (TLBD) or diffuse (DLBD)). The next most frequent disorder is progressive supranuclear palsy (PSP), followed by multiple system atrophy (MSA) and vascular Parkinsonism (VaP). Corticobasal degeneration rarely presents as PD. Other rare causes of PD include nonspecific substantia nigra degeneration associated with basal ganglia pathology or with frontotemporal degeneration (with or without motor neuron disease).

synucleinopathy (LBD + MSA). Only 10% had tauopathy (PSP + CBD); 4% had VaP. PSP is most often clearly differentiated from PD, and the diagnostic accuracy of PSP in the Mayo Clinic brain bank, which houses over 1200 pathologically confirmed PSP brains, is over 80% [10]. While PSP has neuronal loss and degeneration in the substantia nigra as in PD, it is not associated with α -synuclein pathology, but rather tau pathology, with globose neurofibrillary tangles rather than Lewy bodies in affected nigral neurons. The additional involvement of basal ganglia, thalamus, subthalamic nucleus, as well as caudal brainstem and cerebellum in PSP leads to a clinical syndrome clearly different from PD in most cases. The exception is so-called PSP-P [11], in which patients at least early in the course have features of PD, including response to dopamine replacement therapy and asymmetrical Parkinsonism. In PSP-P tau pathology tends to be milder than in typical PSP, and it is associated with disproportionate brainstem compared to diencephalic pathology.

Although MSA is an α -synucleinopathy like PD, it is pathologically distinct – the major pathology is in oligodendroglia rather than neurons. Neuronal inclusions occur, but they do not resemble Lewy bodies, and their distribution is quite different from Lewy bodies in PD [12]. Neuronal inclusions in MSA tend to be most frequent in the putamen, pontine nuclei and inferior olivary nucleus. Inclusions can be detected in the substantia nigra and locus ceruleus, but even here they rarely resemble Lewy bodies. In contrast to PD, where the basal ganglia are morphologically unremarkable (even when there are significant numbers of Lewy neurites), the posterolateral putamen in MSA has macroscopic atrophy and discoloration, and there is severe neuronal loss and gliosis with excessive iron accumulation, especially in MSA-P. These putaminal changes can be detected on antemortem neuroimaging, if it is performed as part of the diagnostic evaluation. MSA-P is the form of MSA presenting primarily as a Parkinsonian disorder, as opposed to cerebellar ataxia (MSA-C). The diagnostic accuracy of pathologically confirmed MSA in the Mayo Clinic brain bank is less than that for PSP (about 70%). Cases with autopsy confirmed MSA are most often misdiagnosed clinically as either PSP (47%) or atypical PD (34%). The most frequent disorder clinically misdiagnosed as MSA, but not associated with MSA pathology at autopsy is PD or dementia with Lewy bodies with significant autonomic dysfunction [13]. As clinicians becoming increasingly aware of the multisystem nature of α -synuclein pathology in PD, including frequent, if not invariable, involvement of both central and peripheral components of the autonomic nervous system, it becomes increasingly important to differentiate PD from MSA by criteria other than only autonomic dysfunction.

Some rare disorders can resemble PD include those with nonspecific substantia nigra degeneration. In the brain bank one such patient carried a *LRRK2* mutation. The patient had nonspecific substantia nigra degeneration, without Lewy bodies or tau pathology [14]. Most *LRRK2* patients have Lewy body pathology, with a lower frequency showing predominantly tau pathology [15].

Substantia nigra degeneration is often observed in frontotemporal degeneration with or without motor neuron disease, and Parkinsonism is not uncommon in frontotemporal degeneration [16], but because of significant involvement of brain regions outside of the extrapyramidal system, it is rarely misdiagnosed as PD.

Rare familial forms of Parkinsonism can have substantia nigra degeneration with TDP-43 pathology, rather than α -synuclein or tau pathology. An example of this is Perry syndrome, which is caused by mutations in *DCTN1* [17]. *DCTN1* encodes the dynactin subunit p150^{Glued} and is a motor protein involved in axonal transport. These patients present with Parkinsonism, depression and central hypoventilation and have pallidonigral TDP-43 proteinopathy as the underlying pathologic process.

Download English Version:

<https://daneshyari.com/en/article/8285613>

Download Persian Version:

<https://daneshyari.com/article/8285613>

[Daneshyari.com](https://daneshyari.com)