Morphologie (2017) xxx, xxx—xxx

Disponible en ligne sur
ScienceDirect
www.sciencedirect.com

Elsevier Masson France
EM|consulte
www.em-consulte.com

CASE REPORT

Embryological and comparative description of the cephalic vein joining the external jugular vein: A case report

Description embryologique et comparative de la veine céphalique jointe à la veine jugulaire externe : à propos d'un cas

R.C. Araújo[a], L.A.S. Pires[b], M.L. Andrade[c], M.C. Perez[d], C.S.L. Filho[d], M.A. Babinski[a,b,c,*]

[a] *Department of Morphology, Biomedical Institute, Fluminense Federal University, Rua Professor Ernani Mello, 101, São Domingos, Niterói 24210-150, Rio de Janeiro, Brazil*
[b] *Medical Sciences Post Graduation Program, Fluminense Federal University, Rio de Janeiro, Brazil*
[c] *Traumatology and Orthopedics Service, Salgado Filho Hospital, Rio de Janeiro, Brazil*
[d] *Orthopedics Service, SARAH Hospital, Brasilia, Brazil*

KEYWORDS
Anatomical variations;
Cephalic vein;
External jugular vein;
Anthropology;
Embryology

Summary The cephalic vein arises from the radial end of the dorsal venous arch. It turns around the radial border of the forearm and passes proximally along the arm to the shoulder, where it enters the axillary vein by penetrating the clavipectoral triangle. The cephalic vein is prone to vary at the antecubital fossa, where it forms numerous anastomoses. A male cadaver fixated with a 10% formalin solution was dissected during regular anatomy lessons. It was found that the cephalic vein crossed the upper third of the arm between two fasciculi of the deltoid muscle and reached the shoulder, where it passed above the acromion and crossed the posterior border of the clavicle in order to join the external jugular vein. The cephalic vein is one of the most used veins for innumerous activities, such as venipunctures and arteriovenous fistula creation. Furthermore, it is an anatomical landmark known for its consistent anatomy, as it possesses low rates of variability. Despite that, its anatomical variations are clinically and surgically significant and healthcare professionals must be aware of the variations of this vessel.

* Corresponding author.
E-mail address: mababinski@gmail.com (M.A. Babinski).

https://doi.org/10.1016/j.morpho.2017.10.002
1286-0115/© 2017 Elsevier Masson SAS. All rights reserved.

We aim to report a rarely described variation of the cephalic vein and discuss its embryological, phylogenetic and clinical features.
© 2017 Elsevier Masson SAS. All rights reserved.

Résumé La veine céphalique prend naissance sur le côté radial de l'arc veineux dorsal. Elle monte vers le bord radial de l'avant-bras et passe de manière du bras à l'épaule, où la veine pénètre fascia clavipectoral. La veine céphalique est susceptible de variations dans la fosse cubitale, où elle forme des nombreuses anastomoses. Un corps d'un homme, fixé avec une solution de formol 10 %, a été disséqué au cours de travaux pratiques d'anatomie. On a retrouvé la veine céphalique traversant le tiers supérieur du bras entre deux faisceaux du muscle deltoïde, où elle a passé l'acromion et a franchi le bord arrière de la clavicule pour rejoindre la veine jugulaire externe. La veine céphalique est une des veines les plus utilisées pour de nombreux gestes médicaux, comme les ponctions veineuses et la création de fistules artérioveineuses. En outre, elle représente un repère anatomique fiable, car elle possède des faibles taux de variabilité. Malgré cela, ses variations anatomiques sont importantes à considérer du point de vue chirurgical et les professionnels de santé doivent être conscients de ses variations. Notre objectif a été de rapporter une variante rarement décrite de la veine céphalique est de discuter ses caractéristiques embryologiques, phylogénétiques et cliniques.
© 2017 Elsevier Masson SAS. Tous droits réservés.

Introduction

The cephalic vein (CV) arises from the radial portion from the dorsal venous network and travels around the radial border of the forearm. As it crosses the elbow, the CV is found in an anatomic groove between the brachioradialis and biceps brachii muscles. The CV travels superficially to the musculocutaneous nerve and then ascends in the groove along the lateral border of the biceps brachii muscle [1,2].

In the upper third of the arm, the CV passes between the pectoralis major and deltoid muscles, crosses the axillary artery, and joins the axillary vein just below the clavicle after penetrating the clavipectoral triangle accompanied by the acromial branch of the thoracoacromial artery. An accessory CV is often present, and it arises from the ulnar side of the dorsum of the hand or the posterior aspect of the forearm and usually joins the CV below the elbow [1,2]. The CV can display different patterns of anastomosis with other superficial veins of the forearm at the antecubital fossa [2—4]. It is one of the most important veins of the superficial drainage system, as it is usually preferred for the insertion of permanent pacing leads [5], peripherally inserted central catheters (PICCs) [6] and the formation of arteriovenous fistulas [7] thus, knowledge of its variations is crucial.

We report the case of a CV variation in a male cadaver and discuss its clinical and surgical aspects while also discussing its comparative anatomy.

Case report

A male cadaver, fixated in a 10% buffered formalin solution, was dissected during regular lessons on the Anatomy Laboratory of the Fluminense Federal University. While dissecting the superficial veins of the upper limb, an uncommon anatomical variation of the CV was found.

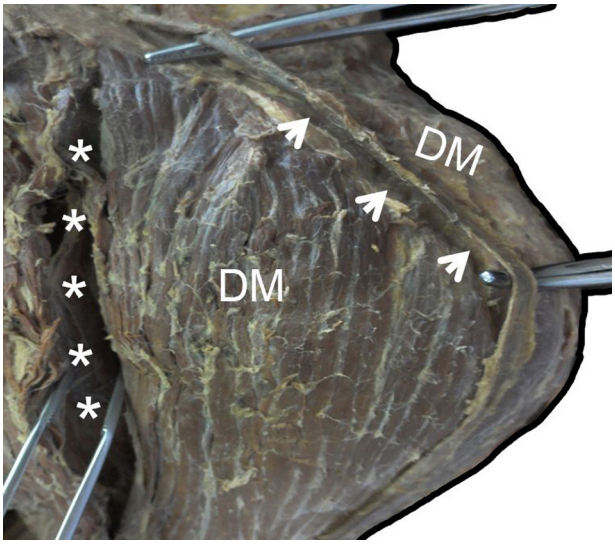

Figure 1 The cephalic vein is displayed grooving the deltoid muscle (DM) (white arrows), while the deltopectoral groove is empty (white asterisks).

This vein crossed the upper third of the left upper limb in a groove between the anterior and medial fasciculi of the deltoid muscle, then, it ascended throughout the acromion and joined the external jugular vein (EJV) while crossing the posterior border of the clavicle (Fig. 1).

Discussion

The superficial venous drainage from the head and neck is essentially performed by the EJV (External Jugular Vein) and

Please cite this article in press as: Araújo RC, et al. Embryological and comparative description of the cephalic vein joining the external jugular vein: A case report. Morphologie (2017), https://doi.org/10.1016/j.morpho.2017.10.002

Download English Version:

https://daneshyari.com/en/article/8390838

Download Persian Version:

https://daneshyari.com/article/8390838

Daneshyari.com