

Aspergillus tamaris keratitis in a contact lens wearer

Juan Cuadros^{a,*}, Juan Gros-Otero^b, Patricia Gallego-Angui^a, Ann Karolin Scheu^c,
Ángeles Montes-Mollón^b, Cinta Pérez-Rico^b, Javier Paz Moreno^b, Peña Gómez-Herruz^a,
Juan Soliveri^c, Miguel Teus^b

^a Microbiology Department, Hospital Universitario Príncipe de Asturias, Alcalá Meco S/N, Madrid 28805, Spain

^b Ophthalmology Department, Hospital Universitario Príncipe de Asturias, Alcalá Meco S/N, Madrid 28805, Spain

^c Biomedicine and Biotechnology Department, Universidad de Alcalá de Henares, Campus Universitario C/ 19, Av. de Madrid, Km 33,600, Alcalá de Henares, Madrid 28871, Spain

ARTICLE INFO

Keywords:

Keratitis

Aspergillus infections

Aspergillus tamaris

Contact lens

ABSTRACT

Keratitis produced by *Aspergillus tamaris* has been previously described associated to an ocular injury. We report a case in a contact lens wearer with a history of previous bilateral myopic LASIK ablation, bilateral intracorneal rings and vitrectomy and scleral buckling in his left eye. The fungus could be quickly identified combining phenotype, microscopy and mass spectrometry. Treatment with intravenous amphotericin, oral voriconazole, and topical amphotericin and natamycin and voriconazole was needed for corneal preservation.

1. Introduction

Fungal eye infections can be very severe and rapid diagnosis is crucial for a successful treatment. Mass spectrometry is being available increasingly in most clinical microbiology laboratories and can be very useful for a prompt diagnosis. A case of keratitis by *A. tamaris* is presented where microscopy, culture and mass spectrometry were sequentially used for the management of the patient.

2. Case report

In August 2015 a patient attended our emergency department complaining of six days of blurred vision, pain and discharge in his left eye (day 0). The symptoms had started four days before, when he was on a tourist trip in Paris, where he was prescribed antibiotic eyedrops (ticarcillin, gentamicin and vancomycin every hour). His previous ophthalmic history included bilateral myopic LASIK ablation, bilateral corneal ectasia treated bilaterally with intracorneal rings and retinal detachment in his left eye treated with vitrectomy and scleral buckling (16, 8 and 6 years before, respectively). At the moment of the diagnosis, he was also using contact lenses in both eyes to correct his residual refractive error. The physical examination of his left eye showed a corneal abscess in the nasal region of 2,7 mm of biggest diameter with surrounding corneal oedema, normal intraocular pressure (IOP) and a best corrected visual acuity of 0.1 (decimal scale). A bacterial corneal infection was suspected and topical treatment was started with topical

vancomycin (50 mg/ml) and ceftazidime (50 mg/ml) every hour, oral ciprofloxacin (500 mg twice a day) and topical 1% atropine twice a day. After twenty days of a favorable evolution, when topical antibiotics were tapered until one drop every 3 h, the clinical features worsened with an increase in epithelial defect, stromal thinning, corneal and conjunctival swelling and more pain (day +20).

Samples from the corneal ulcers were taken for microbiological studies. The Gram stain of a corneal scraping taken with a intramuscular (IM) needle showed numerous hyphae (Fig. 1) and treatment was initiated immediately with topical amphotericin B 0,5%, as it was the only antimycotic topical drug available in our center at that time. In the following 24 h grew a velvety hyaline fungus, which was initially identified by microscopy as belonging to the genus *Aspergillus* spp. Matrix-assisted laser desorption/ionization time-of-flight mass spectrometry (MALDI-TOF MS, Bruker Biotyper system) [1] was performed on colonies pretreated with formic acid and identified the strain as *Aspergillus tamaris* (certainty grade of 1.628) (day +21).

The sample was inoculated onto Sabouraud glucose agar and incubated at 30 °C. In the following days the fungus grew rapidly covering all the plate. Colonies were olive green in the surface (Fig. 2) and white-pale yellow on the reverse side, which became darker with time. They appeared rough and powdery with a wavy edge. Blue lactophenol staining showed septate hyphae, with 5–7.5 µm diameter rough conidiophores which ended into a globose vesicle, 35–50 µm diameter. Uniseriate phialides were scattered across the surface of the vesicle (Fig. 3). Previous reports [2] have warned about the common

* Corresponding author.

E-mail address: juanantonio.cuadros@salud.madrid.org (J. Cuadros).

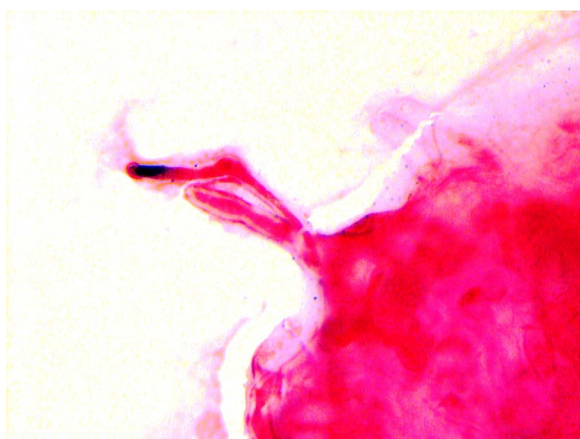


Fig. 1. Hyphae on Gram stain ($\times 1000$ high power field, scale bar in microns).

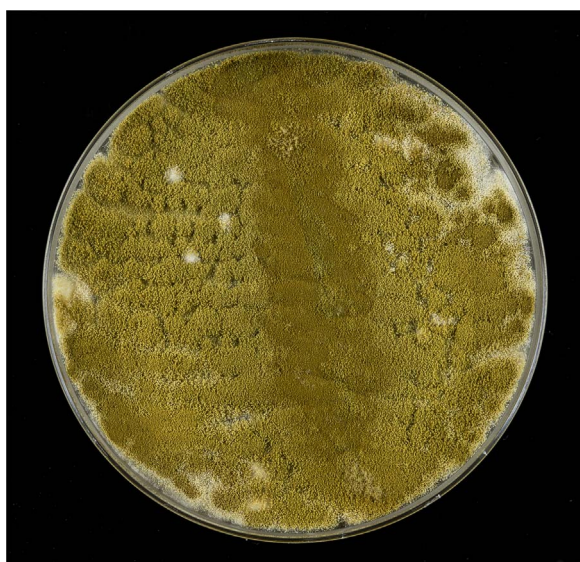


Fig. 2. Olive green velvety mold in Sabouraud's medium.

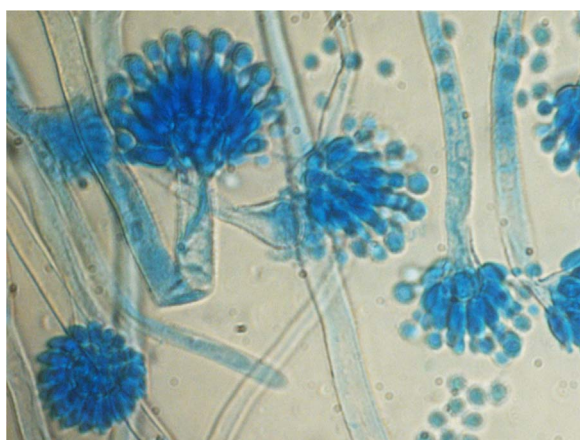


Fig. 3. Conidiophores with uniseriate phialides across the vesicles ($\times 400$).

misidentifying of *A. tamarii* and *A. nomius* as *A. flavus* when only phenotypic methods are used.

Identification of the microorganism of the specimen was based on the nucleotide sequences of its ITS region [3] and its conserved regions of the calmodulin "cmd" [4] and betatubulin "bt2" [5] genes. For that purpose, 100 ml baffled flasks containing 30 ml of Potato Dextrose

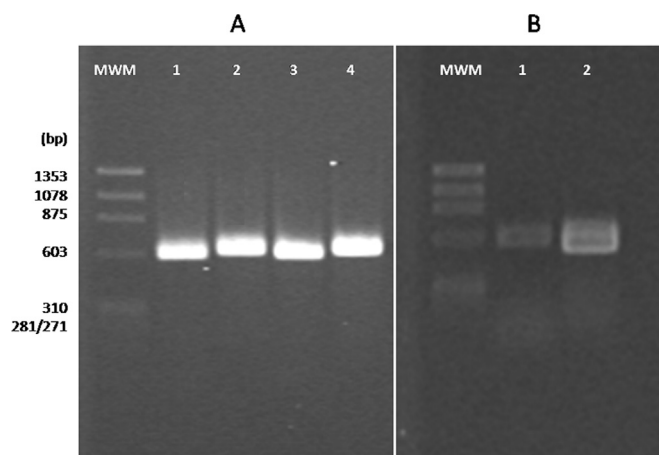


Fig. 4. Agarose gel electrophoresis of amplicons obtained by PCR amplification of total DNA from pure cultures of the specimen. MWM: Φ 174 *Hae*III. Template DNA sample 1 (lanes 1 and 2) and sample 2 (lanes 3 and 4). A: Primer pair ITS 1/4 (lanes 1 and 3) or ITS 5/1 (lanes 2 and 4) using the following PCR program: 95 °C for 2 min followed by 34 cycles of 95 °C for 30 s, 55 °C for 30 s, 72 °C for 1 min, and a final extension at 72 °C for 10 min B: Template DNA sample 1 with primer pair cmd5/6 (lane 1) or bt2a/b (lane 2) using the following PCR program: 95 °C for 2 min followed by 32 cycles of 94 °C for 1 min, 58 °C for 1 min, 72 °C for 1 min, and a final extension at 72 °C for 6 min.

Broth were inoculated with a single colony of the microorganism in duplicate and incubated for 48 h (30 °C, shaking) to obtain pure cultures of the specimen. Total DNA was extracted from each culture using the "UltraClean® Microbial DNA Isolation Kit" and DNA quality assessed by spectrophotometry. ITS, cmd and bt2 regions were amplified by PCR using AmpliTaq Gold® 360 Master Mix and the primer pairs ITS1/ITS4 and ITS5/ITS4, cmd5/6 and bt2a/bt2b, respectively. Amplicons were verified by electrophoresis on 1.2% agarose gels (Fig. 4) and sequenced with the corresponding primers used for their amplification. Nucleotide sequences were analyzed by the Chromas Lite program and assembled with CAP3. No differences were found in the genetic sequences of either DNA sample (see Annex I and II). Finally, the nucleotide sequences of the ITS, cmd and bt2 regions were blasted against GenBank using the NCBI/BLAST tool (see Annex III and IV).

Identity percentages were greater than 99% with respect to different types of collection strains of *Aspergillus tamarii* (strain NRRL20818, ITS region, accession number, NR135325; strain NRRL 4966, calmodulin gene, accession number, EF661527; strain NRRL20818, betatubulin gene, accession number AY017540).

The Etest method (bioMérieux) for molds was performed for determining the MICs to guide the antifungal treatment. Strips containing amphotericin B (0.002–32 µg/ml), fluconazole (0.016–256 µg/ml), posaconazole (0.002–32 µg/ml), and caspofungine (0.002–32 µg/ml), were used on RPMI agar (bioMérieux). After 48 h of incubation at 30 °C, the CMI was read as the drug concentration at which the inhibition zone intersected the Etest strip. *A. tamarii* showed the following CMIs: 0.25 µg/ml to amphotericin B, > 256 µg/ml to fluconazole, 0.5 µg/ml to caspofungine and 0.094 µg/ml to posaconazole.

Broth microdilution method (BMD) was carried out in the Spanish National Center of Microbiology according to methodology developed by the Antifungal Subcommittee of the European Committee on Antimicrobial Susceptibility Testing (EUCAST) [6]. The MIC values obtained by BMD were as follows: 0.25 µg/ml to amphotericin B, 0.5 µg/ml to voriconazole, 0.06 µg/ml to posaconazole, 0.5 µg/ml to caspofungin, 0.12 µg/ml to micafungin and 0.5 µg/ml to anidulafungin.

Due to the progressive worsening of the corneal ulcer, the patient was admitted to hospital and started treatment with topical voriconazole 1% and intravenous liposomal amphotericin B (2 mg/kg/day), once the initial E-test susceptibility tests were known. After 10 days of IV treatment, the intracorneal rings in his left eye were removed due to progressive corneal melting and the development of hypopyon in

Download English Version:

<https://daneshyari.com/en/article/8484780>

Download Persian Version:

<https://daneshyari.com/article/8484780>

[Daneshyari.com](https://daneshyari.com)