

Case report

An after after-cataract: A curious case of visual axis re-opacification



Jay Kalliath¹; Gaurav Prakash^{1,*}; Kavitha Avadhani; Anitha Shakuntala

Abstract

Posterior capsular opacification (PCO) is common after cataract surgery. Recurrence is very rare after a successful Yttrium aluminium-garnet (YAG) capsulotomy in adults. We report a case of visual axis re-opacification after a successful YAG capsulotomy for PCO in an adult. A 60-year male underwent phacoemulsification with +20.0 D acrylic hydrophobic intraocular lens implantation and silicon oil removal (SOR) five months after a successful retinal detachment repair. He underwent a capsulotomy after two months of surgery; however, the visual axis re-opacified after three more months. A YAG anterior hyaloidotomy resulted into improved vision which was maintained over further follow-up.

In a post-vitreotomy pseudophakic eye, compression by silicon oil on the posterior capsule is lost after SOR, causing easier and faster migration of lens epithelial cells from the equator to the centre forming an early PCO. Recurrence is possible due to the proliferation of lens epithelial cells along anterior hyaloid also.

This case highlights the infrequent scenario of visual axis re-opacification and therefore has teaching value for residents and trainee doctors, who should be made aware of this occurrence. Patients should be explained about this possibility when undergoing YAG capsulotomy in complicated cases such as this one.

Keywords: Posterior capsular opacification, Visual axis re-opacification, Capsulotomy, Anterior hyaloid phase opacification

© 2016 The Authors. Production and hosting by Elsevier B.V. on behalf of Saudi Ophthalmological Society, King Saud University. This is an open access article under the CC BY-NC-ND license (<http://creativecommons.org/licenses/by-nc-nd/4.0/>). <http://dx.doi.org/10.1016/j.sjopt.2016.11.002>

Introduction

Visual axis opacification after cataract surgery can be a disturbing experience for the patient. Posterior capsular opacification and anterior hyaloid face (AHF) opacification are the possible causes, with the former being the cause in a predominant majority.^{1,2} AHF opacification occurs more commonly after paediatric cataract surgery, thus necessitating an anterior vitrectomy along with posterior capsulorhexis as a preventive measure. However, it is rarely seen in adults.

The treatment for both these causes of visual axis opacification is Nd:YAG laser assisted disruption of the opacified capsule/membrane done as an outpatient procedure. The procedure is fairly quick, causing a rapid recovery of vision if there are no other co-morbid factors. Mostly, this is an one-time procedure.

We report a case of visual axis re-opacification after a successful YAG capsulotomy for posterior capsular opacification in an adult. This case represents an important clinical lesson that visual axis re-opacification can occur rarely in adults and should be kept in mind as a possibility.

Received 26 April 2015; accepted 2 November 2016; available online 10 November 2016.

NMC Eye Care, New Medical Centre Specialty Hospital, Abu Dhabi, United Arab Emirates

* Corresponding author at: Department of Cornea and Refractive Surgery, NMC Eye Care, New Medical Center Specialty Hospital, Electra Street, PO Box 6222, Abu Dhabi, United Arab Emirates.

e-mail address: dr_gauravprakash@gmail.com (G. Prakash).

¹ Jay Kalliath and Gaurav Prakash have contributed equally to the manuscript.



Peer review under responsibility of Saudi Ophthalmological Society, King Saud University



Production and hosting by Elsevier

Access this article online: www.saudiophthaljournal.com www.sciencedirect.com

Case report

A 60-year-old man presented to us with sudden onset blurring of vision in the left eye due to a rhegmatogenous retinal detachment. His presenting corrected distance visual acuity (CDVA) was 20/400. He underwent an uneventful pars plana vitrectomy with silicone oil tamponade and 360-degree scleral buckle placement. He developed a non-granulomatous anterior uveitis in the immediate postoperative period which responded to topical steroids and resolved leaving patchy posterior synechiae as the sequelae. The postoperative course was uneventful up to the fifth month follow-up when he developed a posterior subcapsular cataract (Fig. 1A). He underwent phacoemulsification, synechiolysis and silicon oil removal in the left eye. A +20.0 D hydrophobic acrylic lens (Acrysof IQ, Alcon, CA) was implanted. The postoperative corrected distance visual acuity (CDVA) was 20/40 at 1 week postoperatively. However, over the next two months of follow-up, we found that there was a deterioration of CDVA (20/120). He was found to have a dense posterior capsular opacity (Fig. 1B).

The retina was well attached. An Nd-YAG capsulotomy was performed. Six shots of 0.5 mJ power were used in single pulse fashion circumferentially to create the opening. The capsulotomy was complete as evidenced in the photograph (Fig. 1C). The CDVA again improved to 20/40.

The patient was on regular follow-up. Three months after the YAG capsulotomy, he complained of blurring of vision again. The CDVA was 20/80. On slit lamp evaluation a new visual axis opacification was seen (Figs. 1D and 2). The margins of the old capsulotomy were at the same location; hence, it was not a spontaneous closure, as has been reported before.^{2,3} Lens epithelial cell proliferation was seen over the intact anterior hyaloid phase.

The retina was attached and the macula was normal. A pseudophakic eye with an intact posterior capsule and anterior hyaloid phase can be considered as a double set of membranes with each having a potential for opacification. So the differential diagnosis in this case was spontaneous closure of the posterior capsulotomy or AHF opacification as the possible causes of re-opacification of the visual axis and decrease in CDVA. As the capsulotomy margins were intact, this was not a case of spontaneous closure. Furthermore, anterior hyaloid face was seen clearly due to the migrated epithelial cells using it as a scaffold (Fig. 2).

After a thorough retinal evaluation, a YAG anterior hyaloidotomy was performed. Five shots of 0.3 mJ at single pulse were applied in a circular fashion. The visual axis was successfully cleared (Fig. 1E). The CDVA improved to 20/40 and was maintained till the last follow-up 6 months after capsulotomy (Fig. 1F).

Discussion

Recurrence of visual axis re-opacification in an adult after an adequately large YAG Capsulotomy is a rare phenomenon.⁴ It has also been reported rarely in cases of myotonic dystrophy.³ There were no signs of the disease in our patient.

Our case was interesting because there was a clear documentation against spontaneous closure of the capsulotomy as can be seen from the slit lamp photograph. Another interesting occurrence in our case was the 'early' (within two months of silicon oil removal) PCO formation. We reviewed literature and evaluated possible reasons for both the early PCO and spontaneous visual axis reopacification in our case.

A recent study has shown that PCO progresses more rapidly in patients undergoing combined or sequential

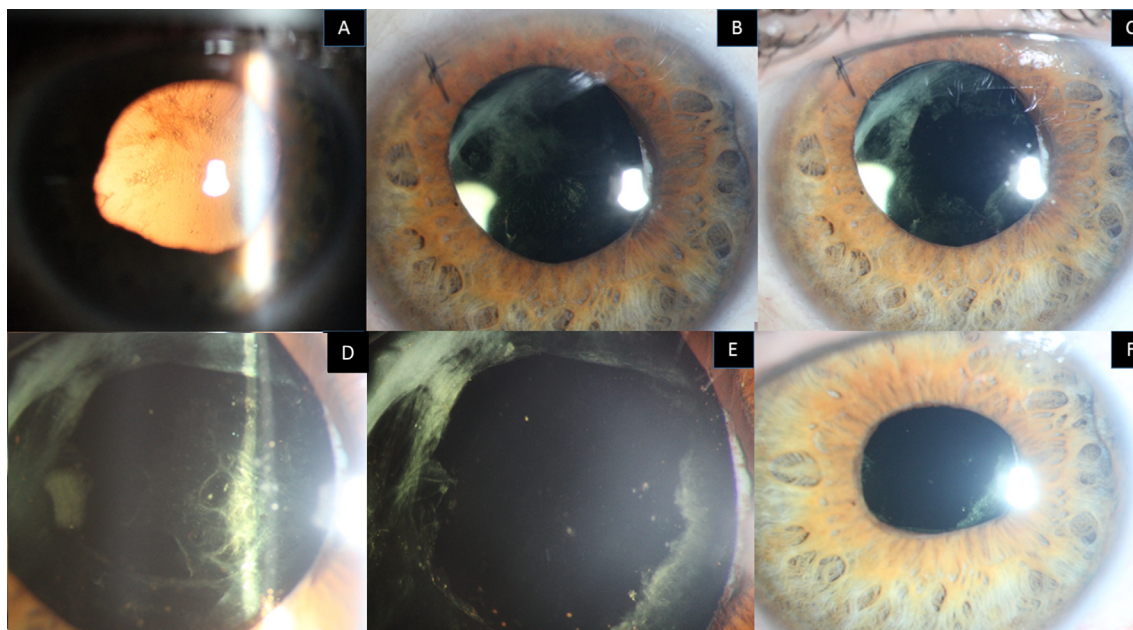


Figure 1. Slit lamp images showing the sequence of events in the case. (A) Post vitrectomised eye with posterior subcapsular cataract. (B) 2 months postoperative appearance with intraocular lens in situ and evident posterior capsular opacification. (C) Immediate post YAG appearance showing clearance of visual axis. (D) Re-appearance of visual axis opacification due to lens epithelial cell proliferation. (E) Immediate post YAG appearance showing the clearing of visual axis. (F) Post second YAG 6 months clinical picture showing a clear visual axis.

Download English Version:

<https://daneshyari.com/en/article/8592481>

Download Persian Version:

<https://daneshyari.com/article/8592481>

[Daneshyari.com](https://daneshyari.com)