



Technical Note

Modified axillary radiograph of the shoulder: a new position[☆]

Luís Filipe Senna^{a,*}, Rodrigo Pires e Albuquerque^b

^a Hospital Estadual Adão Pereira Nunes, Serviço de Ortopedia e Traumatologia, Duque de Caxias, RJ, Brazil

^b Universidade Federal Fluminense, Serviço de Ortopedia e Traumatologia, Niterói, RJ, Brazil

ARTICLE INFO

Article history:

Received 18 December 2015

Accepted 28 January 2016

Available online xxx

Keywords:

Shoulder

Shoulder dislocation

Shoulder joint

Radiography

Palavras-chave:

Ombro

Luxação do ombro

Articulação do ombro

Radiografia

ABSTRACT

Obtaining axillary radiographs of the shoulder in acute trauma is not always feasible. The authors present a new modification of this radiographic view, in order to assess the anatomic relationship between the humeral head and the glenoid cavity. The incidence is performed with the patient sitting on X-ray table, with the affected limb supported thereon. The authors describe the case of a 28-year-old male who suffered an anterior glenohumeral dislocation that was clearly evidenced by this modified radiograph. The concentric relationship between the humeral head and the glenoid cavity was also easily confirmed by obtaining such radiograph after the reduction maneuver.

© 2016 Sociedade Brasileira de Ortopedia e Traumatologia. Published by Elsevier Editora Ltda. This is an open access article under the CC BY-NC-ND license (<http://creativecommons.org/licenses/by-nc-nd/4.0/>).

Modificação da incidência radiográfica axilar para o ombro: uma nova posição

RESUMO

A obtenção de radiografias em perfil axilar do ombro em situação de trauma agudo nem sempre é tarefa fácil. Os autores apresentam uma modificação inédita dessa incidência radiográfica, com o objetivo de avaliar a relação anatômica da cabeça umeral com a cavidade glenoide. A incidência é medida com o paciente sentado sobre a mesa de exames de raios X, com o membro acometido apoiado sobre ela. Os autores descrevem o caso de um paciente de 28 anos que sofreu um episódio de luxação glenoumeral anterior que foi claramente evidenciada pela radiografia modificada. A relação de concentricidade entre a cabeça umeral e a cavidade glenoide foi facilmente confirmada pela obtenção da referida incidência radiográfica obtida após a manobra de redução.

© 2016 Sociedade Brasileira de Ortopedia e Traumatologia. Publicado por Elsevier Editora Ltda. Este é um artigo Open Access sob uma licença CC BY-NC-ND (<http://creativecommons.org/licenses/by-nc-nd/4.0/>).

[☆] Study conducted at Hospital Municipal Dr. Nelson de Sá Earp, Petrópolis, Rio de Janeiro, RJ, Brazil, and at Hospital Estadual Adão Pereira Nunes, Duque de Caxias, RJ, Brazil.

* Corresponding author.

E-mail: lfenna@yahoo.com.br (L.F. Senna).

<http://dx.doi.org/10.1016/j.rboe.2016.12.001>

2255-4971/© 2016 Sociedade Brasileira de Ortopedia e Traumatologia. Published by Elsevier Editora Ltda. This is an open access article under the CC BY-NC-ND license (<http://creativecommons.org/licenses/by-nc-nd/4.0/>).

Introduction

There is a general recommendation for the care of orthopedic trauma patients, which is to obtain at least two radiographic views in orthogonal planes for proper evaluation of the traumatized limb or joint.¹ In the case of the shoulder joint, such recommendation is particularly valuable, as failure to obtain X-rays in orthogonal planes, especially failure to obtain axillary radiographs, is considered to be the main cause of misdiagnosis in glenohumeral dislocations.² Radiographs in anteroposterior, lateral scapula, and axillary views are known as the shoulder trauma series³ and must be performed on all patients with trauma of such joint. The axillary view was first described in 1915 by Lawrence apud Jensen and Rockwood,⁴ and can be done with the patient standing or sitting. Ideally, it is necessary to position the shoulder in approximately 70°–90° of abduction to obtain this radiograph. In patients with mild trauma, this degree of abduction is feasible; however, for patients with more severe trauma, and especially those with glenohumeral joint dislocation, it is extremely difficult to obtain the axial image, because pain and joint incongruity greatly limit the abduction capacity of the joint. Thus, modifications in the classical axillary view have been proposed.^{5,6} The view described by Bloom and Obata⁵ is perhaps the best known method, as it allows for an axillary radiography without removing the patient's arm from the sling – which would in principle be more comfortable. Nonetheless, the authors have found this view to be difficult to obtain, especially in the elderly, since it requires leaning the trunk posteriorly with the patient standing; maintaining balance is difficult and limb positioning is hindered. The view described by Cleaves⁶ requires the use of a curved chassis, which is not widely available. Faced with these difficulties, the authors identified the need to develop a modification of the Lawrence technique in a position that was more comfortable for the patient and easier to reproduce. The patient's positioning for the radiograph was named the Senna position, in reference to the author and creator of the technique. The incidence described below aims to show, in axial projection, the relationship between the humeral head and glenoid cavity.

Technique

To obtain the present modification of the axillary radiograph, the patient is required to sit with the feet hanging on the radiographic table. Then, the patient is requested to position the open hand of the affected side on the table. Only a small degree of abduction is required. The abduction angle formed between the medial aspect of the arm and the lateral chest should be approximately 30°. The X-rays are pointed to the glenohumeral joint, perpendicular to the table, 60 cm from the shoulder. The chassis with radiographic film is positioned on the table, directly under the shadow formed by the shoulder contour, with its anterior border just behind the greater trochanter of the femur (Fig. 1). It is important to note that the patient's body should slightly lean approximately 10° to the affected side. The trunk should also be tilted back and the patient should be asked to try to accentuate the

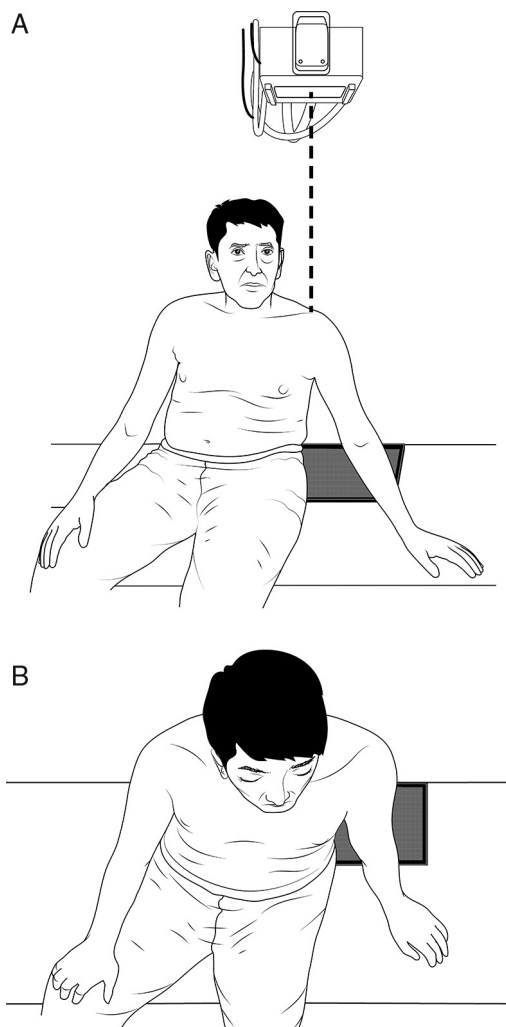


Fig. 1 – Schematic illustration representing the frontal (A) and superior view (B) of the patient and the chassis positioning, as well as the incidence angle of X-rays for the modified axillary radiograph.

thoracic kyphosis. Interestingly, this lateral inclination of the trunk, with accentuation of the thoracic kyphosis, is naturally adopted by most patients suffering from glenohumeral dislocation when seated, which makes the exam easier and less painful for the patient as it respects the natural antalgic position.

Case report

A male 28-year-old mixed-race patient was admitted to the emergency room, walking without assistance, complaining pain, deformity, and functional impairment in his left shoulder after a motorcycle accident. He was lucid and oriented in time and space, with no signs of other injuries and no other complaints. According to the patient, the accident had occurred approximately 30 min before he arrived at the hospital. He denied any previous episode of glenohumeral dislocation or fracture in the region. Physical examination revealed shoulder squaring (epaulet sign) and the patient

Download English Version:

<https://daneshyari.com/en/article/8600489>

Download Persian Version:

<https://daneshyari.com/article/8600489>

[Daneshyari.com](https://daneshyari.com)