




REVISTA BRASILEIRA DE ANESTESIOLOGIA

Publicação Oficial da Sociedade Brasileira de Anestesiologia
www.sba.com.br



CLINICAL INFORMATION

Dissection of the wired endotracheal tube's lumen during general anesthesia: a case report

Fabricio Tavares Mendonça*, Leonardo Damasceno Martins, Rodrigo Gazzi, Jose Tadeu dos Santos Palmieri

Centro de Ensino e Treinamento do Hospital de Base do Distrito Federal, Brasília, DF, Brazil

Received 16 January 2015; accepted 11 February 2015

KEYWORDS

Airway obstruction;
Complication of
intubation;
Obstruction in
ventilation

Abstract

Objective: The aim of this study is to report a case of a clinically significant obstruction during mechanical ventilation caused by the dissection of the wired endotracheal tube's lumen during general anesthesia in a pediatric patient.

Case report: A 12-years old patient undergoing general anesthesia for open appendectomy was intubated with a wired endotracheal tube and difficult removal of the guide. After starting the mechanical ventilation, there was increased expiratory fraction of CO₂ and need for increased inspiratory pressure. Chance of complications with higher incidences were raised and treated unsuccessfully. Finally, during patient reintubation, the dissection of the endotracheal tube lumen was observed, and ventilation was restored to normal.

Conclusion: Anesthesia involves numerous possible complications. Suspicion and constant vigilance are essential for early diagnosis and treatment of any threat to the individual integrity. This case is relevant for emphasizing a possible very rare complication related to airway, which can quickly cause hypoxia and irreversible damage. Thus, this case contributes to the detection of this complication more frequently.

© 2015 Sociedade Brasileira de Anestesiologia. Published by Elsevier Editora Ltda.

PALAVRAS-CHAVE

Obstrução de via
aérea;
Complicação na
intubação;
Obstrução na
ventilação

Dissecção de lúmen de tubo endotraqueal aramado durante anestesia geral: relato de caso

Resumo

Objetivo: Relatar um caso de obstrução à ventilação mecânica clinicamente significativa causada por dissecção do lúmen do tubo endotraqueal aramado durante anestesia geral em um paciente pediátrico.

* Corresponding author.

E-mails: fabriciotmendonca@hotmail.com, fabricio.tavares@me.com (F.T. Mendonça).

Relato: Paciente de 12 anos submetido à anestesia geral para apendicectomia aberta foi intubado com tubo endotraqueal aramado e retirada de guia do tubo difícil. Após iniciar a ventilação mecânica houve aumento da fração expiratória de CO₂ e necessidade de aumento da pressão inspiratória. Hipóteses de complicações com maiores incidências foram aventadas e tratadas sem sucesso. Finalmente, ao reintubar o doente, foi verificada dissecação do lúmen do tubo endotraqueal e a ventilação foi restaurada à normalidade.

Conclusão: O ato anestésico envolve inúmeras possíveis complicações. A suspeição e a vigilância constantes são essenciais para diagnosticar e tratar precocemente qualquer ameaça à integridade do indivíduo. O presente caso é relevante por enfatizar uma possível complicação muito incomum relacionada às vias aéreas capaz de causar hipóxia e danos irreversíveis rapidamente. Dessa forma, o caso contribui para que essa intercorrência seja detectada com maior frequência.

© 2015 Sociedade Brasileira de Anestesiologia. Publicado por Elsevier Editora Ltda.

Introduction

Tracheal intubation in general anesthesia is an essential technique for numerous surgical procedures. Airway protection and mechanical ventilation enable the safe administration of anesthetics to ensure adequate hypnosis, pain inhibition, and muscle relaxation.¹

However, the use of this technique depends on the correct operation of a set of equipment and materials related to the anesthesia. Any defect in any of these materials can compromise the intubation technique and determine a potentially tragic event due to ventilation problem and airway protection. Defects may appear anywhere on the ventilator (bellow, corrugated pipe, capnography, gas input) and endotracheal tube (mucus, foreign body, kinking, cuff herniation or leakage). Because the problem manifestation is common to several clinical complications, it is often not readily identified and corrected, which leads to rapid deterioration of respiratory symptoms and may lead to death.²

We report an uncommon case of deformity and obstruction of the wired endotracheal tube caused by a very difficult removal of the guide wire inserted into the tube.

Case report

Male patient, 12 years old, 35 kg, referred to the operation room (OR) by the emergency service to receive an open appendectomy. He arrived at the OR accompanied by his mother who denied allergies, comorbidities or regular use of medications. Patient's physical status ASA I, HR 110 bpm, blood pressure (BP) 108 × 52 mmHg, SpO₂ 96% in room air; good general condition normal skin color, mild dehydration, eupneic, lucid and oriented. Regarding airway, he had appropriate mouth opening and neck mobility (Mallampati I).

Intravenous infusion was made in left arm with Jelco 20G. After intravenous induction with fentanyl (250 mcg), lidocaine (20 mg), propofol (110 mg) and cisatracurium (7 mg), ventilation under face mask was started.

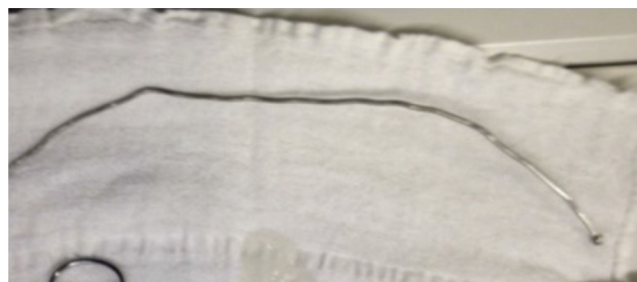

Figure 1 The guide wire used.

After intubation with the help of a Macintosh curved blade #3 and the introduction of the wired endotracheal tube (ETT) #6, the tube guide was removed with great difficulty (Fig. 1). The cuff was inflated and confirmed the position by symmetrical bilateral auscultation and compatible capnographic curve.

Coupled to the automatic mechanical ventilator in the PCV mode, the inspired pressure was 17 cmH₂O at respiratory rate (RR) 16 rpm and positive end expiratory pressure (PEEP) 5 cmH₂O, FiO₂ 40% with 3% sevoflurane. After 20 min, a tidal volume of 120 mL was seen. Therefore, the inspired pressure was increased to 25 cmH₂O to obtain a tidal volume of 280 mL. Subsequently, the gas analyzer indicated increasing rate of ET-CO₂ up to 68 mmHg. Symmetrical and bilateral auscultation was performed, with reduction of murmurs. Administration of ketamine IV (25 mg), did not change the ventilatory pattern. RR was reduced to 10 rpm and a ratio of 1:5 in expiratory time.

After collecting arterial blood gases, intravenous propofol (50 mg) was administered as well as an increasing fraction of inspired sevoflurane. At that point, BP was 97 × 54 mmHg. Arterial blood gas measurement showed pH 7.2; PCO₂ 56.6 mmHg; HCO₃⁻ 22.3; Hb 10.7; Na⁺ 143; K⁺ 3.9; Cl⁻ 101; Ca²⁺ 0.7.

It was decided to change the endotracheal tube to another wired #6. Intubation was performed with no difficulties. The patient was coupled to the ventilator in PCV mode with inspired pressure of 16 cmH₂O and tidal volume

Download English Version:

<https://daneshyari.com/en/article/8611950>

Download Persian Version:

<https://daneshyari.com/article/8611950>

[Daneshyari.com](https://daneshyari.com)