



Egyptian Society of Anesthesiologists
Egyptian Journal of Anaesthesia

www.elsevier.com/locate/egja
www.sciencedirect.com



Case report

Giant paraganglioma in a child: Medical and anaesthetic concerns

Alka Gupta ^{*}, Jasvinder K. Kohli, Sukhyanti Kerai, Namita Arora

Department of Anaesthesiology, PGIMER & Dr. RML Hospital, New Delhi, India

Received 27 August 2015; accepted 12 August 2016

KEYWORDS

Anaesthesia;
 Giant;
 Paraganglioma;
 Paediatrics

Abstract Paraganglioma is a rare neuroendocrine catecholamine producing tumour in childhood which arises outside the adrenal medulla. We present a 12 year old girl with giant paraganglioma with severe hypertension and end organ damage. Diagnosis was confirmed with 24 h urinary Vanillylmandelic Acid (VMA) and CT scan. Preoperative blood pressure was controlled with intravenous nitroprusside, and oral prazosin, amlodipine, labetalol and metoprolol. General anaesthesia with epidural analgesia was given. Intra operative blood pressure rise was managed with infusion of nitroglycerine (NTG), esmolol, nitroprusside and propofol.

© 2016 Publishing services by Elsevier B.V. on behalf of Egyptian Society of Anesthesiologists. This is an open access article under the CC BY-NC-ND license (<http://creativecommons.org/licenses/by-nc-nd/4.0/>).

1. Introduction

Paragangliomas are tumours derived from specialized chemoreceptor tissue nest, thought to be of neural crest origin outside the adrenal medulla [1]. They can arise in posterior mediastinum, retro-peritoneum in general, the base of skull, neck and vagal aortic bodies. It most commonly presents with paroxysmal spells of headache, sweating, palpitations and hypertension. Early diagnosis with aggressive peri operative management is required for reducing morbidity and mortality. Twenty-eight per cent of these tumours are bilateral, malignant and occur in children. In childhood, these tumours are more prevalent in boys than in girls, but trend reverses during

adolescence with greater tendency for familial occurrence [2–4]. This case report describes peri-operative anaesthetic management in a child with giant paraganglioma which had encased the aortic adventitia, inferior vena cava (IVC) and portal vessels.

2. Case history

A 12 year old girl presented in hypertensive crisis with fronto-temporal headache for 1 month and blurring of vision and palpitation for 15 days. On examination, blood pressure (BP) was 196/160 mmHg. Cardiovascular examination revealed systolic murmur. Fundus examination showed hypertensive retinopathy with optic disk oedema in both eyes. A 10 × 8 cm smooth, fixed, hard retro-peritoneal lump was felt on abdominal palpation. Paraganglioma was confirmed on CECT abdomen which showed a heterogeneous 10 × 8 × 5 cm mass in right para-aortic region encasing aorta (Fig. 1). Metaiodobenzylguanidine (MIBG) scan showed MIBG concentrating tumour. Gallium-68 dotatate Positron emission tomogram (PET) scan showed a retro peritoneal mass extending from superior

^{*} Corresponding author at: Department of Anaesthesiology & Intensive Care, PGIMER & Dr. Ram Manohar Lohia Hospital, Baba Kharak Singh Marg, Near Gurudwara Bangla Sahib, Connaught Place, New Delhi, Delhi 110001, India. Tel.: +91 1164552628. E-mail address: alkagupta_rml@yahoo.co.in (A. Gupta).

Peer review under responsibility of Egyptian Society of Anesthesiologists.

<http://dx.doi.org/10.1016/j.egja.2016.08.004>

1110-1849 © 2016 Publishing services by Elsevier B.V. on behalf of Egyptian Society of Anesthesiologists.

This is an open access article under the CC BY-NC-ND license (<http://creativecommons.org/licenses/by-nc-nd/4.0/>).

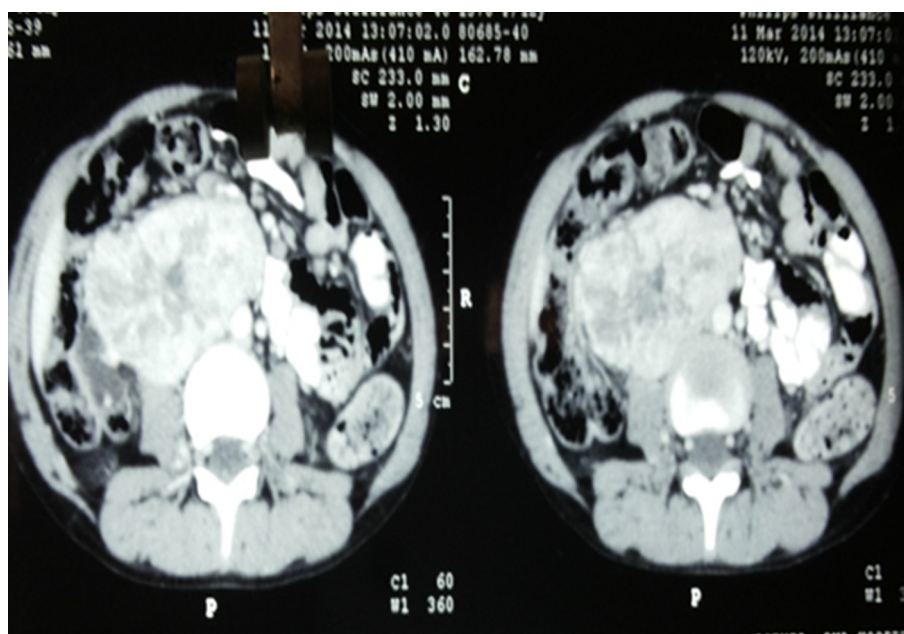


Figure 1

mesenteric artery (SMA) to L4/5 vertebrae level. The 24 h urinary analysis showed VMA to creatinine ratio of 71.33 mg/g creatinine [normal 1.5–5.1] and metanephrine 63.8 μ g [25–31.2]. CT head did not reveal any metastasis. Thyroid function test and S. Calcium were found to be normal. Pre-operative stabilization was done with intravenous nitroprusside and furosemide and maintained on prazosin 5 mg tid, amlodipin 50 mg bid, labetalol 75 mg bid and metoprolol 5 mg bid. The child was taken up for excision of tumour with blood pressure of 140/90 mmHg and heart rate of 90/min. The medications were continued till the morning of surgery. As the paraganglioma was encasing the major vessels of abdominal cavity including aorta, IVC and portal vessels, a cardiopulmonary bypass machine was kept ready in case of any eventuality. In the operation room, intravenous line of 18 g was secured. Fentanyl 50 μ g, midazolam 1 mg and hydrocortisone 50 mg were administered intra venously. All the standard monitors were attached. Left radial artery cannulation was done under local anaesthesia. After pre-oxygenation, anaesthesia was induced with propofol 2 mg/kg, fentanyl 2 μ g/kg, vecuronium bromide 0.1 mg/kg, nitrous oxide:oxygen [60:40] and isoflurane 1%. Trachea was intubated with 6.5 mm cuffed endotracheal tube. Before intubation, vocal cords were sprayed with 10% lignocaine and intravenous Xylocard 30 mg was also given. Blood pressure rose to 180/110 mmHg after intubation which was controlled with bolus dose of propofol and isoflurane 2%. Internal jugular vein cannulation was performed with 5.5 Fr double lumen catheter. Epidural catheter 19G was inserted at L₃₋₄ intervertebral space and 6 ml of 0.25% bupivacaine was administered in epidural space. Intraoperatively intermittent boluses of 3–4 ml of 0.25% bupivacaine was given hourly. Maintenance was done with 60% nitrous oxide in oxygen, isoflurane 1–2%, and intermittent vecuronium. Infusion of NTG 0.5 μ g/kg/min and esmolol 50–100 μ g/kg/min was started to control intra operative rise of BP and heart rate.

Nitroprusside and propofol infusion was started during tumour manipulation. The BP did not rise beyond 190/110 mm HG, and heart rate went up to 110/min even during the tumour manipulation. But there was precipitous fall of BP to 80 mmHg after tumour resection; immediately, we discontinued infusions of esmolol, nitroglycerin, nitroprusside and propofol. To restore the blood pressure dopamine infusion was also started at 5 μ g/kg/min and blood products, crystalloids and colloids were given. Arterial blood gas analysis showed a hematocrit of 25% and moderate acidosis. The blood loss was around 1.5 l. Fluid administered was 4 l of crystalloid, 1500 ml of blood and 2 units of fresh frozen plasma. Urine output was adequate. CVP was maintained at 7–8 cm of water and temperature was 35 °C. Tumour was shaved from inferior vena cava, aorta and portal structures successfully (Fig. 2). BP was normalized before sending the patient to ICU for elective ventilation with dopamine infusion. At 6 month follow-up the child was normotensive, recurrence free and normal urinary VMA.

3. Discussion

Paragangliomas arise from neural crest and are usually syndromic [MEN II, Von-Hippel-Lindau, NF-1, etc.]. The well-known '10%' rule does not apply to paediatric paragangliomas. In children, they are more likely to be extra-adrenal, malignant, recurrent syndromic and bilateral. Hypertension due to paraganglioma in children is more severe and refractory than in adults [5]. Paraganglioma secretes mainly norepinephrine. It is seen more commonly in pre adolescent boys and teenage girls with male preponderance 2:1 [2]. Manifestations are seen due to paroxysmal or sustained release of norepinephrine resulting in constriction of arteriolar and venous segment thereby decreasing the circulatory blood vol-

Download English Version:

<https://daneshyari.com/en/article/8616775>

Download Persian Version:

<https://daneshyari.com/article/8616775>

[Daneshyari.com](https://daneshyari.com)