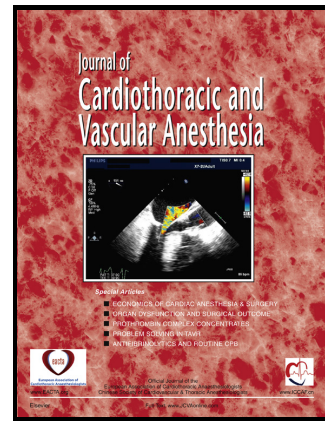


Author's Accepted Manuscript

A new regional wall motion abnormality after aortic dissection repair: What is the next step?

Stephen H. Gregory, Jonathan K. Zoller, Anand Lakshminarasimhachar



PII: S1053-0770(17)30474-3
DOI: <http://dx.doi.org/10.1053/j.jvca.2017.04.050>
Reference: YJCAN4132

To appear in: *Journal of Cardiothoracic and Vascular Anesthesia*

Cite this article as: Stephen H. Gregory, Jonathan K. Zoller and Anand Lakshminarasimhachar, A new regional wall motion abnormality after aortic dissection repair: What is the next step?, *Journal of Cardiothoracic and Vascular Anesthesia*, <http://dx.doi.org/10.1053/j.jvca.2017.04.050>

This is a PDF file of an unedited manuscript that has been accepted for publication. As a service to our customers we are providing this early version of the manuscript. The manuscript will undergo copyediting, typesetting, and review of the resulting galley proof before it is published in its final citable form. Please note that during the production process errors may be discovered which could affect the content, and all legal disclaimers that apply to the journal pertain.

A new regional wall motion abnormality after aortic dissection repair: What is the next step?

1. Author: Stephen H. Gregory, MD₁

- Title: Fellow, Cardiothoracic Anesthesiology
- Email: shgregory@wustl.edu
- Conflicts of Interest: None

2. Author: Jonathan K. Zoller, MD₁

- Title: Fellow, Cardiothoracic Anesthesiology
- Email: zollerj@wustl.edu
- Conflicts of Interest: None

3. Author: Anand Lakshminarasimhachar, MD

- Title: Associate Professor, Anesthesiology
- Email: lakshmia@wustl.edu
- Conflicts of Interest: None

1. Department of Anesthesiology, Washington University in St. Louis. Campus Box 8054. 660 S. Euclid Ave. St. Louis, MO 63110

Corresponding Author:

Name: Stephen H. Gregory, MD

Department: Department of Anesthesiology

Institution: Washington University in St. Louis

Mailing address: Campus Box 8054. 660 S. Euclid Ave. St. Louis, MO 63110

Phone: 1-618-578-8280

Email: shgregory@wustl.edu

Funding: No funding was used in the construction of this manuscript.

Introduction:

The management of the patient presenting with an ascending aortic dissection represents a significant clinical challenge, with multiple acute and subacute complications that may present during perioperative management. Myocardial ischemia is a known complication of aortic dissection, with the

Download English Version:

<https://daneshyari.com/en/article/8619073>

Download Persian Version:

<https://daneshyari.com/article/8619073>

[Daneshyari.com](https://daneshyari.com)