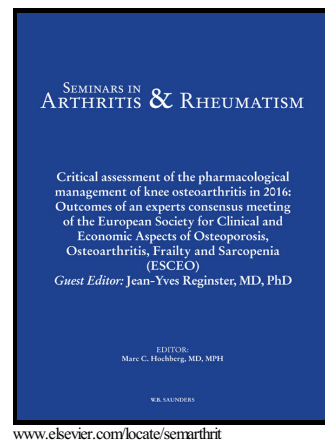


Author's Accepted Manuscript

Clinical and imaging mimickers of axial spondyloarthritis

Gleb Slobodin, Merav Lidar, Iris Eshed



PII: S0049-0172(17)30194-4
DOI: <http://dx.doi.org/10.1016/j.semarthrit.2017.05.009>
Reference: YSARH51199

To appear in: *Seminars in Arthritis and Rheumatism*

Cite this article as: Gleb Slobodin, Merav Lidar and Iris Eshed, Clinical and imaging mimickers of axial spondyloarthritis, *Seminars in Arthritis and Rheumatism*, <http://dx.doi.org/10.1016/j.semarthrit.2017.05.009>

This is a PDF file of an unedited manuscript that has been accepted for publication. As a service to our customers we are providing this early version of the manuscript. The manuscript will undergo copyediting, typesetting, and review of the resulting galley proof before it is published in its final citable form. Please note that during the production process errors may be discovered which could affect the content, and all legal disclaimers that apply to the journal pertain.

Clinical and Imaging Mimickers of Axial Spondyloarthritis

Gleb Slobodin¹, Merav Lidar² and Iris Eshed³

¹ Rheumatology Unit, Bnai Zion Medical Center and Ruth and Bruce Rappaport
Faculty of Medicine, Technion, Haifa, Israel

² Rheumatology Unit, Sheba Medical Center, Tel Hashomer, and the Sackler Faculty
of Medicine, Tel Aviv University, Tel Aviv, Israel

³ Department of Diagnostic Imaging, Sheba Medical Center, Tel Hashomer, and the
Sackler Faculty of Medicine, Tel Aviv University, Israel

Correspondence: Gleb Slobodin, MD, Rheumatology, Bnai Zion Medical Center,
47 Golomb St, Haifa, Israel, 38041 gslobodin@yahoo.com

Disclosures: NONE

Download English Version:

<https://daneshyari.com/en/article/8623845>

Download Persian Version:

<https://daneshyari.com/article/8623845>

[Daneshyari.com](https://daneshyari.com)