

## CASE REPORT

## Management of Endurance Athletes with Flow Limitation in the Iliac Arteries: A Case Series

Assad Khan, Marwan Al-Dawoud, Robert Salaman, Haytham Al-Khaffaf \*

Department of Vascular Surgery, East Lancashire Hospitals NHS Trust, Royal Blackburn Teaching Hospital, Blackburn, UK

**Introduction:** Vascular surgeons increasingly encounter flow limitation of iliac arteries (FLIA) in endurance athletes. An experience of managing this condition is reported.

**Report:** This is a retrospective cohort analysis of prospectively collected data at a single vascular centre. Between 2001 and 2017, 12 athletes with exercise induced pain underwent investigation and assessment. Patients with significant radiological findings (iliac kinking  $\pm$  stenosis demonstrated on duplex ultrasound or catheter angiography) and dynamic flow changes (marked reduction in ankle brachial pressure indices following exertion, or increase in the common iliac artery peak systolic velocity during hip flexion on duplex) underwent surgery after trialling conservative management; the majority were open iliac shortening procedures. Patients with radiological findings, but no dynamic flow changes were managed conservatively. All patients were followed up.

**Discussion:** There were 10 men and two women with a median age of 40 years. Nine patients had iliac kinking (five in isolation, four associated with stenosis), two had stenosis, and one had no iliac disease. Eight patients had severe symptoms (absolute loss of power on maximal exertion) demonstrated dynamic post-exertional flow changes. Seven patients successfully underwent surgery, returning to their sport at similar intensity. One procedure was abandoned owing to severe adhesions from a prior procedure. This patient subsequently changed sport. Three patients with mild symptoms (two had reduction in power at maximal intensity, one was an incidental finding) and who demonstrated no clinical signs of FLIA continued their sport at a lower intensity. Kinking of the iliac arteries in athletes can occur with or without of iliac stenosis. Patients with the most severe iliac symptoms demonstrate dynamic post-exertional flow limitation and may benefit from surgery following a period of conservative management. Patients who have milder symptoms and no dynamic exercise flow limitations can be managed conservatively.

© 2018 The Authors. Published by Elsevier Ltd on behalf of European Society for Vascular Surgery. This is an open access article under the CC BY-NC-ND license (<http://creativecommons.org/licenses/by-nc-nd/4.0/>).

Article history: Received 18 March 2018, Revised 15 June 2018, Accepted 18 June 2018,

**Keywords:** Athletes, Endofibrosis, FLIA, Iliac disease, Iliac kinking

### INTRODUCTION

Pain, loss of power, and/or cramp at maximal effort that resolves upon resting are established as symptoms of underlying flow limitations in the iliac arteries (FLIA).<sup>1</sup> Chevalier et al. first suggested that non-atherosclerotic disease could be the cause of FLIA in athletes, owing to vessel stenosis caused by endofibrosis or kinking of the iliac artery, or a combination of both.<sup>2,3</sup> The pathogenesis of the condition typically affects cyclists because of the hyperflexed hip in the cycling position, followed by aggressive and repetitive flexion and extension. This motion stretches the iliac artery, leading to iliac kinking and can result in FLIA.<sup>2,4–</sup>

<sup>6</sup> Repeated trauma produces a cellular response due to increase in haemodynamic load on the vessel wall, provoking intimal thickening causing stenosis, described as “endofibrosis”.<sup>7</sup>

In such patients, physical examination and conventional investigations are often normal and provocative tests may be required.<sup>8</sup> This paper reports an experience in the diagnosis and management of several athletes suffering disease of the iliac arteries.

### Design

This is a retrospective cohort analysis of prospectively collected data involving all patients experiencing FLIA referred to a single vascular service, managed by the senior authors between the years of 2001 and 2017.

### MATERIALS AND METHODS

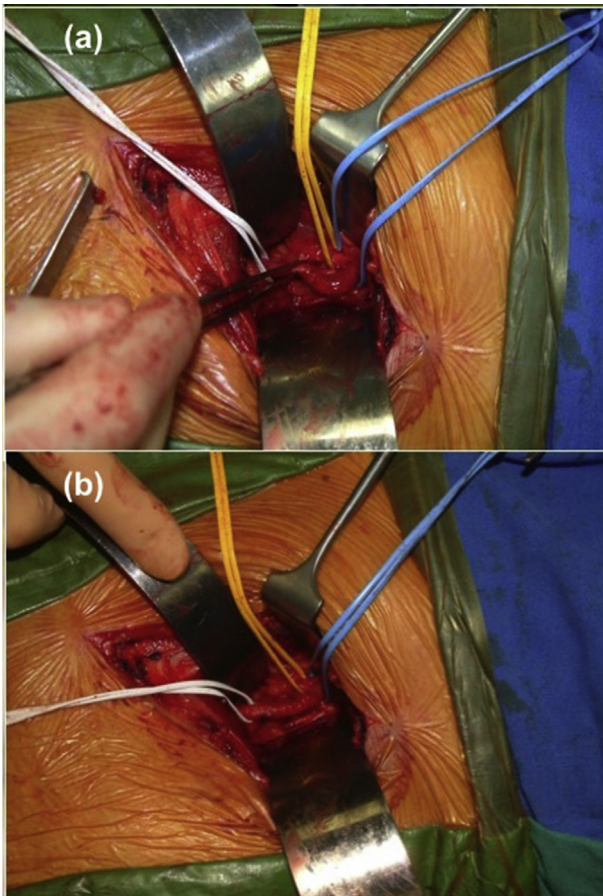
Patients were included if they participated in sports competitively and had symptoms of claudication or loss of power during high intensity exercise with resolution upon

\* Corresponding author. Department of Vascular Surgery, East Lancashire Hospitals NHS Trust, Royal Blackburn Hospital, Haslingden Road, Blackburn BB2 3HH, UK.

E-mail address: [haytham.al-khaffaf@elht.nhs.uk](mailto:haytham.al-khaffaf@elht.nhs.uk) (Haytham Al-Khaffaf).

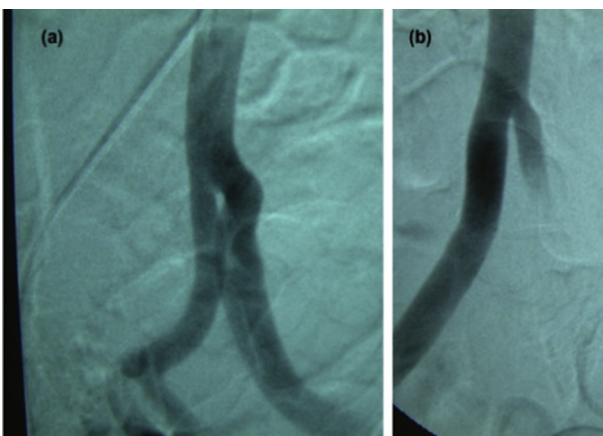
2405-6553/© 2018 The Authors. Published by Elsevier Ltd on behalf of European Society for Vascular Surgery. This is an open access article under the CC BY-NC-ND license (<http://creativecommons.org/licenses/by-nc-nd/4.0/>).

<https://doi.org/10.1016/j.ejvsr.2018.06.001>



**Figure 1.** Operative technique. (a) Open approach (via a Rutherford Morison incision) to the common iliac artery demonstrating iliac kinking even with the patient supine and the hip extended. (b) Excision of the iliac artery. Anastomosis between the two ends displays no tortuosity.

resting. Patients were excluded if they had other comorbidities contributing to arterial disease or atherosclerosis in other vascular territories. All patients, except one, were assessed using provocative tests, in the form of pre- and



**Figure 2.** Pre- and post-operative catheter angiography demonstrating the presence of iliac kinking without stenosis. (a) Angulation without vessel calibre change. (b) Post-operative reduction in angulation with no appreciable difference in diameter.

post-exercise ankle brachial pressure indices (ABPI) performed on a static exercise bike for cyclists, and treadmill at 5.4 miles per hour at a 15% incline for the single runner in the series. The iliac arteries were radiologically assessed by both duplex ultrasound (DUS) and conventional catheter angiography (via contralateral femoral puncture) with the leg extended and in 90° hip flexion (Fig. 2). Patients were discussed in a multidisciplinary team meeting; patients who demonstrated “symptomatic FLIA”, i.e., a significant iliac tortuosity or stenosis demonstrating flow limitation on post-exercise ABPI, proceeded to surgery after a trial of conservative measures. Patients were extensively counselled about the risks of the procedure, including pseudoaneurysm formation, graft infection (where appropriate), disease progression/recurrence, and limb loss.

The preferential surgical technique was open iliac artery excision with a spatulated end to end anastomosis (Fig. 1a and b). Patients with hostile anatomy underwent ilio-femoral “jump” bypass grafts using Dacron. All patients, irrespective of management, were followed up in the vascular clinic.

## RESULTS

Twelve patients (median age 40 years; 10 men [83%] and two women [17%]) were included in the study; 11 were cyclists (92%) and one was a runner (8%). Eleven patients suffered with limiting symptoms; eight patients (67%) experienced severe symptoms (absolute loss of power at maximal exertional intensity): four in the left leg, two in the right leg, and one in both legs. Three patients (25%) suffered with less severe symptoms (a reduction in power on exertion), allowing them to continue cycling, and one patient was asymptomatic (8%).

The predominant radiological finding was iliac kinking, which was present in nine patients: five had isolated kinking and four had kinking with associated stenosis. Two people had stenosis in isolation and one patient (8%) had no identifiable arterial disease.

Nine patients had no previous intervention for iliac disease (75%); two patients had undergone previous treatment for iliac stenosis but remained symptomatic (17%). One patient previously underwent iliac thrombectomy after a cycling session and had an asymptomatic contralateral kink detected incidentally during angiography.

Patients with severe exertional symptoms had a post-exertional ABPI < 1, with the exception of one patient in whom ABPI was not recorded. All patients with less debilitating symptoms had an ABPI > 1 (Table 1).

In terms of management, six patients underwent iliac excision (50%); one had bilateral disease treated and thus seven arteries were treated. One procedure was abandoned because of adhesions around the iliac artery from previous surgery. Two patients underwent an iliofemoral bypass because of hostile anatomy (one patient had iliac stenting and one had an open ileo-caecotomy for complicated appendicitis). From the histology specimens available, five affected arteries demonstrated no evidence of intimal hyperplasia and two showed changes in keeping with

Download English Version:

<https://daneshyari.com/en/article/8659188>

Download Persian Version:

<https://daneshyari.com/article/8659188>

[Daneshyari.com](https://daneshyari.com)