

Syncope on exertion in a young male

Julia W. Erath, MD,^{*} Valentina O. Puntmann, MD, PhD,[†] Emmanouil Chavakis, MD,^{*} Stefan H. Hohnloser, MD, FHRS, FESC, FACC^{*}

From the ^{*}Department of Cardiology, J.W. Goethe University, Frankfurt am Main, Germany, and

[†]Department of Cardiovascular Imaging, J.W. Goethe University, Frankfurt am Main, Germany.

Introduction

Cardiac sarcoidosis is a rare immunologic disease causing heart involvement in 5% of patients.¹ Cardiac sarcoidosis may manifest clinically as a cardiomyopathy with impaired left ventricular (LV) function or as tachyarrhythmias or bradyarrhythmias.² On autopsy, cardiac granulomas can be found in approximately 25% of patients. The most common location for granulomas and scars is the LV free wall, followed by the intraventricular septum, often with involvement of the conduction system.^{3,4}

Case report

We report the case of a 34-year-old man presenting with a history of recurrent syncope on exertion. At rest, 12-lead electrocardiogram (ECG) showed first-degree atrioventricular (AV) block with undisturbed intraventricular conduction (Figure 1A). On exercise treadmill testing (Figure 1B), second-degree AV block with 2:1 AV conduction occurred with increasing workload at 100 W, suggesting infra-Hisian block (Figure 1C). Long-term ECG monitoring 1 day later demonstrated intermittent third-degree AV block (Figure 1D). Echocardiography showed both mildly impaired right ventricular (RV) and LV function (RV ejection fraction = 47%, LV ejection fraction [LVEF] = 54%) but normal diameters and mild tricuspid regurgitation. As the etiology of the underlying heart disease remained unclear, cardiac magnetic resonance (CMR) with late gadolinium enhancement (LGE) was performed (Figure 2).

CMR imaging revealed moderately reduced LV global systolic function (LVEF = 45%) with sharply demarcated intramyocardial enhancement within the mid-anterior septal segment, corresponding to the region of the bundle of His (Figure 2A). In addition, remote native T1 and T2 mapping

values were elevated, consistent with the presence of myocardial inflammation. Together with bihilar lymphadenopathy on CMR, the findings were highly suggestive of cardiac involvement in a patient with systemic sarcoidosis. Subsequent bronchoalveolar lavage revealed an increased CD4/CD8 lymphocyte ratio, and lung and paratracheal lymph node biopsy provided the histologic proof of noncaseating granuloma. Subsequently, a 2-chamber pacemaker was implanted and the patient started on high-dose steroid therapy (1 mg per kg body weight per day).⁵ Two months after therapy initiation, pacemaker interrogation showed predominantly physiological AV conduction with only occasional need for ventricular pacing. On repeated CMR imaging, myocardial native T1 and T2 were almost normalized with less late gadolinium-enhanced myocardium (Figure 2B).

Discussion

Progressive AV-nodal conduction disturbances are a hallmark of cardiac sarcoidosis.^{1,2} The present case illustrates the importance of a multidisciplinary approach to establishing the diagnosis of this disease entity. Collaboration between electrophysiologists, magnetic resonance imaging specialists, and pulmonologists enables a timely diagnosis and appropriate therapy.

Diagnosis

Cardiac sarcoidosis should be suspected in young and middle-aged patients (<50 years) presenting with unexplained syncope in the setting of AV conduction abnormalities and/or ventricular arrhythmias with or without heart failure.^{1,2,5} All patients with extracardiac sarcoidosis are recommended to be actively screened for cardiac involvement by electrocardiography and echocardiography.^{1,5} Although there are no pathognomonic diagnostic criteria to date, abnormal thinning or thickening of the septal wall, wall motion abnormalities not corresponding to a coronary region, and systolic or diastolic dysfunction, as well as pericardial effusion, might be present in cardiac sarcoidosis.^{1,2} If either a patient's history or electrocardiography or echocardiography is positive for cardiac sarcoidosis, further diagnostic testing with CMR imaging is recommended owing to a Heart Rhythm Society consensus statement of

KEYWORDS Cardiac magnetic resonance; Complete heart block; Pacemaker; Sarcoidosis; Syncope
(Heart Rhythm Case Reports 2018; ■:1–4)

Address reprint requests and correspondence: Dr Stefan H. Hohnloser, University Hospital Frankfurt Goethe University, Department of Cardiology, Division of Clinical Electrophysiology, Theodor-Stern-Kai 7, D 60590 Frankfurt, Germany. E-mail address: hohnloser@em.uni-frankfurt.de.

KEY TEACHING POINTS

- Young patients with syncope, especially on exertion, should undergo provocative exercise testing.
- Inflammatory cardiac disease might be the cause for transient complete heart block.
- Cardiac magnetic resonance imaging is a suitable tool to monitor myocardial involvement on first presentation and during follow-up.

2014.⁵ Apart from myocardial thickening and/or wall motion abnormalities, enhanced T1 and T2 signal as markers for inflammation and edema⁴ can be found in the setting of sarcoidosis, especially in an early, clinically silent stage. Furthermore, LGE might visualize granuloma or scarring, often found in a patchy distribution.⁴ Compared to fluorodeoxyglucose positron emission tomography, CMR imaging was considered to be of better specificity but worse sensitivity. Newer observational studies found that an optimal magnetic resonance imaging technique adjudged by an expert cardiologist and radiologist can yield a sensitivity of 100% to diagnose cardiac sarcoidosis.¹ Endomyocardial biopsy can confirm cardiac involvement in systemic sarcoidosis, but owing to the disseminated granulomatous infiltration, only 25% of cardiac biopsies in patients with cardiac sarcoidosis are positive.³ That is why extracardiac biopsies (eg, from pulmonary lymph

nodes or lung tissue) are preferred in patients with systemic sarcoidosis. If only a cardiac manifestation is suspected, an image-guided endomyocardial biopsy (eg, with CMR or 3-dimensional voltage map) is recommended by current consensus statements.⁵ To establish the risk of sudden cardiac death, an electrophysiological study can be performed as a class IIb recommendation in patients with LVEF > 35%, despite optimal medical therapy and a period of immunosuppression, if there is still evidence of active inflammation.⁵ A small prospective study of 75 patients with cardiac sarcoidosis undergoing extensive programmed electrical stimulation demonstrated that event-free survival in patients with inducible ventricular arrhythmia on programmed electrical stimulation is significantly lower.

Treatment

Owing to the scarcity of data, it is still unknown whether only patients with myocardial inflammation and signs of active sarcoidosis or all patients with sarcoidosis, even in clinically silent stages, should be treated. There are no randomized, prospective data on treatment with corticosteroids. A recently initiated randomized controlled trial, the CASTOR study, had to be closed owing to a lack of funding. Small cohort studies report improvement in AV conduction as well as in LV function in patients with initially severely depressed LVEF (<35%), but no regeneration in patients with moderately impaired LVEF under immunosuppressive therapy with corticosteroids.^{1,2} The current expert consensus paper recommends immunosuppression as a class IIa recommendation in patients with AV block type II

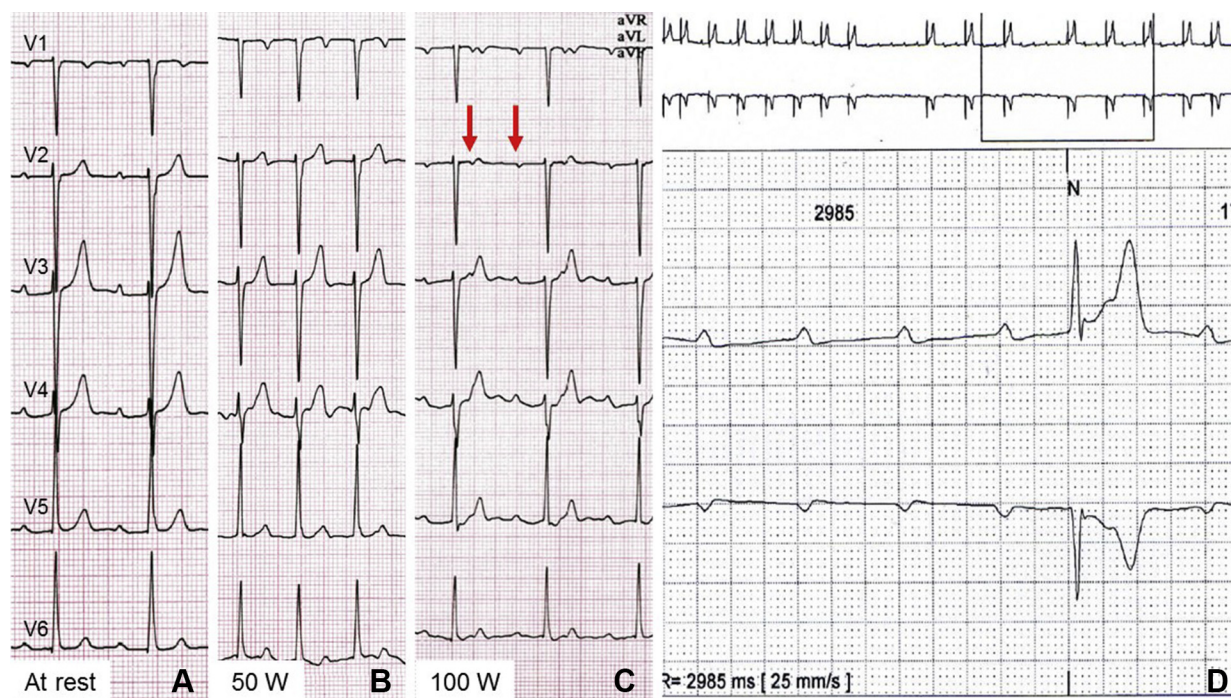


Figure 1 Electrocardiogram at 25 mm/s paper speed at rest (A), at exercise 50 W (B), at exercise 100 W (C), and during Holter monitoring (D).

Download English Version:

<https://daneshyari.com/en/article/8660462>

Download Persian Version:

<https://daneshyari.com/article/8660462>

[Daneshyari.com](https://daneshyari.com)