

# Atrial flutter following ethanol infusion in the vein of Marshall



Tadashi Hoshiyama, MD,\* Keiichi Ashikaga, MD,\* Kana Nakashima, MD,\*  
Kenichi Tsujita, MD,† Yoshisato Shibata, MD\*

From the \*Miyazaki Medical Association Hospital Cardiovascular Center, Miyazaki, Japan, and  
†Department of Cardiovascular Medicine, Graduate School of Medical Sciences, Kumamoto  
University, Kumamoto, Japan.

## Introduction

Perimitral flutter rotates around the mitral annulus, and it is sometimes observed after catheter ablation for atrial fibrillation.<sup>1</sup> Linear ablation from the mitral annulus to the left inferior pulmonary vein (the so-called mitral isthmus) to obtain bidirectional block is the most common therapy to terminate this flutter.<sup>2</sup> However, it has been shown that obtaining complete bidirectional block by only radiofrequency catheter ablation is technically difficult.<sup>2</sup> Therefore, some catheter ablation methods have been proposed to achieve complete bidirectional block. Ethanol infusion in the vein of Marshall (VOM) is one of the methods to achieve complete bidirectional block of the mitral isthmus.<sup>3</sup> This technique forms a scar lesion at the mitral isthmus that corresponds to the anatomic location of the VOM.<sup>4</sup> However, an incomplete lesion may create a slow conduction zone that leads to another reentry circuit. In this report, we encountered a patient with uncommon flutter after previous radiofrequency catheter ablation that included ethanol infusion in the VOM for perimitral flutter. However, based on an electrophysiological study and 3-dimensional activation map of the left atrium, the uncommon flutter was not perimitral flutter, as it rotated around the left atrial appendage (LAA). Furthermore, the fractionated potential and low-voltage electrograms forming the critical isthmus were located between the left pulmonary vein (LPV) and LAA, where only scar area was observed after ethanol infusion in the VOM. The critical isthmus may have been formed secondary to the low-voltage area by ethanol infusion in the VOM.

## Case report

An 83-year-old woman was referred to our hospital for palpitation. Double valve replacement had been performed for severe

---

**KEYWORDS** Atrial flutter; Chemical ablation; Proarrhythmia; Uncommon flutter; Vein of Marshall  
(Heart Rhythm Case Reports 2018;4:155–158)

---

**Address reprint requests and correspondence:** Dr Tadashi Hoshiyama, Miyazaki Medical Association Hospital Cardiovascular Center, 738-1 Funado, Shinbeppu, Miyazaki, 880-0834 Japan. E-mail address: [tadashi@kumamoto-u.ac.jp](mailto:tadashi@kumamoto-u.ac.jp).

aortic stenosis and mitral regurgitation 5 years prior. She had a history of 2 catheter ablations in the past 2 years, which included a pulmonary vein isolation for paroxysmal atrial fibrillation, linear ablation of left atrial roof for roof-dependent flutter, linear ablation of cavotricuspid isthmus for common flutter, and ethanol infusion in the VOM for perimitral flutter. Despite the 2 previous catheter ablations, a 12-lead surface electrocardiogram showed supraventricular tachycardia with an atrial rate of 150 beats per minute (bpm). The morphology of the P wave was similar to that of the previous perimitral flutter. However, the rate was slower (150 bpm) than the rate of 200 bpm at previous perimitral flutter. Therefore, we speculated that an incomplete block line of the mitral isthmus led to the recurrence of the perimitral flutter with a slower rate. She was admitted to our hospital for catheter ablation at a later date.

An activation map of the left atrial electronic anatomic imaging (CARTO 3, Biosense Webster, Irvine, CA) was created using a high-density mapping catheter (PentaRay catheter, Biosense Webster). Based on the caudal view of the electronic anatomic imaging, the tachycardia seemed to be perimitral flutter (Figure 1A). However, the activation map was not consistent with tachycardia cycle length, and the post-pacing interval at the mitral isthmus did not match the tachycardia cycle length (Figure 2A). Upon the addition of the potentials of the left atrium, the tachycardia was ruled out as perimitral flutter and was shown to be macroreentrant tachycardia involving the LAA (Figure 1B). In addition, a slow conduction zone was located between the LPV and LAA (Figure 1B) where the scar area was observed without potentials in the voltage map after ethanol infusion in the VOM in the previous session (Figure 3A). Indeed, the fractionated potential was observed at the site using a high-density mapping catheter (PentaRay catheter, Biosense Webster) (Figure 1C), and the post-pacing interval at the site matched the tachycardia cycle length (Figure 2B). From the above findings, the critical isthmus was located between the LPV and LAA. Radiofrequency catheter ablation using a ThermoCool catheter (Biosense Webster) promptly terminated the tachycardia with the extension of the tachycardia cycle length. There was no recurrence after radiofrequency catheter ablation.

### KEY TEACHING POINTS

- The critical isthmus of atrial flutter, which is formed secondary to the low-voltage area created by ethanol infusion in the vein of Marshall (VOM), is rare.
- It should be noted that although ethanol infusion in the VOM is effective for perimitral flutter, it may create another reentrant arrhythmia.
- Additional radiofrequency catheter ablation from the endocardial side may prevent proarrhythmic effect.

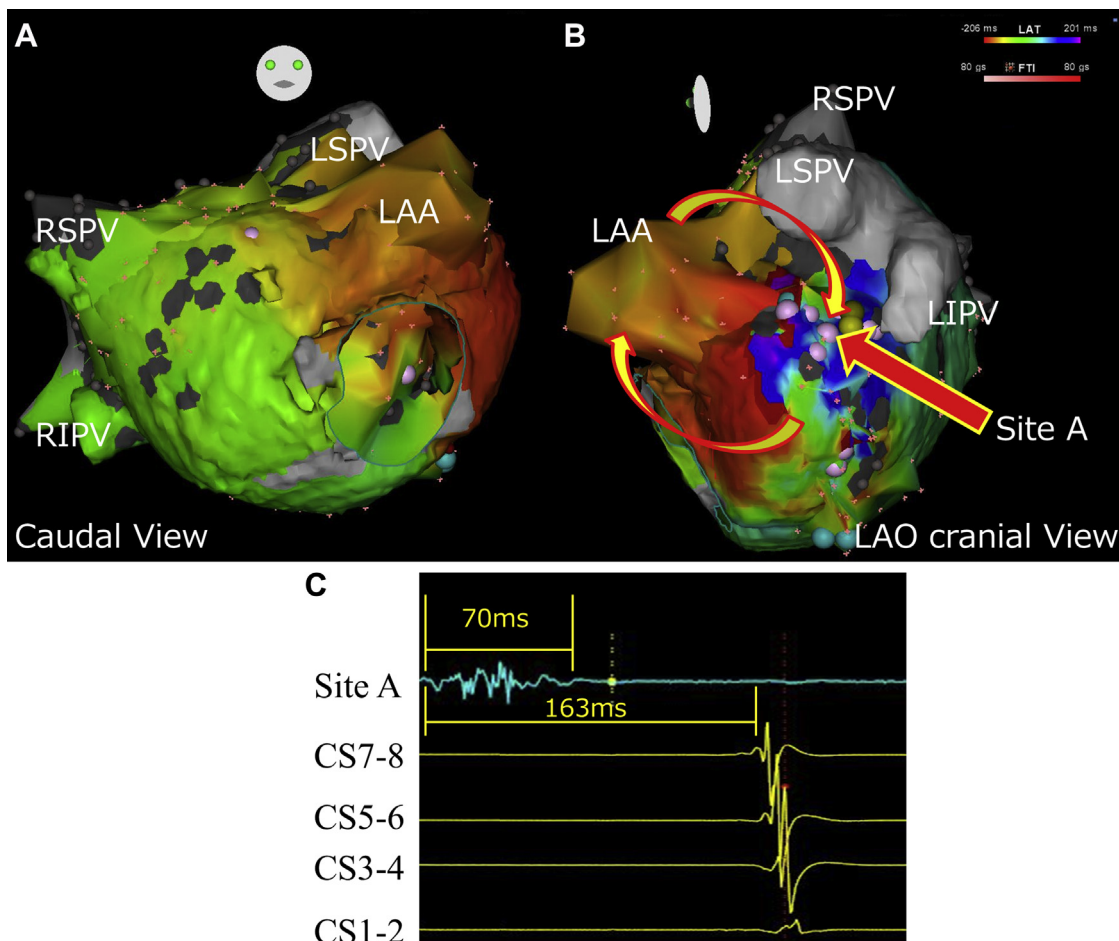
### Discussion

In this case report, we described an uncommon atrial flutter that rotated around the LAA. The critical isthmus was located between the LPV and LAA. Although a scar area without potential was observed at this site after ethanol infusion in the VOM in the previous session, a fractionated potential and low voltage were observed in the present

session. Radiofrequency catheter ablation at the site promptly terminated the tachycardia.

It has been shown that achieving complete bidirectional block of the mitral isthmus by only radiofrequency catheter ablation is technically difficult,<sup>2</sup> and the success rates has been reported to vary over a wide range from 32% to 71%.<sup>5,6</sup> This may be attributed to anatomic complexity of the mitral isthmus. Becker<sup>7</sup> reported on the anatomic aspect that leads to difficulties in creating bidirectional block. In that report, the examination of human hearts obtained autopsy revealed that the wall thickness of the mitral isthmus ranges from 2 to 8 mm, and the great cardiac vein runs on the epicardial side.<sup>7</sup> In addition, Macedo and colleagues<sup>8</sup> reported that the mitral isthmus is consistently located endocardially to the VOM. Vein draining posterior surface of LPV may pass directly through the VOM into coronary sinus.<sup>8</sup> As a result, blood flow may decrease the temperature during radiofrequency catheter ablation. These mechanisms may lead to failure to create a complete lesion.

On the other hand, ethanol infusion in the VOM has been reported to be effective for perimitral flutter<sup>4</sup> owing to formation of a scar area at the mitral isthmus. In fact, voltage maps



**Figure 1** Left atrial activation map: **A:** caudal view; **B:** left anterior oblique (LAO) cranial view. **C:** Intracardiac electrogram between left pulmonary vein and left atrial appendage (LAA) and coronary sinus (CS). Round pink tags in panel B represent where abnormal electrogram was observed. LIPV = left inferior pulmonary vein; LSPV = left superior pulmonary vein; RIPV = right inferior pulmonary vein; RSPV = right superior pulmonary vein.

Download English Version:

<https://daneshyari.com/en/article/8660497>

Download Persian Version:

<https://daneshyari.com/article/8660497>

[Daneshyari.com](https://daneshyari.com)