



Contents lists available at ScienceDirect

Indian Pacing and Electrophysiology Journal

journal homepage: www.elsevier.com/locate/IPEJ

Cardiomyopathy induced by incessant ventricular tachycardia originating in the vicinity of the His bundle

Sana Ouali ^{a,*}, Manel Ben Halima ^a, Selim Boudiche ^a, Anissa Gharbi ^b, Khedher Nadim ^a, Kaouthar Hakim ^c, Fatma Ouarda ^c, Mohamed Sami Mourali ^a

^a Cardiology Department, La Rabta Hospital, Tunisia

^b Cardiology Department, Farhat Hached Hospital, Tunisia

^c Congenital Heart Disease Department, La Rabta Hospital, Tunisia

ARTICLE INFO

Article history:

Received 12 March 2017

Received in revised form

6 August 2017

Accepted 25 October 2017

Available online xxx

Keywords:

Parahisian ventricular tachycardia
Tachycardia mediated cardiomyopathy
Radiofrequency catheter ablation
Children

ABSTRACT

A 04-year-old boy was referred to our institution with severe, progressive heart failure of 4-months duration associated with a persistent wide QRS tachycardia with left bundle branch block and severe left ventricular dysfunction. Because of incessant wide QRS tachycardia refractory to antiarrhythmic drugs, he was referred for electrophysiological study. The ECG was suggestive of VT arising from the right ventricle near the His area. Electrophysiological study revealed that origin of tachycardia was septum of the right ventricle, near His bundle, however the procedure was not successful and an inadvertent complete atrioventricular conduction block occurred. The same ventricular tachycardia recurred. A second procedure was performed with a retrograd aortic approach to map the left side of the inter-ventricular septum. The earliest endocardial site for ablation was localized in the anterobasal region of left ventricle near His bundle. In this location, one radiofrequency pulse interrupted VT and rendered it not inducible. The echocardiographic evaluation showed partial reversal of left ventricular function in the first 3 months. The diagnosis was idiopathic parahisian left ventricular tachycardia leading to a tachycardia mediated cardiomyopathy, an extremely rare clinical picture in children.

Copyright © 2017, Indian Heart Rhythm Society. Production and hosting by Elsevier B.V. This is an open access article under the CC BY-NC-ND license (<http://creativecommons.org/licenses/by-nc-nd/4.0/>).

1. Case report

A 4-year-old boy was referred to our institution with severe, progressive heart failure of 4-months duration associated with a persistent rapid heart rate, ranging from 150 to 180 bpm, despite the use of amiodarone and bisoprolol. The electrocardiogram (ECG) performed during admission showed a regular tachycardia with left bundle-branch block (LBBB) QRS morphology with an atrioventricular dissociation. Echocardiographic evaluation showed left ventricle (LV) enlargement (LVDd: 45 mm; LVDs: 42 mm), and a reduced LV ejection fraction (LVEF: 23%). Idiopathic incessant ventricular tachycardia (VT) leading to tachycardia mediated cardiomyopathy was suggested. Because of incessant wide QRS tachycardia refractory to antiarrhythmic drugs, he was referred for electrophysiological study. Antiarrhythmic medications were

discontinued one week prior to electrophysiological procedure. The ECG was suggestive of VT arising from the right ventricle near the His bundle (Fig. 1).

The patient was brought to the electrophysiological (EP) laboratory in a fasting state after informed consent was obtained.

During deep sedation with endotracheal intubation, the VT stopped and sinus rhythm was restored.

Catheters were placed in the right ventricle via femoral veins. A seven French 4 mm-tip radiofrequency (RF) mapping/ablation catheter (Mariner, Medtronic) was used for cardiac mapping and ablation. One additional 6 F decapolar electrode catheter was used. During normal atrioventricular (AV) conduction, AH and HV intervals were 100 and 38 ms, respectively. Programmed ventricular pacing during isoproterenol infusion easily induced the ventricular tachycardia.

The ablation site was selected using activation mapping during tachycardia. During VT, retrograde ventriculoatrial (VA) conduction was 1:1 with a heart rate of 140 bpm (RR: 420 ms), and the VA interval was 165 ms. The entire right ventricle endocardial surface, including the tricuspid annulus, was carefully mapped. The earliest

* Corresponding author. Cardiology Department, La Rabta Hospital, 1007 La Rabta Jebbari, Tunis, Tunisia.

E-mail address: sanaouali@hotmail.fr (S. Ouali).

Peer review under responsibility of Indian Heart Rhythm Society.

<https://doi.org/10.1016/j.ipej.2017.10.008>

0972-6292/Copyright © 2017, Indian Heart Rhythm Society. Production and hosting by Elsevier B.V. This is an open access article under the CC BY-NC-ND license (<http://creativecommons.org/licenses/by-nc-nd/4.0/>).

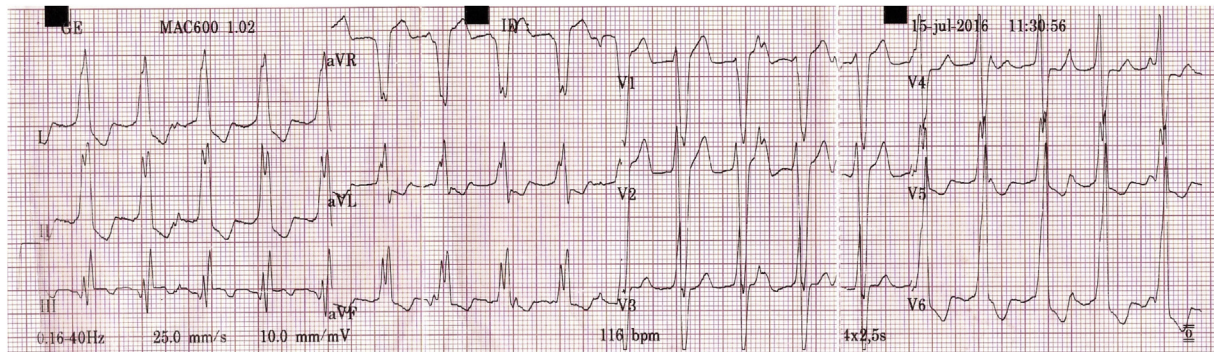


Fig. 1. Twelve-lead ECG showing wide-QRS tachycardia with a left bundle-branch block morphology.

endocardial site for ablation was localized adjacent to the His bundle (Fig. 2, Panel A). Local activation times preceded in 38 ms at QRS beginning (Fig. 2, Panel B). No cryo energy was available to prevent injury to the bundle. Radiofrequency ablation was indicated because the tachycardia mediated cardiomyopathy despite the risk of atrioventricular block (AVB). The VT stopped after 7–13 s after the beginning of each RF application but remained inducible during isoproterenol infusion. Unfortunately, a complete AV conduction block (AVB) was induced and the procedure was stopped. A single chamber pacemaker was implanted. Two weeks later the same VT recurred and the child underwent an additional session of RF catheter ablation. A retrograd aortic approach via the left femoral artery was performed to map the left side of the

interventricular septum. Intravenous (IV) heparin bolus of 50 U/kg and infusion of 1000 U/h were administered during the procedure. A local activation time preceding the surface QRS complex by 58 ms, with a QS morphology with steep negative deflection was observed in the unipolar recording from the catheter tip in the left parahisian area (Fig. 2, Panel C and D). One RF application stopped the VT and remained non-inducible immediately and 30 min after the last energy application, despite isoproterenol infusion (Fig. 3). The child remained free of VT during 7 months of follow-up. The echocardiographic evaluation showed partial reversal of left ventricular function in the first 3 months with LVEF of 38% despite right ventricle pacing.

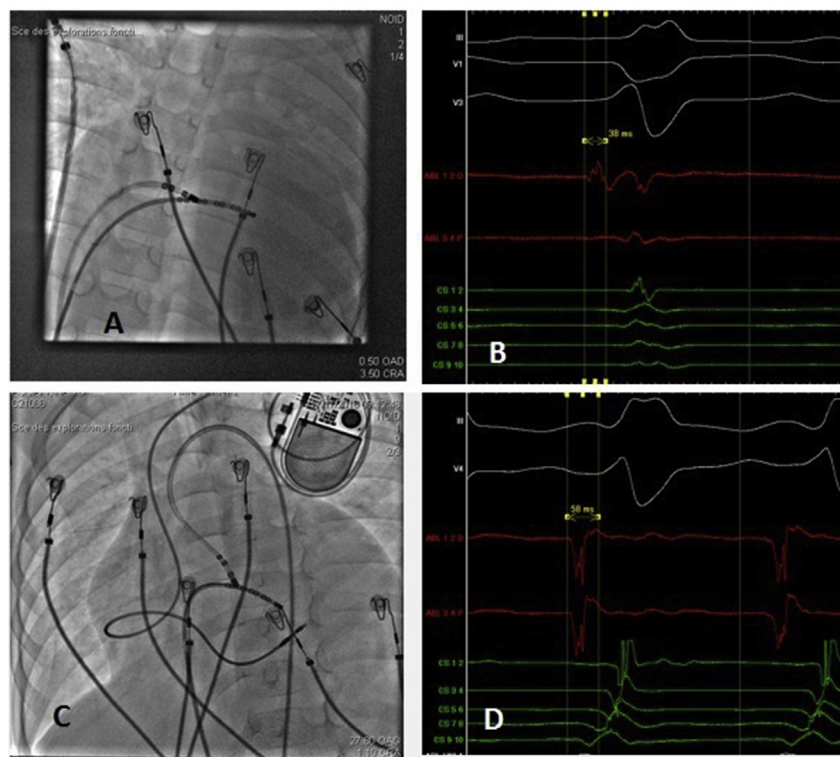


Fig. 2. Panel A: Anteroposterior fluoroscopic view showing the electrophysiological catheter positions during the first procedure. The earliest endocardial site for ablation was localized adjacent to the His bundle. Panel B: Corresponding intracardiac recordings during ventricular tachycardia from the right side of the parahisian area. Local activation times preceded in 38 ms at QRS beginning. Panel C: Rx image in left anterior oblique position, showing the catheter location where the earliest endocardial potential was recorded and where radiofrequency energy was successfully applied in the left parahisian region. Panel D: Corresponding intracardiac recordings during ventricular tachycardia from the left side of the interventricular septum. A local activation time preceding the surface QRS complex by 58 ms. Top to bottom: III, V1 and V3 (Panel B) and III and V4 (Panel D) are reference ECG leads. ABLp and ABLd proximal and distal electrogram obtained at the target spot. CS1–2 to CS9–10: distal to proximal electrograms recorded from a decapolar mapping catheter positioned in the right ventricle.

Download English Version:

<https://daneshyari.com/en/article/8661628>

Download Persian Version:

<https://daneshyari.com/article/8661628>

[Daneshyari.com](https://daneshyari.com)