Journal of Cardiology xxx (2018) xxx–xxx

Contents lists available at ScienceDirect

Journal of Cardiology

journal homepage: www.elsevier.com/locate/jjcc

Review

Histopathological validation of optical coherence tomography findings of the coronary arteries

Kenichi Fujii (MD)[a,b,*], Rika Kawakami (MD)[b], Seiichi Hirota (MD)[b]

[a] Department of Cardiology, Higashi Takarazuka Satoh Hospital, Takarazuka, Japan
[b] Department of Surgical Pathology, Hyogo College of Medicine, Nishinomiya, Japan

ARTICLE INFO

Article history:
Received 28 February 2018
Accepted 1 March 2018
Available online xxx

Keywords:
Optical coherence tomography
Atherosclerosis
Stent

ABSTRACT

Optical coherence tomography (OCT), a catheter-based imaging modality for the visualization of coronary arteries, is widely used during percutaneous coronary intervention to improve the understanding of the anatomy of coronary artery stenosis and to elucidate the mechanisms of atherosclerosis. In this review, we provide a short description of the histopathological validations of OCT for visualizing atherosclerotic plaques and vascular healing response after drug-eluting stent (DES) implantation. Because OCT measures the intensity of light returning from within a tissue, tissue having a higher heterogeneity of optical index of refraction, such as microcalcification deposition and foam cell accumulation on the luminal surface, may exhibit stronger optical scattering that appears as a thin-cap fibroatheroma image. Furthermore, even if OCT shows exposed uncovered stent struts, some of the struts could be re-endothelialized. In our ex vivo histopathological experience, re-endothelialization at the surface of stent struts was confirmed by histopathological analysis, although OCT images showed exposed uncovered struts after DES implantation. Therefore, careful interpretation is required to assess tissue morphology and stent strut coverage by OCT.

Contents

Introduction

Optical coherence tomography (OCT), a light interference-based optical technique, allows three-dimensional cross-sectional imaging within biological samples, with a spatial resolution of approximately 10 μm. OCT lies between the deep and superficial imaging techniques, conveying high spatial resolution at imaging depths of millimeters into tissue. Since its conception, OCT has been developed as a technique enabling high-resolution real-time in situ imaging of tissue microstructure, without the need for tissue excision and processing. Recent technological advancements have facilitated the application of OCT technology in a

* Corresponding author at: Higashi Takarazuka Satoh Hospital, Department of Cardiology, Takarazuka-city, Hyogo 6650873, Japan.

https://doi.org/10.1016/j.jjcc.2018.03.003
0914-5087/© 2018 Published by Elsevier Ltd on behalf of Japanese College of Cardiology.

variety of medical fields, such as developmental biology, ophthalmology, interventional cardiology, dentistry, gastrointestinal endoscopy, dermatology, laryngology, and gynecology. In interventional cardiology, intravascular OCT, which is a catheter-based imaging modality for the visualization of coronary arteries, is widely used during percutaneous coronary intervention to improve the understanding of the anatomy of complex lesions and to elucidate the mechanisms of atherosclerosis. With an axial resolution of approximately 10 μm and a lateral resolution of 30–40 μm [1], intracoronary OCT is capable of visualizing coronary microstructure and deployed stents at a resolution that is 10 times better than that of intravascular ultrasound (IVUS), the preceding technology for the high-resolution imaging of the coronary wall. Moreover, OCT is capable of differentiating lipid tissue from fibrous tissue. Because OCT uses near-infrared light and cross-sectional images are generated by measuring the echo time delay and intensity of light that is reflected or backscattered from the arterial wall, OCT has the potential for characterizing tissue morphology by measuring backscattered infrared light. Several in vivo OCT studies have elucidated the mechanism of acute coronary syndrome (ACS) and the process of atherosclerosis progression in native coronary arteries [2]. These studies have also clarified the mechanism of vascular response after drug-eluting stent (DES) implantation [3]. Furthermore, the morphological characteristics of very late stent thrombosis (VLST) after DES implantation, which is frequently associated with myocardial infarction and may be fatal, have been clarified by a clinical in vivo study using OCT [3]. The application of OCT to actual in vivo pathology, however, has been hampered by the inability to improve the lateral resolution of these probes so that they are capable of distinguishing finer tissue structures. In this review, we provide a short description of the histopathological validations of OCT for visualizing atherosclerotic plaques and vascular healing response after DES implantation.

Evaluation of the native coronary artery

The coronary artery comprises three layers: intima, consisting of endothelium and collagen fiber; media, consisting of smooth muscle and elastic fiber; adventitia, consisting of collagen fiber. Because OCT measures the intensity of light returning from within a tissue, tissues with a higher heterogeneity of optical index of refraction exhibit stronger optical scattering and therefore, a stronger OCT signal. If the characteristic size of the index of refraction is larger than the wavelength of near-infrared light, the OCT signal will have a larger variance. The intima in the normal arterial wall is normally represented by the bright signal of collagen fiber. The media shows a dark and homogeneous signal because of less collagen fiber and abundant smooth muscle cells and extracellular matrix. The adventitia is also represented by the bright signal of collagen fiber. In atherosclerotic plaques, fibrotic plaques, which consist of bundles of collagen fibers, smooth muscle cells, and proteoglycan, appear as a high-signal-intensity tissue because there is much reflected light returning from collagen fibers (Fig. 1). In contrast, lipidic tissues appear as low-signal-intensity regions with diffuse borders because of multiple scattering in lipids at light wavelengths around 1000 nm [4]. Furthermore, OCT depicts dense calcium as low-signal-intensity areas with sharply delineated borders. Because the dimension of the individual particles of calcium hydroxyapatite is smaller than the wavelength of near-infrared light, there is little reflected light returning from these tissues. As a result, OCT images of dense calcium show weaker optical scattering and, therefore, a lower OCT signal intensity. In 2002, in a comparison using autopsy specimens, Yabushita et al. [5] reported that OCT images of each type of plaque had the following features: (1) fibrous plaque, a homogenous high-signal region with low attenuation; (2) lipid-rich plaque, a low-signal region with diffuse borders; and (3) calcified plaque, a well-delineated low-signal region with sharp borders. They showed that the sensitivity and specificity of OCT were 71–79% and 97–98%, respectively, for fibrous plaque, 90–94% and 90–92%, respectively, for lipid-rich plaques, and 95–96% and 97%, respectively, for calcified plaques [5]. These findings were later confirmed by Kume et al. [6] who reported a >90% sensitivity and specificity for detecting lipid-rich plaque by OCT in 166 sections from 108 coronary arterial segments of 40 consecutive human cadavers. Kume et al. [7] also analyzed the difference between red and white coronary arterial thrombi using OCT ex vivo in postmortem patients. They found no significant differences in

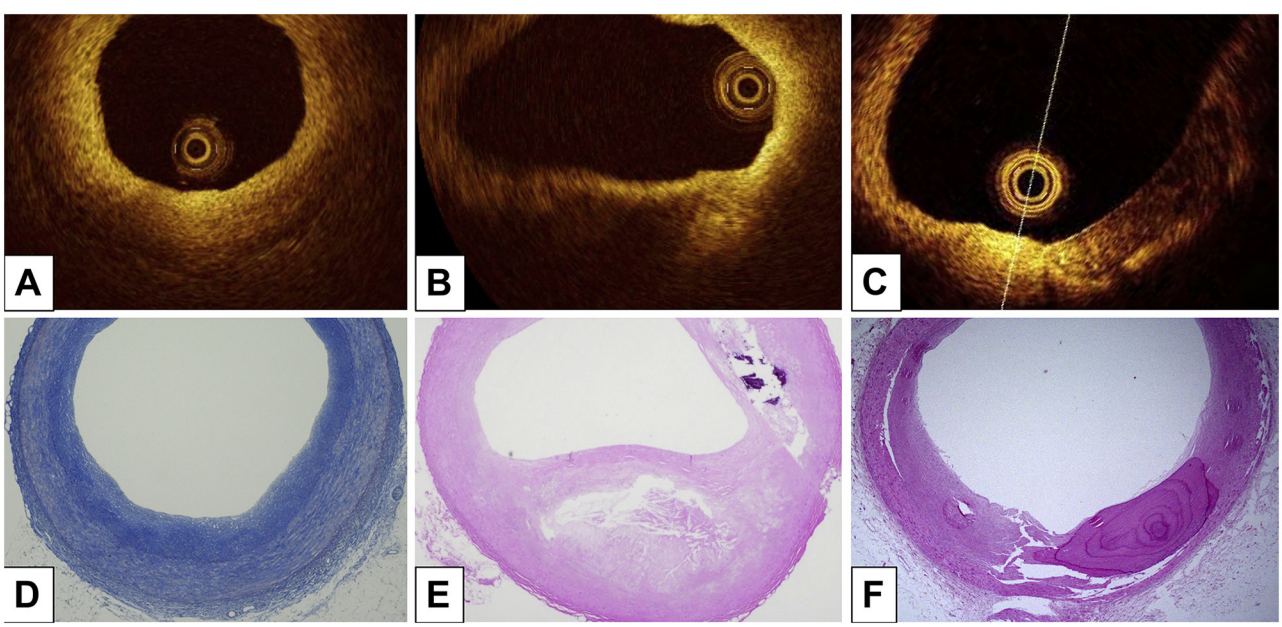

Fig. 1. Correlation between optical coherence tomography (OCT) images and histologic images of coronary atherosclerotic plaques obtained at autopsy. (A, B, C) OCT images of plaque consisting mainly of fibrotic tissue, lipidic tissue, and calcium. (D) OCT images of the plaque of fibrous tissue. (E, F) Corresponding pathological images of lipidic tissue and calcium (hematoxylin and eosin stain).

Please cite this article in press as: , et al. Histopathological validation of optical coherence tomography findings of the coronary arteries. J Cardiol (2018), https://doi.org/10.1016/j.jjcc.2018.03.003