



ELSEVIER

Contents lists available at ScienceDirect

Journal of Cardiology Cases

journal homepage: [www.elsevier.com/locate/jccase](http://www.elsevier.com/locate/jccase)



## Case Report

# Multiple coronary artery spasms triggering life-threatening ventricular arrhythmia associated with the radiofrequency ablation of ganglionated plexuses of the left atrium

Shogo Sakamoto (MD, PhD)<sup>a,\*</sup>, Toru Kataoka (MD, PhD)<sup>a</sup>, Miwa Kanai (MD)<sup>a</sup>, Kenji Tamura (MD)<sup>a</sup>, Tomokazu Iguchi (MD, PhD)<sup>a</sup>, Hiroaki Tatsumi (MD, PhD)<sup>b</sup>, Atsushi Doi (MD, PhD)<sup>b</sup>, Minoru Yoshiyama (MD, PhD, JFCC)<sup>b</sup>

<sup>a</sup> Department of Cardiovascular Medicine, Bell Land General Hospital, Osaka, Japan

<sup>b</sup> Department of Cardiovascular Medicine, Osaka City University Graduate School of Medicine, Osaka, Japan

### ARTICLE INFO

#### Article history:

Received 29 June 2017

Received in revised form 5 December 2017

Accepted 18 December 2017

#### Keywords:

Multiple coronary spasms

Ganglionated plexus

Atrial fibrillation

Ventricular fibrillation

Autonomic imbalance

### ABSTRACT

We report a case of multiple coronary spasms leading to life-threatening ventricular arrhythmia, during left atrium (LA) ablation. Coronary artery spasm is a rare complication during radiofrequency catheter ablation of atrial fibrillation (AF). Previous reports mention that autonomic imbalance leads to coronary artery spasm and ST-segment elevation in the inferior leads, during trans-septal LA catheterization and AF ablation procedures. However, there are few reports detailing the association between ablation sites and changes in the electrocardiogram. We encountered transient ST-segment elevation and refractory ventricular arrhythmia, associated with coronary artery spasm, during radiofrequency ablation of ganglionated plexuses (superior surface of left and right atrium).

**<Learning objective:** Our case report shows that ablation of ganglionated plexus sites during pulmonary vein isolation, can induce ST-segment elevation in various leads, and cause multiple coronary spasms associated with refractory ventricular fibrillation. There is an inherent risk of multiple coronary spasms during catheter ablation of atrial fibrillation (AF), in patients with vasospastic angina. We recommend continuous intravenous infusion of nitroglycerin during ablation for AF to prevent coronary spasms in patients with vasospastic angina.>

© 2018 Japanese College of Cardiology. Published by Elsevier Ltd. All rights reserved.

## Introduction

Coronary artery spasm is a rare complication associated with radiofrequency catheter ablation of the left atrium. Previous reports mentioned that various mechanisms including direct thermal injury, progressive inflammation, or stimulation of ganglionated plexuses (GP) might lead to coronary artery spasm. However, there are few reports about the relationship between ablation of GP sites and changes on the electrocardiogram (ECG). We present here, ECG changes associated with GP stimulation, and the risk of life-threatening coronary spasm.

## Case report

A 57-year-old man was admitted to our hospital for acute heart failure with atrial fibrillation (AF). However, he had no symptoms such as palpitations or chest pain. We suspected that the AF was associated with heart failure. Thus, he was admitted for pulmonary vein isolation (PVI) procedure for AF. The patient was placed under general anesthesia using propofol and dexmedetomidine. Two 8 Fr. Swartz sheaths (St Jude Medical Inc., Saint Paul, MN, USA) and AgilisNxT (St Jude Medical Inc.) were inserted into the left atrium, through a punctured trans-septal hole. The patient was administered 8000 units of heparin, and heparin was continued until a maintenance dose was reached, with minimal activated clotting time of 300 s. We flushed the sheaths carefully using saline with heparin to prevent air or thrombus. We used an irrigated tip radiofrequency (RF) ablation catheter (Navistar ThermoCoolSmartTouch; Biosense Webster, Irvine, CA, USA). Ablation was performed at a maximum temperature of 43 °C and power limit of

\* Corresponding author at: Department of Cardiovascular Medicine, Bell Land General Hospital, 500-3 Higashiyama, Naka-ku, Sakai, Osaka, 599-8247, Japan.  
E-mail address: [s821shogo@live.jp](mailto:s821shogo@live.jp) (S. Sakamoto).

<https://doi.org/10.1016/j.jccase.2017.12.004>

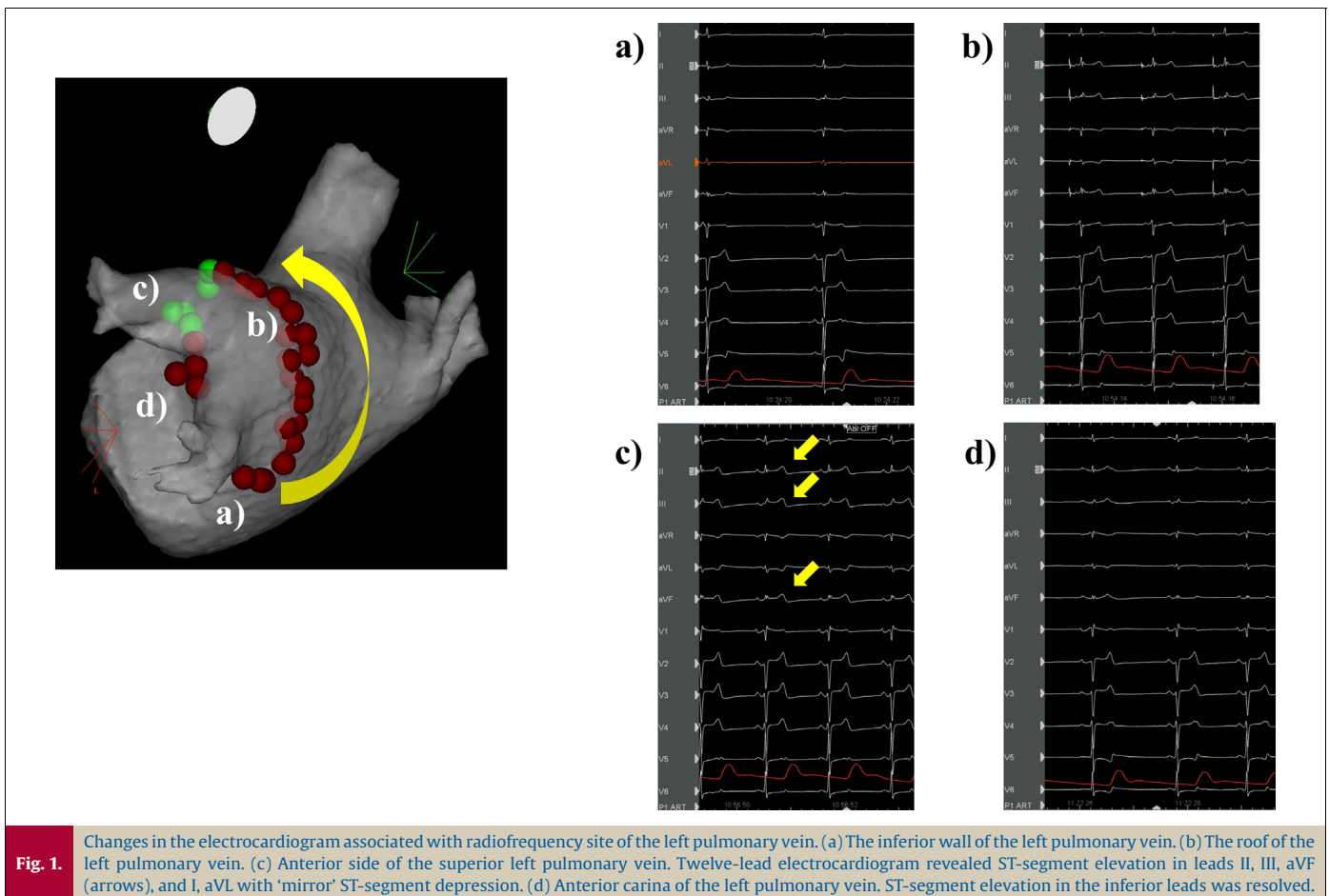
1878-5409/© 2018 Japanese College of Cardiology. Published by Elsevier Ltd. All rights reserved.

30 W. We used the CARTO3 system automated lesion-tagging module (Biosense Webster), based on catheter stability information and force-time integral (FTI). Our target FTI was 400 gs. RF was performed using the point-by-point technique. Ablation was initiated at the inferior wall of the left inferior pulmonary vein (IPV), and posterior ablation was performed sequentially upward, to the superior wall of the left superior pulmonary vein (SPV). Subsequently, anterior ablation was performed downward toward the left IPV. The patient's blood pressure was 89/55 mmHg and heart rate was 55 bpm while initiating ablation. However, his blood pressure decreased to 66/42 mmHg, and the heart rate suddenly dropped to 36 bpm, at the time of ablation of the atrial appendage-atrial junction (between the 19th and 24th applications). RF energy was 30 W and RF application was followed by FTI (400 gs). Cardiac tamponade was excluded on echocardiography. Within a few minutes, the patient's blood pressure returned to baseline. Following this, RF ablation was continued and the procedure for the left PV was completed successfully. Retrospectively, we observed ST-segment elevation in leads II, III, aVF, and I, aVL with 'mirror' ST-segment depression, on a 12-lead ECG. The ST-segment elevation and hemodynamic changes resolved spontaneously after several minutes (Fig. 1). We continued right PVI from the inferior wall of the right IPV to the roof on the posterior side. At the time of roof ablation, the 12-lead ECG revealed occurrence of AF, and the patient's blood pressure decreased gradually. During ablation on the anterior side of right SPV (between the 53rd and 59th applications), the 12-lead ECG revealed ST-segment elevation in aVR and recurrence of hypotension. The patient's blood pressure dropped to 60/43 mmHg and heart rate decreased to 31 bpm. However, these changes could not be detected earlier, because only a limited number of ECG leads were displayed on the monitor.

Hence, we initiated atrial pacing and continued the ablation. RF energy was 30 W and RF application did not change. Suddenly, the 12-lead ECG showed monomorphic ventricular tachycardia, which progressed to ventricular fibrillation (VF) (Fig. 2). Immediately, cardioversion was performed thrice, but it failed to control the VF. The patient then developed pulseless electrical activity. We initiated percutaneous cardiopulmonary support (PCPS) and VF was terminated using an external defibrillator. Cardiac tamponade was excluded by ultrasound sonography. The 12-lead ECG revealed ST-segment elevation in the inferior leads and in V2, V3, and V4. Therefore, we performed urgent coronary artery angiography, which demonstrated severe spasm, and reduced flow in the right and left coronary arteries (Fig. 3). Intracoronary bolus injection of nitroglycerin induced vasodilation of the coronary arteries and the ST-segment elevation in the leads improved. Subsequently, his blood pressure and general condition stabilized. We performed ablation at the residual site of the right PV, and the left atrium RF ablation was completed successfully. The patient recovered consciousness 3 days later, his hemodynamic stability was maintained, and he was taken off PCPS support. He recovered without any neurological sequelae, and was discharged. Sinus rhythm was preserved. One year later, a drug-induced coronary artery spasm test was performed. We injected acetylcholine into the right coronary artery up to a dose of 50  $\mu$ g. The drug-induced coronary artery spasm test revealed total occlusion of the right coronary artery.

## Discussion

In this case report, we described in detail, the association between RF of GP sites of the left atrium with ST-segment elevation



Download English Version:

<https://daneshyari.com/en/article/8668078>

Download Persian Version:

<https://daneshyari.com/article/8668078>

[Daneshyari.com](https://daneshyari.com)