



ELSEVIER

Contents lists available at ScienceDirect

Journal of Cardiology Cases

journal homepage: [www.elsevier.com/locate/jccase](http://www.elsevier.com/locate/jccase)

## Case Report

## Time course of restenosis with “black hole” on intravascular ultrasound after implantation of platinum–chromium everolimus-eluting stent: Assessment using optical frequency-domain imaging



Shinnosuke Kikuchi (MD)<sup>a,b</sup>, Yukiko Morita (MD)<sup>a,\*</sup>, Masahiko Kanna (MD)<sup>a</sup>, Toru Dejima (MD)<sup>a</sup>, Mina Nakayama (MD)<sup>a</sup>, Yuichi Okajima (MD)<sup>a</sup>, Kiyoshi Hibi (MD, FJCC)<sup>b</sup>, Kazuo Kimura (MD, FJCC)<sup>b</sup>, Kouichi Tamura (MD)<sup>c</sup>

<sup>a</sup> Division of Cardiology, National Hospital Organization Sagamihara National Hospital, Sagamihara, Japan

<sup>b</sup> Division of Cardiology, Yokohama City University Medical Center, Yokohama, Japan

<sup>c</sup> Department of Medical Science and Cardiorenal Medicine, Yokohama City University Graduate School of Medicine, Yokohama, Japan

## ARTICLE INFO

## Article history:

Received 13 June 2017

Received in revised form 8 October 2017

Accepted 30 October 2017

## Keywords:

Black hole

Restenosis

Second-generation drug-eluting stent

Intravascular ultrasound

Optical frequency-domain imaging

## ABSTRACT

Management of in-stent restenosis (ISR) remains challenging even in the drug-eluting stent era. We report the case of a Japanese female with repeated ISR after primary percutaneous coronary intervention (PCI) for acute coronary syndrome. We observed ISR tissue with “black hole” on intravascular ultrasound, which appeared to be heterogeneous tissue on optical frequency-domain imaging (OFDI). Paclitaxel-coated balloon dilatation of the ISR lesion with “black hole” was ineffective. The morphological assessment of ISR tissue using OFDI might be important to treat ISR lesions by PCI. OFDI is a novel tool to observe the difference in the in-stent tissue characteristics.

**<Learning objective:** In-stent restenosis (ISR) remains a clinical problem even in the drug-eluting stent (DES) era. The morphological assessment of ISR tissue using optical frequency-domain imaging (i.e. homogeneous, heterogeneous, and layered types) might be important to treat ISR lesions by percutaneous coronary intervention since the reaction to DES and drug-coating balloon seems to be different according to the in-stent tissue characteristics.>

© 2018 Published by Elsevier Ltd on behalf of Japanese College of Cardiology.

## Introduction

In-stent restenosis (ISR) remains a clinical problem, although drug-eluting stents (DES) reduced the rate of restenosis through inhibition of cell proliferation compared with bare-metal stents (BMS) [1]. Progress in intracoronary imaging modalities has enabled the morphological assessment of ISR tissue. Optical frequency-domain imaging (OFDI) findings of ISR tissue structure were classified into several types: homogeneous, heterogeneous, and layered types [2]. The morphological assessment of ISR tissue might be important to treat ISR lesions [3]. We report the case of a

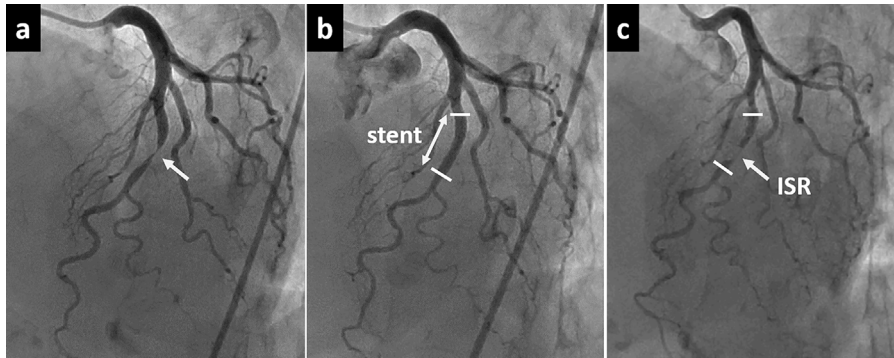
Japanese female with repeated ISR after primary percutaneous coronary intervention (PCI) for acute coronary syndrome, in whom we evaluated the restenotic tissue over time using intravascular ultrasound (IVUS) and OFDI.

## Case report

A 63-year-old woman with a history of dyslipidemia was admitted to our hospital with acute coronary syndrome. Coronary angiography (CAG) showed significant stenosis of the mid left anterior descending artery (LAD) (Fig. 1a). A 3.0 × 16 mm platinum–chromium everolimus-eluting stent was implanted directly (Fig. 1b). Routine follow-up angiography 7 months later showed ISR [OFDI-derived minimal lumen area (MLA): 0.72 mm<sup>2</sup>] (Fig. 1c). The appearance of ISR on IVUS (OptiCross, Boston Scientific, Natick, MA, USA) included homogeneous echo-lucent intraluminal tissue, the so called “black hole” (Fig. 2 upper and middle panels) [4,5]. On

\* Corresponding author at: Division of Cardiology, National Hospital Organization Sagamihara National Hospital, 18-1 Sakuradai, Minami-ku, Sagamihara 252-0392, Japan.

E-mail address: [y-morita@sagamihara-hosp.gr.jp](mailto:y-morita@sagamihara-hosp.gr.jp) (Y. Morita).



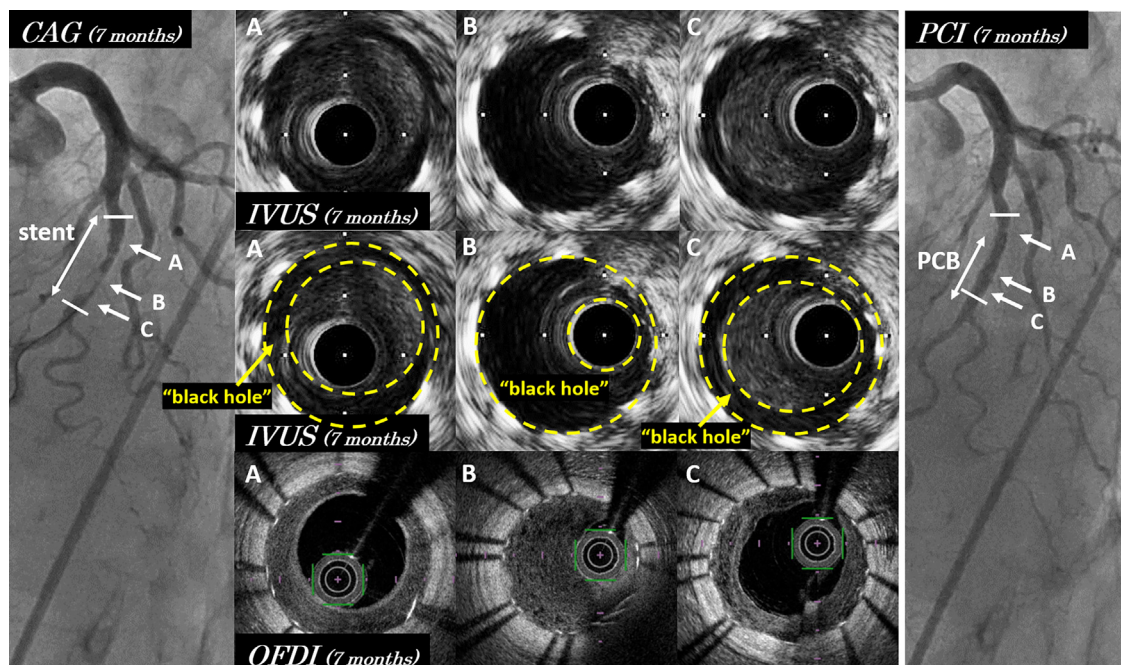
**Fig. 1.** (a) Immediate coronary angiography for acute coronary syndrome showed a significant stenosis at mid left anterior descending artery. (b) A 3.0 × 16 mm platinum–chromium everolimus-eluting stent was implanted directly. (c) Follow-up angiography 7 months later showed in-stent restenosis (ISR).

OFDI (FastView, Terumo, Tokyo, Japan), it appeared to be heterogeneous low-intensity smooth sponge-like tissue (Fig. 2, lower panels). The restenotic “black hole” lesion was dilated from segment “B” through segment “C” with a 3.0 × 15 mm paclitaxel-coated balloon (PCB) after dilatation with a 3.0-mm scoring balloon (Fig. 2, right panel), whereas segment “A” was not dilated since the stenosis was not considered significant (angiographic % diameter stenosis was 50%). Follow-up angiography 11 months later showed ISR with “black hole” on IVUS again (OFDI-derived MLA: 1.21 mm<sup>2</sup>). In segment “A”, which was not dilated with PCB, progression and abundant bright punctate structures with backward attenuation were observed in the smooth heterogeneous sponge-like tissue on OFDI (Fig. 3, middle panels). Bright puncta in the heterogeneous tissue on OFDI developed in the proximal stent segment without PCB dilatation, whereas these were not observed in the distal stent segment with PCB dilatation. These bright puncta were not observed at 7 months follow-up (Fig. 2, lower panels;

Fig. 3, upper panels). The lesion of repeated restenosis with “black hole” was dilated with a 3.0 mm scoring balloon including segment “A”. Follow-up angiography 16 months later also showed ISR (OFDI-derived MLA: 1.59 mm<sup>2</sup>). However, the FFR value was 0.93 for LAD and PCI was not performed. The appearance of ISR on IVUS included “black hole” again, where the same appearance was found on OFDI (Fig. 3, lower panels). Progression of heterogeneous tissue with bright puncta was observed around the proximal stent edge.

### Discussion

“Black hole” on IVUS is defined as homogeneous echo-lucent intraluminal tissue. Histopathological assessment of “black hole” tissue showed hypocellular tissue with proteoglycan- or fibrin-rich extracellular matrix (ECM), lacking connective tissue [1,6]. The hypocellular tissue may look echo-lucent on IVUS. It is thought that



**Fig. 2.** Coronary angiography, intravascular ultrasound (IVUS), and optical frequency-domain imaging (OFDI) 7 months later. IVUS images of in-stent restenosis (upper and middle panels) showed homogeneous echo-lucent intraluminal tissue, the so-called “black hole”. “Black hole” is the tissue surrounded with yellow lines. In-stent restenosis on OFDI (lower panels) showed low-intensity smooth heterogeneous sponge-like tissue. Segment “B” and “C” was dilated with paclitaxel-coated balloon (PCB), whereas segment “A” was not dilated with PCB (right panel). PCI, percutaneous coronary intervention; CAG, coronary angiography.

Download English Version:

<https://daneshyari.com/en/article/8668087>

Download Persian Version:

<https://daneshyari.com/article/8668087>

[Daneshyari.com](https://daneshyari.com)