



# Significant left ventricular outflow tract obstruction secondary to systolic anterior motion in a patient without hypertrophic cardiomyopathy: An echocardiographic study

Hanan Alrammah<sup>a,\*</sup>, Sami Ghazal<sup>b</sup>

<sup>a</sup> Medical Intern, Imam Abdulrahman Bin Faisal University, Dammam

<sup>b</sup> Internal Medicine Department, College of Medicine, Imam Abdulrahman Bin Faisal University, Dammam

<sup>a,b</sup> Saudi Arabia

Dynamic left ventricular outflow tract obstruction (LVOTO) can be hemodynamically significant and can adversely affect the heart and quality of life. It is caused by systolic anterior motion (SAM) of the anterior mitral valve into the LVOT. The mechanism underlying SAM has been an area of special interest. However, SAM occurrence in the absence of septal hypertrophy is exceedingly uncommon. Here we present a case of a young male patient who sought medical care with a complaint of exertional dyspnea, New York Heart Association functional Class 2–3, and was found to have SAM and severe LVOTO at rest without hypertrophic cardiomyopathy. Continuous wave Doppler signal showed a peak velocity of 4.96 m/s along the LVOT, with a pressure gradient at rest of 98.44 mmHg, calculated using the modified Bernoulli equation. The patient is not known to have any medical conditions, nor had a family history of cardiac condition or sudden death. Trans-thoracic echocardiography showed concentric remodeling of the LV without hypertrophy. Trans-esophageal echocardiography was performed for further assessment of the anatomy. The anterior mitral leaflet (AML) and posterior mitral leaflet (PML) lengths were 3.7 cm and 1.3 cm, respectively (normal AML < 3 cm; normal PML < 1.5 cm). In our patient, the LVOTO is significant enough to result in a decreased cardiac output, which explains the symptoms experienced, due to which he developed concentric remodeling. The only finding in this patient explaining SAM is an elongated AML.

© 2018 The Authors. Production and hosting by Elsevier B.V. on behalf of King Saud University. This is an open access article under the CC BY-NC-ND license (<http://creativecommons.org/licenses/by-nc-nd/4.0/>).

**Keywords:** Echocardiography, Left ventricular outflow obstruction, Systolic anterior motion

## 1. Introduction

Dynamic left ventricular outflow tract obstruction (LVOTO) can be hemodynamically significant and can adversely affect the heart and

quality of life. It is caused by systolic anterior motion (SAM) of the anterior mitral valve into the LVOT. The mechanism underlying SAM has been an area of special interest. Hypertrophic cardiomyopathy (HCM) is the most prevalent cause of SAM of the mitral valve and LVOTO [1]. While

*Disclosures:* Authors have nothing to disclose with regard to commercial support

Received 2 June 2018; revised 24 June 2018; accepted 8 July 2018.

\* Corresponding author: Hanan Alrammah, Omar bin Abdulaziz Street, Eastern Province, Dhahran, Saudi Arabia.  
E-mail address: [hanan.alrammah@gmail.com](mailto:hanan.alrammah@gmail.com) (H. Alrammah).



P.O. Box 2925 Riyadh – 11461KSA  
Tel: +966 1 2520088 ext 40151  
Fax: +966 1 2520718  
Email: [sha@sha.org.sa](mailto:sha@sha.org.sa)  
URL: [www.sha.org.sa](http://www.sha.org.sa)

1016-7315 © 2018 The Authors. Production and hosting by Elsevier B.V. on behalf of King Saud University. This is an open access article under the CC BY-NC-ND license (<http://creativecommons.org/licenses/by-nc-nd/4.0/>).



Peer review under responsibility of King Saud University.  
URL: [www.ksu.edu.sa](http://www.ksu.edu.sa)  
<https://doi.org/10.1016/j.jsha.2018.07.001>



Production and hosting by Elsevier

several theories have been proposed to explain the occurrence of SAM and LVOTO, the ‘drag effect’ theory is widely accepted [2]. Occurrence of SAM in the absence of septal hypertrophy is exceedingly uncommon. In this report, we present a case of a young male patient who sought medical care with a complaint of exertional dyspnea and was found to have SAM and severe LVOTO at rest without HCM.

## 2. Case report

A 38-year-old male patient was referred to the cardiology department at our institute with a complaint of exertional shortness of breath, New York Heart Association functional Class 2–3, with no orthopnea or paroxysmal nocturnal dyspnea. The patient is not known to have any medical conditions; besides, there was no family history of cardiac condition nor sudden death. Various investigations were performed, including electrocardiogram and trans-thoracic echocardiography (TTE), which showed concentric remodeling of the left ventricle without hypertrophy and the following measurements: interventricular septal thickness, 1.2 cm; posterior wall thickness, 1.2 cm; left ventricular internal diameter end diastole, 4.5 cm; relative wall thickness, 52%; left ventricle mass, 197.99 g; left ventricle mass index, 95.65 g/m<sup>2</sup> (Fig. 1A). SAM of the anterior mitral leaflet (AML) was noted (Fig. 1B) with prominent flow acceleration using color Doppler. Severe LVOTO at rest was also noted, with a continuous wave Doppler signal showing a peak velocity of 4.96 m/s along the LVOT and pressure gradient at rest of 98.44 mmHg, which was calculated using the modified Bernoulli equation (Fig. 1C). The patient had a normal left ventricular ejection fraction of

70% with no regional wall motion abnormalities. Mild posteriorly directed jets of mitral regurgitation were also identified. Mid-left ventricular parasternal short-axis view confirmed the normal position of the papillary muscles (PMs) and a PM diameter of 1.1 cm. Trans-esophageal echocardiography (TEE) was performed for further assessment of the anatomy. The AML and posterior mitral leaflet (PML) lengths were 3.7 cm and 1.3 cm, respectively (normal AML < 3 cm; normal PML < 1.5 cm). The AML-to-PML ratio was 2.8 (Fig. 2A) and the LVOT diameter was 2.2 cm. The distance from the mitral valve coaptation point to the septum was 1.5 cm, protrusion height (calculated from the mitral annular plane to the most protruding mitral leaflet tip) was 2 cm (Fig. 2B), residual length (calculated as the uncoapted portion that protrudes distally beyond the coaptation point) was 0.6 cm, and mitral aortic angle was 110°. The patient was started on a  $\beta$ -blocker, which improved his symptoms.

## 3. Discussion

SAM of the mitral valve can be classified into valvular and chordal. Chordal SAM is hemodynamically insignificant [1]. Hypertrophic obstructive cardiomyopathy (HOCM) is the commonest cause of SAM [1]. Several mechanisms have been suggested to explain the occurrence of SAM. Classically, in HOCM, it is assumed that as the velocity of the blood accelerates through the LVOT, pressure decreases, a phenomenon termed the ‘Venturi effect’. The AML will then be sucked into the lower-pressure LVOT, which causes the obstruction, but this presents only a small part of the story. The septal hypertrophy seen in HOCM will affect the ejection flow stream of the left

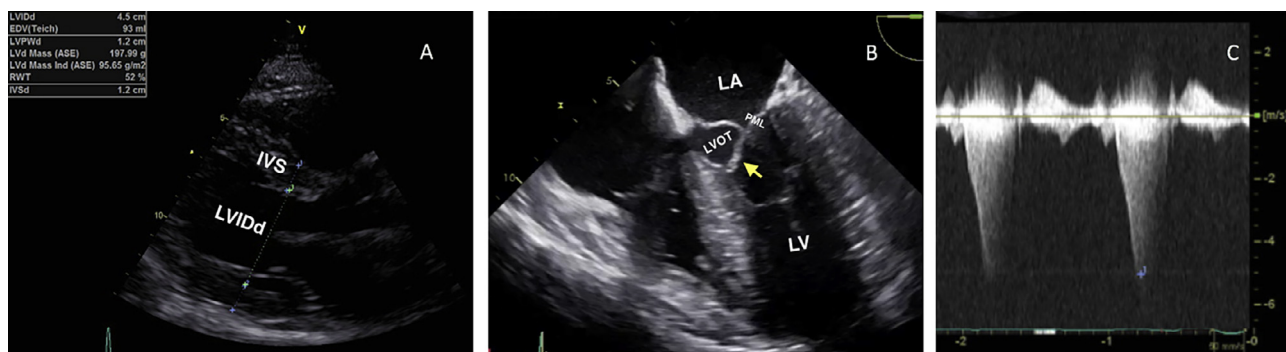


Figure 1. Echocardiography showing SAM. (A) Trans-thoracic echocardiographic imaging in the parasternal long-axis view showing concentric remodeling of the left ventricle (LV). (B) Transesophageal echocardiography. Mid-esophageal four-chamber view showing a systolic anterior motion of the anterior mitral leaflet (yellow arrow) into the left ventricular outflow tract (LVOT) causing severe LVOT obstruction at rest with gradient of 98 mmHg by continuous wave Doppler (C). IVS = interventricular septum; LA = left atrium; LVIDd = left ventricular internal diameter end diastole; PML = posterior mitral leaflet.

Download English Version:

<https://daneshyari.com/en/article/8669751>

Download Persian Version:

<https://daneshyari.com/article/8669751>

[Daneshyari.com](https://daneshyari.com)