

Accepted Manuscript

Leukemoid Reaction: Case report

Trevor Ellison, MD, PhD, Kaushik Mandal, MBBS, MD

PII: S0022-5223(17)31900-1

DOI: [10.1016/j.jtcvs.2017.08.125](https://doi.org/10.1016/j.jtcvs.2017.08.125)

Reference: YMTC 11953

To appear in: *The Journal of Thoracic and Cardiovascular Surgery*

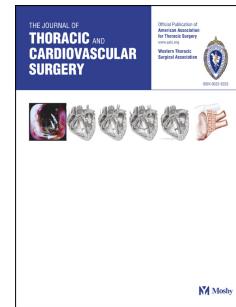
Received Date: 4 April 2017

Revised Date: 2 August 2017

Accepted Date: 29 August 2017

Please cite this article as: Ellison T, Mandal K, Leukemoid Reaction: Case report, *The Journal of Thoracic and Cardiovascular Surgery* (2018), doi: 10.1016/j.jtcvs.2017.08.125.

This is a PDF file of an unedited manuscript that has been accepted for publication. As a service to our customers we are providing this early version of the manuscript. The manuscript will undergo copyediting, typesetting, and review of the resulting proof before it is published in its final form. Please note that during the production process errors may be discovered which could affect the content, and all legal disclaimers that apply to the journal pertain.



1 **Leukemoid Reaction: Case report**

2 *Trevor Ellison, MD, PhD, Kaushik Mandal, MBBS, MD*

3 *The Johns Hopkins Hospital, Department of Surgery, Division of Cardiac Surgery*

4

5 *Disclosures: Nothing to disclose with regard to commercial support*

6

7 *Contact information: Kaushik Mandal, MBBS, MD, Department of Surgery, Division of*
8 *Cardiac Surgery, The Johns Hopkins Hospital, 600 N. Wolfe Street, Sheikh Zayed Tower*
9 *Suite 7107, Baltimore, Maryland 21287 (Email: kmandal2@jhmi.edu).*

10

11 Word count: 748

12

13

14 Central message: Leukemoid reaction is rare and in some instances may be related to a
15 patient's systemic inflammatory response to cardiopulmonary bypass rather than
16 infection or other more common causes

17

18

Download English Version:

<https://daneshyari.com/en/article/8670727>

Download Persian Version:

<https://daneshyari.com/article/8670727>

[Daneshyari.com](https://daneshyari.com)