



REVIEW ARTICLE

## Cardiovascular risk in Turner syndrome

Beatriz Donato<sup>a,\*</sup>, Maria João Ferreira<sup>a,b</sup>



<sup>a</sup> Faculdade de Medicina, Universidade de Coimbra, Coimbra, Portugal

<sup>b</sup> Cardiology Department, Centro Hospitalar Universitário de Coimbra, Coimbra, Portugal

Received 10 February 2017; accepted 16 August 2017

### KEYWORDS

Turner syndrome;  
Cardiovascular  
diseases;  
Risk factors;  
Female

**Abstract** Turner syndrome is a relatively common genetic disorder of female development, characterized by partial or complete absence of an X chromosome, with a variable clinical presentation. Congenital or acquired cardiovascular disease is highly prevalent and a major cause of early death in this syndrome. The most feared complication is aortic dissection, which can occur at a very young age and requires careful assessment of its risk factors. A systematic literature search identified sixty relevant publications. These were reviewed with regard to the increased risk of cardiovascular disease in women with Turner syndrome, especially in pregnancy. The most common congenital cardiovascular defects are presented and illustrated with appropriate iconography. The current recommendations regarding the screening and monitoring of cardiovascular disease in these patients are discussed.

© 2018 Sociedade Portuguesa de Cardiologia. Published by Elsevier España, S.L.U. All rights reserved.

### PALAVRAS-CHAVE

Síndrome de Turner;  
Doenças  
cardiovasculares;  
Fatores de risco;  
Mulher

### Risco cardiovascular na síndrome de Turner

**Resumo** A síndrome de Turner é uma condição genética relativamente comum, caracterizada pela perda total ou parcial de um cromossoma X, com uma apresentação clínica variável e que afeta o desenvolvimento das mulheres. Nessa síndrome há uma prevalência elevada de doença cardiovascular, congénita e adquirida, que condiciona um risco aumentado de morte prematura. A complicação mais temida é a disseção da aorta, que tende a ocorrer em idades mais precoces, implica uma avaliação cuidada dos seus fatores de risco. A pesquisa sistemática da literatura permitiu encontrar 60 artigos relevantes sobre o tema. Foi feita uma revisão sobre o risco aumentado de doença cardiovascular nas doentes com síndrome de Turner, em particular na gravidez. Foram apresentados e ilustrados com iconografia própria os defeitos cardiovasculares congénitos mais prevalentes. Foram discutidas as recomendações atuais relativas ao rastreio e à vigilância da doença cardiovascular nessas doentes.

© 2018 Sociedade Portuguesa de Cardiologia. Publicado por Elsevier España, S.L.U. Todos os direitos reservados.

\* Corresponding author.

E-mail address: [beatrizcamposdonato@gmail.com](mailto:beatrizcamposdonato@gmail.com) (B. Donato).

## Introduction

Turner syndrome (TS) is a genetic disorder with a characteristic phenotype that occurs as a result of a structurally abnormal or absent X chromosome. TS is the only monosomy compatible with life and affects around 1 in 2000 newborn females.<sup>1,2</sup>

There are variable Turner karyotypes, such as monosomy X (45,X; the most prevalent karyotype), mosaic karyotype, isochromosome X, ring X chromosome or deletions. In all these cases, significant portions of the X chromosome are deleted.<sup>3</sup>

The diagnosis of TS requires having key clinical features, including short stature and gonadal failure (the cardinal features) and congenital cardiovascular (CV) defects as well as an abnormal karyotype.<sup>2</sup>

The most serious consequences of X-chromosome haploinsufficiency involve the CV system. Indeed, CV defects, present in up to 50% of the TS population, are the major cause of premature death and contribute to a standardized mortality ratio three times higher than in the general female population. Therefore, imaging studies (both echocardiography and cardiovascular magnetic resonance [CMR]) are crucial for the timely detection of often subclinical CV disease and should preferably be ordered before the onset of symptomatic and irreversible organ damage.<sup>2,4,5</sup>

A thorough cardiac examination is recommended for all women with TS every 5 to 10 years, at the time of transition from pediatric to adult care, before attempting pregnancy or if hypertension (HTN) develops.<sup>2,6</sup>

The aim of this paper is to review both congenital and acquired cardiovascular diseases and the role of clinical imaging in TS CV risk stratification with recommendations for CV screening. Moreover, particular attention will be given to the special risk of CV complications in pregnancy with this syndrome.

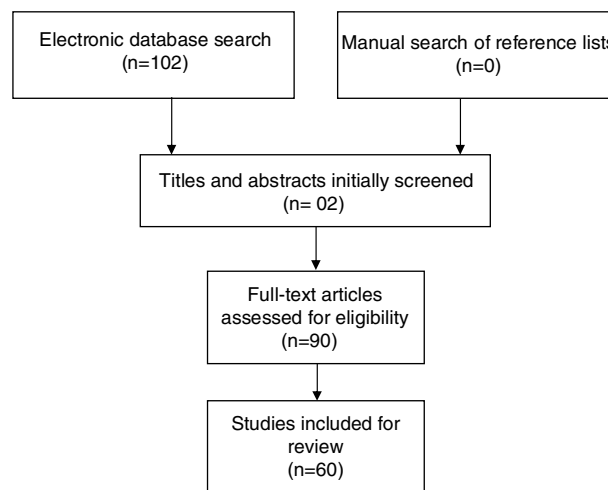
## Methods

This review was performed according to the Preferred Reporting Items for Systematic Reviews and Meta-Analyses (PRISMA) guidelines, thus providing a comprehensive framework that objectively assesses quality indicators and risk of bias in the studies included.

All original studies investigating Turner syndrome and cardiovascular risk were eligible for this systematic review. Further selection criteria were: (i) publication date between January 2000 and September 2016, (ii) written in English, (iii) published in a scholarly peer-reviewed journal.

Studies were found by searching the PubMed, EMBASE and Cochrane Library electronic databases, using the following search strategy: "Turner syndrome AND Cardiovascular disease AND Risk factors AND Female".

Studies were identified by searching relevant papers via PubMed/MEDLINE (<http://www.ncbi.nlm.nih.gov/pubmed>), the Cochrane Library and EMBASE using the following search strategy: "Turner syndrome AND Cardiovascular disease AND Risk factors. Finally, reference lists of the studies retrieved were manually searched in order to detect any additional relevant studies. Keywords and combinations of keywords were used to search the electronic databases (Figure 1).



**Figure 1** Flow diagram of search strategy and study selection.

After performing the initial literature searches, each study title and abstract was screened for eligibility by the first author. The full texts of all potentially relevant studies were subsequently retrieved and examined further for eligibility. The PRISMA flow diagram (Figure 1) provides more detailed information regarding the process for selecting studies. Sixty articles were included in this review and the information from the studies included was then analyzed and recorded. Table 1 shows a summary of the literature consulted.

## Congenital cardiovascular disorders

Variations in the CV anatomy of patients with TS, the frequencies of which are summarized in Table 2, are major factors in their reduced life expectancy.<sup>7</sup>

Major defects in cardiac and aortic development during fetal life are associated with miscarriage in most cases of fetuses with 45X karyotype. Fetuses with CV failure almost always demonstrate obstructed jugular lymphatics with increased nuchal translucency or nuchal cystic hygromas, the typical intrauterine presentation of TS. The residual postnatal webbing of the neck predicts CV defects. This association suggests a pathogenetic connection between fetal lymphatic obstruction and defective CV development due to the compression or obstruction of the outflow tracts.<sup>2,8,9</sup>

However, this is just a theory regarding a pathogenetic mechanism for congenital CV defects, because the real causes are currently unknown.<sup>1</sup>

### A. Valvular anomaly

#### A. 1. Bicuspid aortic valve

A bicuspid aortic valve (BAV) is a congenital valvular anomaly found in approximately 30% of TS patients and it is not often clinically apparent.<sup>14</sup>

Identifying a BAV in asymptomatic individuals is important because they are at increased risk of infective endocarditis, hemodynamically significant stenosis (promoted

**Table 1**

Referenc  
numb

Bondy e  
al.<sup>1</sup>

Bondy e  
al.<sup>2</sup>

Bondy e  
al.<sup>3</sup>

Marin et

Mortens  
et al.<sup>5</sup>

Hiratzka  
al.<sup>6</sup>

Granger  
al.<sup>7</sup>

Surerus  
al.<sup>8</sup>

Loscalzo  
al.<sup>9</sup>

Spectrum  
al.<sup>10</sup>

Ho et al

Hjerrild  
al.<sup>12</sup>

Download English Version:

<https://daneshyari.com/en/article/8677920>

Download Persian Version:

<https://daneshyari.com/article/8677920>

[Daneshyari.com](https://daneshyari.com)