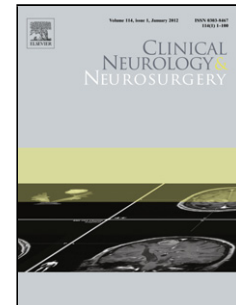


## Accepted Manuscript

Title: Clinical significance of the coexistence of carotid artery plaque and white matter disease in patients with symptomatic cerebral infarction

Authors: Mami Ishikawa, Hitoshi Sugawara, Toshiyuki Tsuji, Mutsumi Nagai, Gen Kusaka, Heiji Naritaka



PII: S0303-8467(17)30297-4  
DOI: <https://doi.org/10.1016/j.clineuro.2017.10.027>  
Reference: CLINEU 4812

To appear in: *Clinical Neurology and Neurosurgery*

Received date: 16-8-2017  
Revised date: 23-9-2017  
Accepted date: 25-10-2017

Please cite this article as: Ishikawa Mami, Sugawara Hitoshi, Tsuji Toshiyuki, Nagai Mutsumi, Kusaka Gen, Naritaka Heiji. Clinical significance of the coexistence of carotid artery plaque and white matter disease in patients with symptomatic cerebral infarction. *Clinical Neurology and Neurosurgery* <https://doi.org/10.1016/j.clineuro.2017.10.027>

This is a PDF file of an unedited manuscript that has been accepted for publication. As a service to our customers we are providing this early version of the manuscript. The manuscript will undergo copyediting, typesetting, and review of the resulting proof before it is published in its final form. Please note that during the production process errors may be discovered which could affect the content, and all legal disclaimers that apply to the journal pertain.

# Clinical significance of the coexistence of carotid artery plaque and white matter disease in patients with symptomatic cerebral infarction

Mami Ishikawa M.D. Ph.D.<sup>1, 2</sup>, Hitoshi Sugawara M.D. Ph.D.<sup>3</sup>,  
Toshiyuki Tsuji M.D.<sup>2</sup>, Mutsumi Nagai M.D. Ph.D.<sup>2</sup>,  
Gen Kusaka M.D. Ph.D.<sup>2</sup>, Heiji Naritaka M.D., Ph.D.<sup>1</sup>

<sup>1</sup>Department of Neurosurgery, Edogawa Hospital

<sup>2</sup>Department of Neurosurgery and <sup>3</sup>Division of General Medicine, Department of the Comprehensive Medicine 1. Saitama Medical Center, Jichi Medical University

## Corresponding author:

Mami Ishikawa MD, PhD.

Department of Neurosurgery, Edogawa Hospital

2-24-18 Higashikoiwa, Edogawa-ku, 133-0052 Tokyo, JAPAN

E-mail: m.ishikawa@edogawa.or.jp Tel: 81-3-3673-1221

## Highlights for review

- The unique features of carotid artery plaque and white matter disease (WMD) in cerebral infarction (CI) were investigated.
- The increased means of measures regarding the plaques and WMD in the cerebral ischemia group may be indicative of CI.
- The coexistence of plaque and WMD is the feature of symptomatic CI without stenosis or occlusion of a cerebral artery.

## Abstract

*Objectives:* Symptomatic cerebral infarction (CI) can occur in patients without main

Download English Version:

<https://daneshyari.com/en/article/8682064>

Download Persian Version:

<https://daneshyari.com/article/8682064>

[Daneshyari.com](https://daneshyari.com)