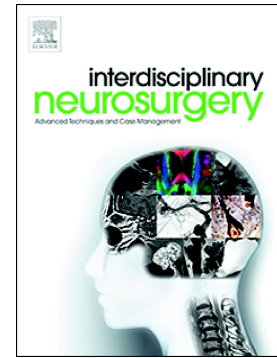


## Accepted Manuscript

A rare case of facial nerve schwannoma masked by a concomitant temporomandibular disorder pain

Natália R. Ferreira, Aleli T. Oliveira, Marcos F. DosSantos, Valéria Battistella, Paulo R.V. Bahia, Antônio C.P. Carvalho, André Antonio Monteiro



PII: S2214-7519(18)30027-6  
DOI: doi:[10.1016/j.inat.2018.06.008](https://doi.org/10.1016/j.inat.2018.06.008)  
Reference: INAT 338

To appear in: *Interdisciplinary Neurosurgery: Advanced Techniques and Case Management*

Received date: 16 February 2018  
Revised date: 9 May 2018  
Accepted date: 24 June 2018

Please cite this article as: Natália R. Ferreira, Aleli T. Oliveira, Marcos F. DosSantos, Valéria Battistella, Paulo R.V. Bahia, Antônio C.P. Carvalho, André Antonio Monteiro , A rare case of facial nerve schwannoma masked by a concomitant temporomandibular disorder pain. Inat (2018), doi:[10.1016/j.inat.2018.06.008](https://doi.org/10.1016/j.inat.2018.06.008)

This is a PDF file of an unedited manuscript that has been accepted for publication. As a service to our customers we are providing this early version of the manuscript. The manuscript will undergo copyediting, typesetting, and review of the resulting proof before it is published in its final form. Please note that during the production process errors may be discovered which could affect the content, and all legal disclaimers that apply to the journal pertain.

## **A rare case of facial nerve schwannoma masked by a concomitant temporomandibular disorder pain**

**Authors:** Natália R. Ferreira, D.D.S.,<sup>a,c\*</sup> Aleli T. Oliveira, D.D.S.,<sup>a,c</sup> Marcos F. DosSantos, D.D.S., M.S., Ph.D.,<sup>b</sup> Valéria Battistella M.D., M.S.,<sup>d</sup> Paulo R.V. Bahia, M.D., Ph.D.,<sup>c</sup> Antônio C. P. Carvalho, M.D., Ph.D.,<sup>c</sup> André Antonio Monteiro, D.D.S., M.S., Odont. Dr<sup>a</sup>

### **Complete affiliations of all authors:**

- a. Departamento de Clínica, Faculdade de Odontologia, Universidade Federal do Rio de Janeiro, Brasil.
- b. Universidade Federal do Rio de Janeiro (UFRJ), Campus Macaé, Macaé, Rio de Janeiro, Brasil.
- c. Departamento de Radiologia, Faculdade de Medicina, Universidade Federal do Rio de Janeiro, Brasil.
- d. Departamento Neurologia vascular, Hospital Copa D'Or, Rio de Janeiro, Brasil.

### **\*Corresponding Author:**

Natália dos Reis Ferreira  
Faculdade de Odontologia, Universidade Federal do Rio de Janeiro  
Av. Carlos Chagas Filho, 373, Centro de Ciências da Saúde, Bloco K, 2º andar, Sala 56,  
Ilha da Cidade Universitária, Rio de Janeiro, RJ  
CEP: 21.941-902, Brasil  
+5524981076200  
natrferreira@gmail.com

Conflicts of interest: None

Abstract word count: 148

Manuscript word count: 1,800

Number of references: 19

Number of figures: 3

Total number of pages of the entire manuscript: 9

Download English Version:

<https://daneshyari.com/en/article/8684830>

Download Persian Version:

<https://daneshyari.com/article/8684830>

[Daneshyari.com](https://daneshyari.com)