Journal of Clinical Neuroscience xxx (2017) xxx–xxx

Contents lists available at ScienceDirect

Journal of Clinical Neuroscience

journal homepage: www.elsevier.com/locate/jocn

Review article

Paediatric aneurysms – Review of endovascular treatment strategies

P. Bhogal [a,*], M. Aguilar Pérez [a], C. Wendl [b], H. Bäzner [c], O. Ganslandt [d], H. Henkes [a,e]

[a] Neuroradiological Clinic, Neurocenter, Klinikum Stuttgart, Stuttgart, Germany
[b] Institut für Röntgendiagnostik, Universitätsklinikum Regensburg, Regensburg, Germany
[c] Neurological Clinic, Neurocenter, Klinikum Stuttgart, Germany
[d] Neurosurgical Clinic, Neurocenter, Klinikum Stuttgart, Germany
[e] Medical Faculty, University Duisburg-Essen, Essen, Germany

ARTICLE INFO

Article history:
Received 21 May 2017
Accepted 10 August 2017
Available online xxxx

Keywords:
Paediatric aneurysm
Coil
Flow diversion
Parent artery occlusion
Dissection
Infection

ABSTRACT

Paediatric aneurysms are rare and represent the end result of a variety of different pathological mechanisms. They have a varied presentation and features that are distinct from their adult counterparts. The appropriate management of these aneurysms requires a multi-disciplinary team approach and detailed analysis to deal with the underlying pathology. This can involve the use of coils, adjunctive devices such as neck-bridging devices, flow diverters and liquid embolic agents, as well as microsurgical clipping. In this paper we discuss the different types of aneurysms that can present in the paediatric population and present cases that highlight the entire spectrum of paediatric aneurysmal disease and the different treatment options currently available. Treatment of paediatric intracranial aneurysms requires individualized strategies.

© 2017 The Authors. Published by Elsevier Ltd. This is an open access article under the CC BY-NC-ND license (http://creativecommons.org/licenses/by-nc-nd/4.0/).

1. Introduction

Intracranial aneurysms in the paediatric population are relatively uncommon and occur less frequently than in adults, accounting for <5% of all intracranial aneurysms [1,2]. Although in the adult population various risk factors can contribute to the formation of aneurysms these are unlikely to contribute to the formation aneurysms in the paediatric population. Compared to adults there are differences in aneurysm location, morphological characteristics, presentation and outcome. The treatment of aneurysms in the adult population underwent considerable changes since the publication of the International Subarachnoid Aneurysm Trial (ISAT) [3], with endovascular coiling showing advantages over microsurgical clipping. However, there has been no such trial in the paediatric population and it is unlikely that there ever will be. The published literature consists of case series [4–9], however, even the available literature is scarce compared to the published material on adult aneurysms.

We sought to describe our experience of treating paediatric aneurysms using a variety of different endovascular strategies and highlight the potential advantages and disadvantages of the different strategies.

2. Saccular aneurysms

Classic saccular or berry aneurysms are rarely seen in neonates, infants and children below the age of 10, however, their incidence increases with age and up to 20% of aneurysms seen in those below 18 years old may be classified as saccular aneurysms [10–12]. Although the underlying patho-mechanisms involved in the formation of these aneurysms in children may differ compared to adults some authors believe that the treatment and natural history of classical saccular aneurysms does not significantly differ from that in adults [10]. In this regard both microsurgical and endovascular treatment options (Fig. 1) can play a valuable role in the management of these aneurysms. Consistent with adult aneurysm management and the shift towards endovascular concepts there has been a gradual increase in the use of the endovascular techniques compared to microsurgical clipping since the publication of ISAT, with approximately 50% of paediatric aneurysms treated endovascularly according to Beez et al. [13].

3. Dissecting and fusiform aneurysms

Dissecting and fusiform aneurysms are over represented in the paediatric population in comparison to adults, with Krings et al. [10] reporting that the incidence of dissecting aneurysms in the paediatric population is four times higher than in the adult population. This group also suggests that up to 50% of all aneurysms in

* Corresponding author at: Neuroradiological Clinic, Neurocenter, Klinikum Stuttgart, Kriegsbergstrasse 60, 70174 Stuttgart, Germany.
E-mail address: bhogalweb@aol.com (P. Bhogal).

http://dx.doi.org/10.1016/j.jocn.2017.08.009
0967-5868/© 2017 The Authors. Published by Elsevier Ltd.
This is an open access article under the CC BY-NC-ND license (http://creativecommons.org/licenses/by-nc-nd/4.0/).

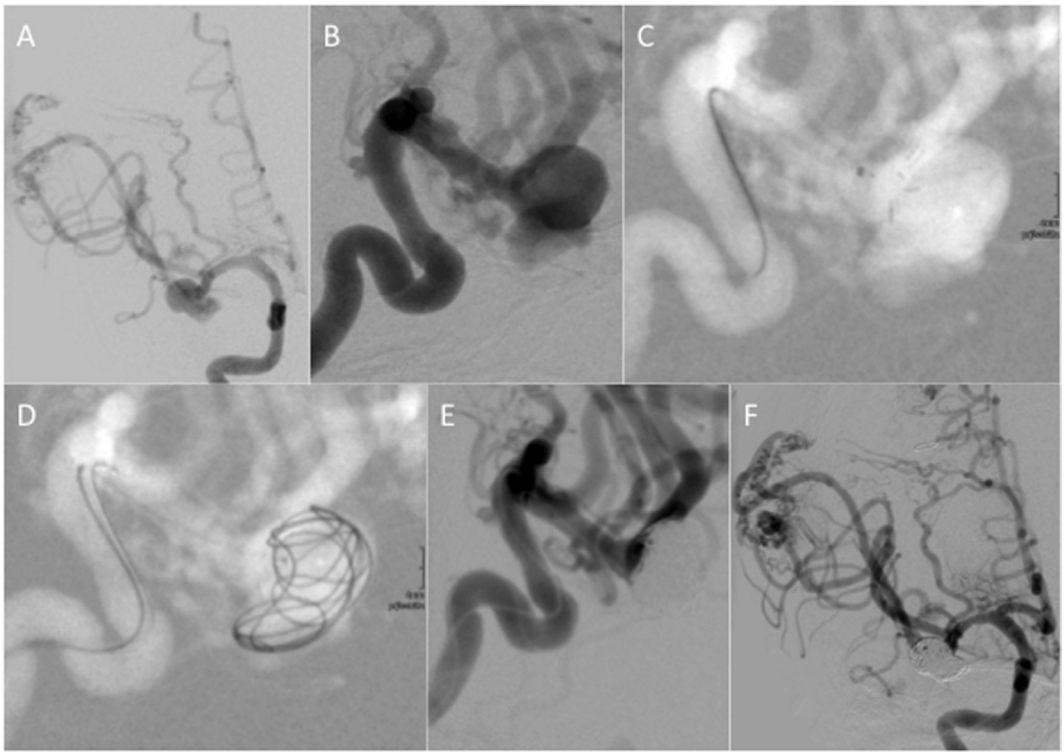

Fig. 1. A 13-year-old boy with a previously diagnosed hereditary haemorrhagic telangiectasia (Osler-Weber-Rendu syndrome) sustained a massive right frontal intracerebral and subarachnoid haemorrhage, which required decompressive craniectomy. DSA showed a cerebellar AVM and a large right frontal brain AVM with a flow related aneurysm at the right MCA bifurcation (a and b). The aneurysm was the likely source of the intracranial haemorrhage. This aneurysm was wide necked and showed an irregular shape. A significant risk of recurrent haemorrhage was anticipated. After a thorough interdisciplinary discussion, taking haematological, paediatric, surgical and endovascular aspects into account, a pCONus2_HPC neck-bridging device was implanted (c). This version of the pCONus device has a hydrophilic surface with reduced thrombogenicity and therefore requires the patient to be placed only on ASA and not on dual anti-platelet medication. After placement of the pCONus2_HPC the aneurysm was coiled (d) and completely occluded (e and f). The patient was initially started on ASA and Clopidogrel. Three weeks after the treatment recurrent epistaxis prompted a reduction of the platelet function inhibition, which was continued with 50 mg ASA PO daily, without thrombosis of the bifurcation implant pCONus2_HPC.

the paediatric population, particularly in younger infants and children, may be the result of a dissection. As with dissecting aneurysms in the adult the presentation can be extremely varied and a high degree of suspicion and prompt thorough investigation is required in order to accurately identify the underlying pathology. The presenting symptoms can be related to ischaemia, subarachnoid haemorrhage or mass effect and in certain circumstances a combination of different symptoms. Dissections that present with subarachnoid haemorrhage have a predisposition for recurrent haemorrhage and this risk is highest in the early post-ictal period with up to 80% of recurrent haemorrhages occurring during the first week [14,15]. As in adults there are several treatment options available for dissecting aneurysms and these can be broadly classified as reconstructive (parent artery preserving) (Figs. 2 and 3) or deconstructive (parent artery sacrificing) (Fig. 4). The decision on which treatment option is most suitable will be determined by a variety of factors such as exact location of the dissection, presence of collateral supply, local perforator arteries, etc. The recent development of flow diverting stents has provided a viable treatment option for dissecting aneurysms. The tightly woven mesh of these stents will act to not only redirect blood away from the dissection but also tack the dissection flap down against the arterial wall. The implantation of these devices requires the usage of dual antiplatelet agents, which may increase the risk of re-haemorrhage. In addition to the risks of anti-platelet agents the long-term results of the device implantation in the paediatric population are not known. More recently coated flow diverters, such as the Pipeline Shield (Medtronic) have become available which may not require dual anti-platelet agents.

If vessel sacrifice is considered then parent vessel occlusion with coils is a suitable treatment option. Prior to parent vessel occlusion balloon test occlusion with analysis of the collateral supply should be performed and although the pial collaterals in children are usually sufficient to allow for vessel sacrifice, this strategy could require a conjunctive bypass operation.

Chronic dissections may result in fusiform aneurysms. In this scenario some authors follow a conservative strategy with close follow-up [10], however, an alternative is parent artery reconstruction with flow diversion. Several case reports and case series have reported on the use of flow diverters in the paediatric population [16–22] and these have shown, as in adults, gradual occlusion of the aneurysms over time. However, the use of flow diverters or intracranial stents in children needs to be considered carefully. The first issue is that of the child's growth and the expected change in the size of the cerebral vessels might be considered as a contradiction to the use of flow diverters or stents in general [16,23,24]. However, it has been shown that the cranial growth is rapid during the early years of life and then slows markedly with virtual complete growth by the age of 6 years with 85% of growth complete by the age of 5 [25]. Similarly, by the age of 4 years the intracranial arteries have reached 81–99% of their adult diameters with 87% of the middle cerebral artery (MCA) diameter reached by 6 months of age [26]. Similar findings were reported by He et al. [27] who dubbed it 'the rule of 5' since the vast majority of the arterial growth occurs before the age of 5. The second issue, and much more important, is that of anti-platelet medication. There are currently no available guidelines on the use of anti-platelet agents in children with cerebrovascular diseases and no definite

Download English Version:

https://daneshyari.com/en/article/8685508

Download Persian Version:

https://daneshyari.com/article/8685508

Daneshyari.com