Case of Subarachnoid Hemorrhage from Ruptured Oncotic Fusiform Aneurysms from Choriocarcinoma Metastasis Treated with Aneurysmectomy and Vessel Reconstruction

Yuichi Ito[1], Yoshio Araki[2], Takashi Izumi[2], Sho Okamoto[2], Masaaki Kimura[1], Toshihiko Wakabayashi[2]

Key words
- Anastomosis
- Choriocarcinoma
- Oncotic aneurysm
- Subarachnoid hemorrhage

Abbreviations and Acronyms
hCG: Human chorionic gonadotropin
MCA: Middle cerebral artery
MEA: Methotrexate, etoposide, and actinomycin D
SAH: Subarachnoid hemorrhage
STA: Superficial temporal artery

From the Department of Neurosurgery, [1]Nagoya Ekisaikai Hospital, Nakagawa-ku, and [2]Nagoya University Graduate School of Medicine, Showa-ku, Nagoya, Aichi, Japan

To whom correspondence should be addressed: Yoshio Araki, M.D., Ph.D. [E-mail: y.araki@med.nagoya-u.ac.jp]

Citation: World Neurosurg. (2018) 113:98-102. https://doi.org/10.1016/j.wneu.2018.02.049

Journal homepage: www.WORLDNEUROSURGERY.org

Available online: www.sciencedirect.com

1878-8750/$ - see front matter © 2018 Elsevier Inc. All rights reserved.

■ BACKGROUND: **Oncotic aneurysm is a rare condition with a high mortality rate. Because no consensus has been reached regarding therapeutic strategy for ruptured oncotic aneurysm, treatment remains challenging.**

■ CASE DESCRIPTION: **A 35-year-old woman developed sudden onset of severe headache. Computed tomography showed subarachnoid hemorrhage and cerebral angiography revealed 2 fusiform aneurysms in the distal portion of the left middle cerebral artery. Aneurysmectomy with vessel reconstruction using a superficial temporal artery graft was performed to maintain blood flow to the distal middle cerebral artery. Pathologic examination of the aneurysm and wall of the resected recipient middle cerebral artery showed infiltrating trophoblasts. Immunostaining for human chorionic gonadotropin was positive in the aneurysm specimen. On the basis of an elevated concentration of serum human chorionic gonadotropin, choriocarcinoma with ruptured intracranial oncotic aneurysms was diagnosed. After further systemic examination for carcinoma, chemotherapy was initiated.**

■ CONCLUSIONS: **Aneurysmectomy, resection of the parent artery with irregular walls and reconstruction to the distal recipient artery with normal intima should be considered to secure patency of the anastomosis and prevent the recurrence of oncotic aneurysm. Subsequent chemotherapy is essential to prevent carcinomatous meningitis and disease progression.**

INTRODUCTION

Aneurysms of the distal middle cerebral artery (MCA) are rare, constituting 2%–6% of cerebral aneurysms.[1] The etiology of this aneurysm includes infectious, traumatic, and oncotic factors.[1] Among these, oncotic aneurysm is rare and shows a high mortality rate estimated as >60%.[2-11] Most cases with ruptured aneurysmal formation resulting from carcinoma invasion into the arterial wall are difficult to treat directly with surgery, so treatment remains challenging. We report here a case of effective treatment for ruptured oncotic fusiform aneurysms. The patient was treated with aneurysmectomy and vessel reconstruction using a superficial temporal artery (STA) graft.[12] We propose adaptive surgical treatment of ruptured oncotic fusiform aneurysms for the purpose of subsequent chemotherapy.

CASE PRESENTATION

A 35-year-old woman was admitted to our hospital due to sudden onset of severe headache. Two years before admission, she had undergone an abortion followed by atypical genital bleeding. She had a history of hemosputum and cavitary shadows in the left lung on computed tomography of the chest 3 months before this admission (Figure 1A). Three weeks before admission, transbronchial biopsy had been performed for the cavitary shadows. No history of head trauma was elicited. Axillary temperature was 38.0°C, heart rate was 96 beats/min, blood pressure was 136/68 mm Hg, and respiratory rate was 20 breaths/min. Neurologic examination revealed no focal neurologic deficits.

Plain computed tomography of the head revealed pure subarachnoid hemorrhage (SAH) mainly in the left sylvian fissure (Figure 1B). Cerebral angiography revealed 2 fusiform aneurysms in the left distal MCA (Figure 1C and D). The wall of the distal MCA was irregular. The aneurysms measured 4.7 mm × 5.1 mm and 3.2 mm × 4.1 mm. Cardiac ultrasonography revealed no vegetations, valvular disease, or myxoma. A diagnosis of SAH (Hunt and Hess grade 2) from the left distal MCA fusiform aneurysm was established, and a treatment strategy of aneurysmectomy and vessel reconstruction using an STA graft was selected for this rare disease. Under general anesthesia, a curved linear incision in the scalp was made along the parietal branch of the STA and temporoparietal craniotomy was performed. Using a surgical microscope, the arachnoid was opened and dissected along the distal MCA, exposing the aneurysm (Figure 2A). All affected arteries involved in the aneurysms were exposed and clipped (Figure 2B).

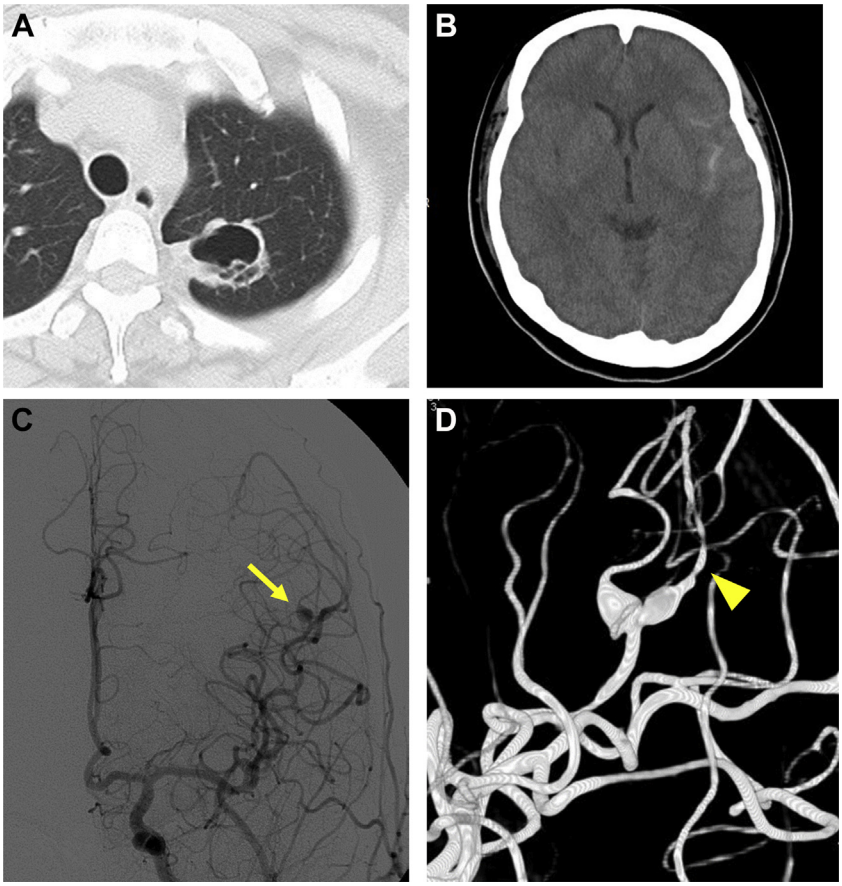

Figure 1. Preoperative radiologic findings. (**A**) Computed tomography (CT) of the chest revealing cavitary shadows in the left lung. (**B**) CT of the head revealing subarachnoid hemorrhage with dominant distribution in the left sylvian fissure. (**C**) Left common carotid angiogram revealing 2 fusiform aneurysms (4.7 mm × 5.1 mm and 3.2 mm × 4.1 mm) at the distal portion of the left middle cerebral artery (*yellow arrow*). (**D**) Enlarged view of 3-dimensional digital subtraction angiography revealing 2 fusiform aneurysms and irregular wall of the distal portion of an aneurysm (*yellow arrowhead*).

Trapping of the aneurysms and aneurysmectomy was performed. STA-MCA anastomosis was performed in an end-to-end fashion (Figure 2C). The intima of the recipient MCA appeared thickened. Although intraoperative indocyanine green fluorescence videography revealed that the anastomosis was not patent, postoperative magnetic resonance imaging diffusion-weighted image revealed no ischemic changes (Figure 2D). The patient experienced no new neurologic deficits after surgery.

Gross photographs of the aneurysms are shown in Figure 3A. Microscopic examination of the aneurysms revealed ruptured aneurysmal walls with tumor cell infiltrates (Figure 3B). Infiltration was observed in the arteries of the distal MCA emanating from the aneurysm. Trophoblasts were identified, and stains for human chorionic gonadotropin (hCG) showed positive results in the aneurysms (Figure 3C). Biopsy of the cavity in the lung revealed trophoblasts, and stains for hCG also yielded positive results. Serum hCG was 238 mIU/mm^3. Magnetic resonance imaging of the pelvis revealed no residual tumoral lesion after the abortion. Given the history of abortion and atypical genital bleeding, choriocarcinoma with ruptured intracranial oncotic aneurysms and metastatic lung tumor was finally diagnosed as choriocarcinoma stage IV. The patient was immediately treated with chemotherapy including methotrexate, etoposide, and actinomycin D (MEA) for a total of 15 courses. Six months later, serum hCG was <0.4 mIU/mm^3. One year after admission, the patient showed no neurologic deficits and good general condition. Magnetic resonance angiography performed 2 years after the surgery revealed no recurrence and no de novo aneurysm formation (Figure 4), and all metastases had disappeared following the completion of chemotherapy.

DISCUSSION

To the best of our knowledge, this is only the 26th reported case of ruptured oncotic aneurysm.[11] Distal MCA aneurysm was first described by Poppen in 1951, and ruptured distal MCA aneurysms are now a rare entity, constituting 0.47% of all cerebral aneurysms.[1] The etiology of distal MCA aneurysm includes infectious, traumatic, and oncotic factors. Oncotic aneurysm was first described by Vaughan and Howard in 1962, and only 25 cases of ruptured oncotic aneurysm have been reported.[10,11] The etiology of oncotic aneurysm includes choriocarcinoma, myxoma, and lymphoma.[7,10,12] The pathogenesis of oncotic aneurysm would begin with the occlusion of vessels by tumor cell emboli, followed by proliferation of tumor cells into vessel walls and destruction of the internal elastic lamina, resulting in aneurysm formation.[7,10] According to previous reports, most cases were identified with onset of intracerebral hemorrhage. Onset with pure SAH as in this case appears rare and may have a positive prognostic effect if treatment can be successfully performed. Intracerebral hemorrhage occurring beyond the arachnoid membrane not only disturbs neurons and neural fibers but also facilitates the dissemination of tumor cells.

Treatment of ruptured oncotic aneurysm is challenging because of the characteristics, and standardized treatment strategies have yet to be established. Most oncotic aneurysms are fusiform type and are located in the distal MCA, and standard neck clipping is difficult.[7,10]

Branscheidt et al[13] reported a case of metastatic multiple cerebral aneurysm from cardiac myxoma to the distal MCA.

Download English Version:

https://daneshyari.com/en/article/8691719

Download Persian Version:

https://daneshyari.com/article/8691719

Daneshyari.com